

# A Surgical Landmark for Frontal Ventriculostomy: A Craniometric Study in Thai Cadavers and Dry Skulls

Nawaporn Techataweewan MD\*, Amnat Kitkhuandee MD\*\*, Pichayen Duangthongphon MD\*\*, Yanyong Toomsan MSc\*

\* Department of Anatomy, Faculty of Medicine, Khon Kaen University, Khon Kaen, Thailand

\*\* Department of Surgery, Faculty of Medicine, Khon Kaen University, Khon Kaen, Thailand

**Background:** *The free-hand pass method of ventriculostomy catheter placement using surface anatomical landmarks can be a lifesaving emergency neurosurgical procedure allowing assessment and management of intracranial pressure for critically ill patients. The procedure requires a burr hole through the skull and the appropriate location of this point is essential to success.*

**Objective:** *To determine cranial measurements to assist with optimal ventriculostomy burr hole placement in Thai patients.*

**Material and Method:** *Measurements of the frontal bone were performed on 65 embalmed cadaveric cranial vaults (33 males and 32 females) and 729 dry skulls (349 males and 380 females) at the Department of Anatomy, Faculty of Medicine, Khon Kaen University, Thailand.*

**Results:** *In the large sample of dry skulls, measurements from nasion to bregma were 127.9 mm in males and 124.0 mm in females. The mean distance between the mid-supraorbital rim and the coronal suture on the right is 105.9 mm in males and 99.6 mm in females, and on the left 100.0 mm in males and 94.2 mm in females. The measurements were statistically significant larger in males than in females, and statistically significant larger on the right side than the left in both sexes. These measurements on dry skulls were smaller than on cadaveric scalps by approximately 8 mm.*

**Conclusion:** *The mean values from nasion to bregma and mid-supraorbital rim to coronal suture were determined. This is a first step in improving success rates with the procedure in Thai patients.*

**Keywords:** *Kocher's point, Intraventricular catheter, Cranial shape*

**J Med Assoc Thai 2017; 100 (9): 1007-13**

**Website:** <http://www.jmatonline.com>

One of the most commonly performed procedures in neurosurgery is ventriculostomy, the insertion of an intraventricular catheter (also known as external ventricular drainage). This operation is considered an important tool for diagnosis and temporary therapeutic or prophylactic intervention for the continuous management of intracranial pressure and cerebrospinal fluid drainage<sup>(1-3)</sup>.

It involves drilling a burr hole in the frontal cranial vault and inserting a catheter into one of the ventricles of the brain. The location of the ventricular catheter tip is crucial. Its ideal location is inside the frontal horn of the lateral ventricle, just anterior to the foramen of Monro<sup>(4-6)</sup>. A number of different devices such as endoscopy, neuronavigation, and mechanical guides<sup>(4-8)</sup> have been reported as being technically accurate and safe for ventricular catheter placements.

Ventricular cannulation as a life-saving procedure is often practiced by neurosurgeons in emergencies, where the only method available is the

free-hand pass technique using surface anatomical landmarks to locate the burr hole and guide the insertion of the catheter<sup>(9,10)</sup>. The most common site for the burr hole is described as Kocher's point, or the coronal point, but there appears to be no universal agreement on the precise location of this point. It is variously defined as between 10 and 13 cm posterior to nasion and 2.5 to 3 cm lateral to the midline at the mid-pupillary line<sup>(11-15)</sup>, or at least one cm anterior to the coronal suture<sup>(16,17)</sup>.

The accuracy of freehand placement of a ventriculostomy catheter has been investigated extensively. Several studies report misplacement of the catheter using Kocher's point and other anatomical landmarks ranging from 7 to 45%<sup>(1,15,18,19)</sup>.

The measurements used for defining Kocher's point for locating the burr hole used in this procedure are most likely to have been originally developed on European patients. Kocher is most likely to be German, although we have been unable to get access to his original publication<sup>(9)</sup>. It is well known that there is variation in head shape worldwide. For example, the heads of people of European ancestry, although variable in shape, tend towards being relatively long and narrow

**Correspondence to:**

Techataweewan N; Department of Anatomy, Faculty of Medicine, Khon Kaen University, Khon Kaen 40002, Thailand.

Phone: +66-43-363173; Fax: +66-43-348381

E-mail: [nawtec@kku.ac.th](mailto:nawtec@kku.ac.th)

(dolichocephalic)<sup>(20)</sup> compared to Asian skulls, which are relatively short and wide (brachycephalic)<sup>(21)</sup>. In view of these issues, the aim of the present research was to take a first step to improve the success of ventriculostomy in Thai practice by determining the relevant frontal cranial dimensions between surgical landmarks in Thai patients using cadavers and dry skulls.

### Material and Method

To derive measurements approximately comparable to those in living patients in the present study, they were first taken on sample of cadaveric heads obtained from the Department of Anatomy at Khon Kaen University, Khon Kaen, Thailand. The size of this sample was limited because of the time involved, so the same measurements were taken on a large sample of dry skulls from the collection in the Department of Anatomy. To establish comparability between the measurements on the two samples, they were repeated on the cadaveric heads after dissection of the soft tissues of the scalp.

The anatomical landmarks and measurements were chosen to match those used in ventriculostomy during neurosurgery. They are nasion, bregma, the coronal suture, and the mid-superior orbital rim. The latter was used as a substitute for the mid-pupillary point. It was defined as the most superior point on the superior orbital rim, determined by eye, when viewing the skull from the anterior. This is usually at the midpoint of the orbital rim. In living patients, the landmarks (nasion, bregma, the coronal suture, and the mid-superior orbital rim) used to determine the site of the burr hole are identified by palpation. In the cadavers, these landmarks were identified by palpation and small incision.

Distances were taken from nasion to bregma, and on both sides of the skull from the mid-superior orbital rim to the coronal suture, parallel to the nasion-bregma measurement. They were using a tape measure (Fig. 1) and were performed by a single investigator to avoid inter-observer error. Each point was measured three times and the average was taken as the final value.

Sixty-five embalmed cadaveric heads (33 males and 32 females) were used. The mean age at death of the donors of these cadavers was 70 years (range 33 to 95 years). The donors of the cadavers had no history of brain tumor, head trauma, or neurosurgery. Measurements were obtained from each cadaver, firstly on the scalp, and then on the skull after dissection of the scalp.

The scalp of all samples was then removed by mid-sagittal and biauricular incisions to expose the cranial surface. The measurements as described above were then replicated (Fig. 2).

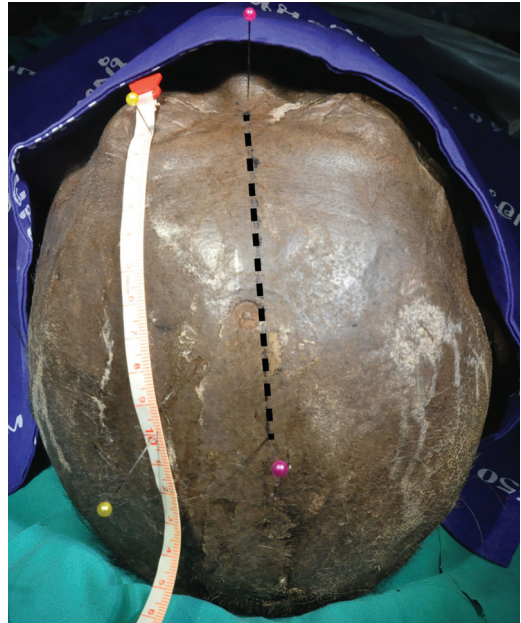


Fig. 1 Superior view cadaver scalp, showing nasion-bregma distance (dashed line), and mid-superior orbital rim-coronal suture (tape).

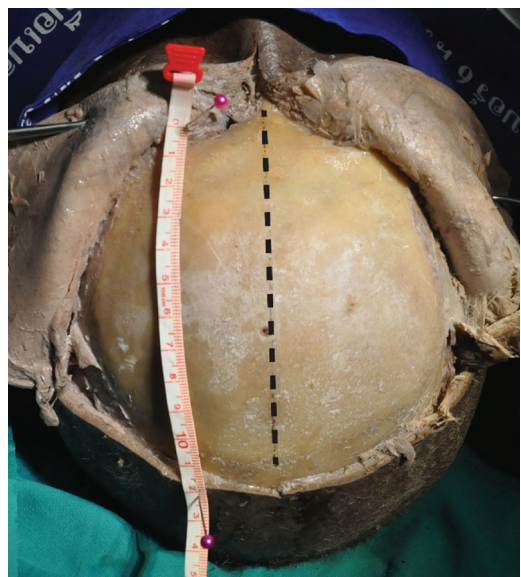


Fig. 2 Superior view of nasion-bregma distance (dashed line), and mid-superior orbital rim-coronal suture (tape) on the skull of a male cadaver.

Seven hundred and twenty nine dry human skulls were randomly selected from the collection of the Department of Anatomy of Khon Kaen University. Pathological specimens were excluded. Donors of all skulls were of Thai ancestry and the sex ratio was 349 males, 380 females. Average age at death was 64.50 years (range 25 to 103 years), with the male average 65.26±13.58 years and female average 63.76±14.60 years. Measurements were taken using the same bony landmarks and structures as described for the cadavers (Fig. 3).

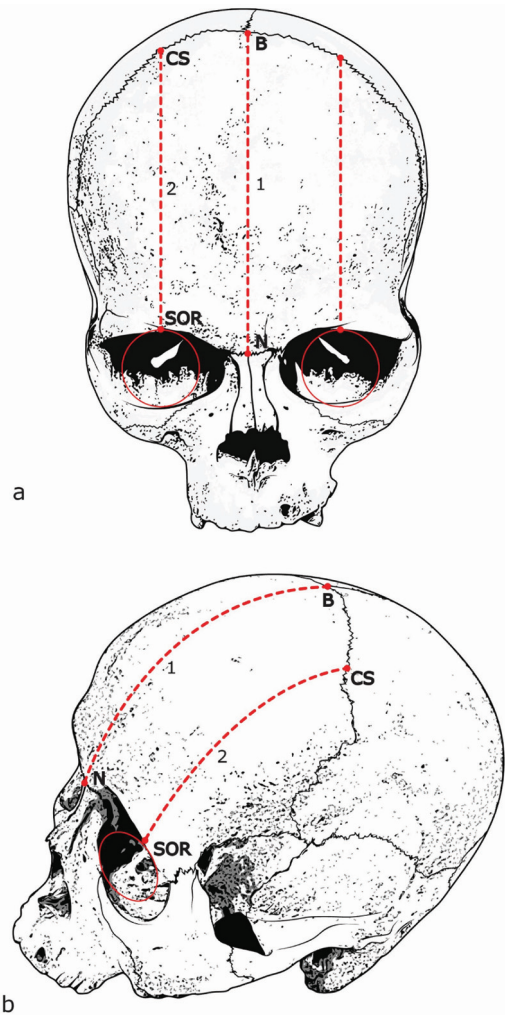
All metric data were analyzed by using STATA version 10.1 (StataCorp, College Station, TX, USA). Comparisons between males and females were performed using the independent t-test. A paired t-test was used for evaluating statistical associations between the right and left sides. A *p*-value of less than 0.05 was determined as statistically significant. The data are given as means and standard deviations. This study was approved by the Ethics Committee in Human Research of Khon Kaen University (No. HE 591120).

## Results

The cadaveric scalp and skull measurements obtained are summarized in Table 1 and 2, respectively, and the dry skull measurements in Table 3. These show that males have statistically significantly higher mean values than females for all parameters in both scalp and skull.

Table 4 show the differences between the right and left mid supraorbital rim to coronal suture measurements for cadaver scalp, cadaver skull and dry skull. Right and left did not differ significantly in the cadaver scalp and skull but the right-left difference in the much larger dry skull sample was significant for both males and females, with the right larger than left.

Table 5 details the differences between the cadaveric measurements, and between the cadaver and dry skull measurements, for both sexes. The cadaveric scalp measurements are significantly greater than the cadaver skull measurements for all parameters, with



**Fig. 3** Diagram illustrating the recorded landmarks and measurements on dry skulls (a) anterior view and (b) oblique view. Measurements taken between nasion (N) and bregma (B, 1), and the distance between mid-supraorbital rim (SOR) and the coronal suture (CS, 2) on both sides.

the differences ranging from 7.8 to 8.6 mm. The nasion-bregma differences are almost identical in both sexes, but the mid-supraorbital rim - coronal suture differences

**Table 1.** Means, ranges, and standard deviations of cadaveric scalp parameters for males (n = 33) and females (n = 32), and *p*-value for the differences between the sexes

Parameters	Mean (mm)		Minimum (mm)		Maximum (mm)		SD		<i>p</i> -value (Student's t-test)
	Male	Female	Male	Female	Male	Female	Male	Female	
Nasion-bregma distance	136.0	132.2	126.0	105.0	146.0	153.0	0.55	0.90	0.043*
Right mid-supraorbital rim-coronal suture distance	110.6	104.0	90.0	85.0	135.0	120.0	0.87	0.97	0.005*
Left mid-supraorbital rim-coronal suture distance	109.2	103.8	95.0	84.0	131.0	124.0	0.89	1.01	0.026*

\* Significant at 5% level of significance

**Table 2.** Means, ranges, and standard deviations of cadaveric skull parameters for males and females, and *p*-value for the differences between the sexes

Parameters	Mean (mm)		Minimum (mm)		Maximum (mm)		SD		<i>p</i> -value (Student's t-test)
	Male	Female	Male	Female	Male	Female	Male	Female	
Nasion-bregma distance	127.9	124.2	116.0	100.0	140.0	146.0	0.90	0.52	0.047*
Right mid-supraorbital rim-coronal suture distance	102.3	95.4	82.0	76.0	125.0	115.0	0.90	0.94	0.004*
Left mid-supraorbital rim-coronal suture distance	101.4	95.4	91.0	78.0	123.0	117.0	0.87	0.96	0.011*

\* Significant at 5% level of significance

**Table 3.** Means, ranges, and standard deviations of dry skull parameters for males (n = 349) and females (n = 380), and *p*-value for the differences between the sexes

Parameters	Mean (mm)		Minimum (mm)		Maximum (mm)		SD		<i>p</i> -value (Student's t-test)
	Male	Female	Male	Female	Male	Female	Male	Female	
Nasion-bregma distance	127.6	122.7	104.0	99.0	146.0	141.0	0.60	0.59	<0.001*
Right mid-supraorbital rim-coronal suture distance	105.9	99.6	90.0	83.0	127.0	120.0	0.58	0.59	<0.001*
Left mid-supraorbital rim-coronal suture distance	100.0	94.2	83.0	79.0	115.0	109.0	0.56	0.52	<0.001*

\* Significant at 5% level of significance

**Table 4.** Differences between right and left mid-supraorbital rim to coronal suture measurements, and *p*-value for the differences between the sexes, the original measurements are summarized in Table 1-3

Variables	Males	Females
Cadaveric scalp		
- Difference (mm)	1.40	0.20
- <i>p</i> -value	0.401	0.884
Cadaveric skull		
- Difference (mm)	0.90	0.00
- <i>p</i> -value	0.610	1.000
Dry skull		
- Difference (mm)	5.90	5.40
- <i>p</i> -value	<0.001*	<0.001*

\* Significant at 5% level of significance

are larger in females by 0.3 mm on the right and 0.6 mm on the left.

The differences between the cadaveric skull and dry skull measurements are not significant for either sex, with the exception of the right mid-supraorbital rim to coronal suture distance, which is significantly larger in the dry skull than in the cadaver skull in both sexes.

## Discussion

The preferred location for siting a burr hole using the classical free-hand technique for frontal ventriculostomy, known as Kocher's point, is defined in various ways by different authors, as noted in the introduction. This variability in the definition of the point can be assumed to be partly dependent on the vault shape of the patient sample used in the definition.

**Table 5.** Differences between mean measurements of cadaveric scalp and cadaveric skull, and between mean measurements of cadaveric and dry skull for males and females, and *p*-value for these differences, the original measurements are summarized in Table 1-3

Variables	Males	Females
Nasion-bregma distance		
- Cadaveric scalp and cadaveric skull		
- Difference (mm)	8.10	8.00
- <i>p</i> -value	<0.001*	<0.001*
- Cadaveric skull and dry skull		
- Difference (mm)	0.30	1.50
- <i>p</i> -value	0.966	0.457
Right mid-supraorbital rim-coronal suture distance		
- Cadaveric scalp and cadaveric skull		
- Difference (mm)	8.30	8.60
- <i>p</i> -value	<0.001*	<0.001*
- Cadaveric skull and dry skull		
- Difference (mm)	3.60	4.20
- <i>p</i> -value	0.007*	0.002*
Left mid-supraorbital rim-coronal suture distance		
- Cadaveric scalp and cadaveric skull		
- Difference (mm)	7.80	8.40
- <i>p</i> -value	<0.001*	<0.001*
- Cadaveric skull and dry skull		
- Difference (mm)	1.40	1.20
- <i>p</i> -value	0.467	0.565

\* Significant at 5% level of significance

As most publications defining Kocher's point are based on samples of patients with European ancestry, for surgeons treating patients of non-European ancestry, the higher chance of interpopulation variability in

cranial morphology has the possibility of compounding the difficulty in optimizing the location of the burr hole. This results in variability in the accuracy of burr hole placement for any individual patient and increases the chances of multiple attempts being required to successfully complete the procedure.

The present study aimed to assess the average nasion-bregma distance and mid-supraorbital rim-coronal suture distance in the Thai population as a first step in improving the accuracy for location of the burr hole in Thai patients. It provides mean values for consideration in the free-hand technique for ventricular catheter placement, which is still the standard method of ventriculostomy.

The results of both cadaveric and dry bone measurements indicate that frontal bones are significantly longer in the sagittal plane for all parameters in Thai males than in Thai females. Comparison of the right and left sides shows the right side is significantly longer in the sagittal plane than the left in both sexes in the dry skull sample. Although this does not appear to be the case in the cadaveric samples, this may be a reflection of the smaller sample size and the results from the large dry skull can be taken as the most accurate.

The comparison of cadaver scalp and cadaver skull measurements shows the skull measurements are all approximately 8 mm smaller than the scalp measurements. The greater differences of 0.3 and 0.6 mm in females compared with males in the mid-supraorbital - coronal suture measurements may be a reflection of a greater thickness of subcutaneous fat in females. The comparison of the cadaver skull and dry skull measurements shows they do not differ significantly, again with the exception of the right-side measurement, which is significantly larger in the dry skulls than in the cadaver skulls in both sexes. There is no obvious reason for this but again it can be assumed that the larger dry skull sample provides the most accurate data.

For application during surgery when siting the burr hole, this dataset shows the measurements on living patients should be increased by 8 mm to allow for the thickness of the scalp.

As noted in the introduction, published clinical studies compare the accuracy of image-guided ventriculostomy with the free-hand pass technique, and show that the accuracy and shunt revision rates using the image-guided techniques are superior to the free-hand technique. Currently, these systems are not universally available in all hospitals, and in addition, the image-navigation technology added 36 minutes to

the overall time until catheter insertion<sup>(22)</sup>. This delay is not desirable in an emergency.

At present, the most common and practical method available for Thai neurosurgeons for determining the location of the burr hole for ventriculostomy is the freehand method. It is normal practice in Thai hospitals to establish the location of the landmark for siting the burr hole (Kocher's point) using traditional means, although these were established on European populations. The large sample of Thai craniometrics reported in the present study are the first step in establishing whether this location of the burr hole is appropriate for the differently shaped crania of Thai people. The next step is to compare the Thai craniometrics with the same dimensions in large samples of dry skulls of European ancestry to determine the extent of the adjustment needed in the location of the burr hole, with the aim of reducing the number of attempts required to successfully carry out this surgical intervention.

## Conclusion

This work provides mean values from nasion to bregma and mid-supraorbital rim to coronal suture in the frontal bone of a large sample of Thai crania as a first step in improving the success rate of ventriculostomy in Thai people. Future research will firstly compare these measurements with those people of European ancestry to determine the extent of any modification needed in siting the burr hole. Concurrently, a clinical study will determine the current success rate of the procedure at Srinagarind Hospital as a base for future comparisons.

## What is already known on this topic?

The only data available for determining the best position for ventriculostomy are based on European populations. This is the first presentation of data from Thai people.

## What this study adds?

It provides the first evidence for the surgical landmark required to optimize frontal ventriculostomy in Thai people.

## Acknowledgement

This study received grant support from the Faculty of Medicine, Khon Kaen University (No. IN59238). We would like to acknowledge Assoc. Prof. Nancy Tayles for editing the MS via Publication Clinic KKU, Thailand.

## Potential conflicts of interest

None.

## References

1. Khanna RK, Rosenblum ML, Rock JP, Malik GM. Prolonged external ventricular drainage with percutaneous long-tunnel ventriculostomies. *J Neurosurg* 1995; 83: 791-4.
2. Sumer MM, Acikgoz B, Akpınar G. External ventricular drainage for acute obstructive hydrocephalus developing following spontaneous intracerebral haemorrhages. *Neurol Sci* 2002; 23: 29-33.
3. Zhong J, Dujovny M, Park HK, Perez E, Perlin AR, Diaz FG. Advances in ICP monitoring techniques. *Neurol Res* 2003; 25: 339-50.
4. Theodosopoulos PV, Abosch A, McDermott MW. Intraoperative fiber-optic endoscopy for ventricular catheter insertion. *Can J Neurol Sci* 2001; 28: 56-60.
5. Kim YB, Lee JW, Lee KS, Lee KC. Image-guided placement of ventricular shunt catheter. *J Clin Neurosci* 2006; 13: 50-4.
6. Hayhurst C, Beems T, Jenkinson MD, Byrne P, Clark S, Kandasamy J, et al. Effect of electromagnetic-navigated shunt placement on failure rates: a prospective multicenter study. *J Neurosurg* 2010; 113: 1273-8.
7. Janson CG, Romanova LG, Rudser KD, Haines SJ. Improvement in clinical outcomes following optimal targeting of brain ventricular catheters with intraoperative imaging. *J Neurosurg* 2014; 120: 684-96.
8. Wilson TJ, Stetler WR Jr, Al Holou WN, Sullivan SE. Comparison of the accuracy of ventricular catheter placement using freehand placement, ultrasonic guidance, and stereotactic neuronavigation. *J Neurosurg* 2013; 119: 66-70.
9. O'Neill BR, Velez DA, Braxton EE, Whiting D, Oh MY. A survey of ventriculostomy and intracranial pressure monitor placement practices. *Surg Neurol* 2008; 70: 268-73.
10. Dunn IF, Fierichs K, Day A, Kim DH. Ventriculostomy. In: Schmidek HH, Roberts DW, editors. *Schmidek & Sweet operative neurosurgical techniques: indications, methods, and results*. Vol.1. 5th ed. Philadelphia: Saunders; 2006: 35-6.
11. Dimitriou J, Levivier M, Gugliotta M. Comparison of complications in patients receiving different types of intracranial pressure monitoring: a retrospective study in a single center in Switzerland. *World Neurosurg* 2016; 89: 641-6.
12. Sussman ES, Kellner CP, Nelson E, McDowell MM, Bruce SS, Bruce RA, et al. Hemorrhagic complications of ventriculostomy: incidence and predictors in patients with intracerebral hemorrhage. *J Neurosurg* 2014; 120: 931-6.
13. Tsang ACO, Leung GKK. External ventricular drain infections. In: Pant S, Cherian I, editors. *Hydrocephalus*. Croatia: InTech; 2012: 87-98.
14. Woernle CM, Burkhardt JK, Bellut D, Krayenbuehl N, Bertalanffy H. Do iatrogenic factors bias the placement of external ventricular catheters? --a single institute experience and review of the literature. *Neurol Med Chir (Tokyo)* 2011; 51: 180-6.
15. Muralidharan R. External ventricular drains: Management and complications. *Surg Neurol Int* 2015; 6 (Suppl 6): S271-S274.
16. Huyette DR, Turnbow BJ, Kaufman C, Vaslow DF, Whiting BB, Oh MY. Accuracy of the freehand pass technique for ventriculostomy catheter placement: retrospective assessment using computed tomography scans. *J Neurosurg* 2008; 108: 88-91.
17. Muirhead WR, Basu S. Trajectories for frontal external ventricular drain placement: virtual cannulation of adults with acute hydrocephalus. *Br J Neurosurg* 2012; 26: 710-6.
18. Kakarla UK, Kim LJ, Chang SW, Theodore N, Spetzler RF. Safety and accuracy of bedside external ventricular drain placement. *Neurosurgery* 2008; 63: ONS162-6.
19. Stangl AP, Meyer B, Zentner J, Schramm J. Continuous external CSF drainage--a perpetual problem in neurosurgery. *Surg Neurol* 1998; 50: 77-82.
20. Gladwin T. The cranial index: A statistical study. *Hum Biol* 1941; 13: 88-102.
21. Sangvichien S, Boonkaew K, Chuncharunee A, Komoltri C, Piyawinitwong S, Wongsawut A, et al. Sex determination in Thai skulls by using craniometry: Multiple logistic regression analysis. *Siriraj Med J* 2007; 59: 216-21.
22. Mahan M, Spetzler RF, Nakaji P. Electromagnetic stereotactic navigation for external ventricular drain placement in the intensive care unit. *J Clin Neurosci* 2013; 20: 1718-22.

---

ตำแหน่งในการเจาะโพรงสมองผ่านกระดูกหน้าผาก: การศึกษาด้วยการวัดกะโหลกศีรษะในศพดองและกระดูกกะโหลกศีรษะคนไทย

นพพร เตชชาติวิวัฒธรรม, อำนวยกิจ จิ๋ววรรดี, พิษเยนทร์ ดวงทองพล, ยรรยง ทุ่มแสน

ภูมิหลัง: การวางสายระบายของเหลวในโพรงสมองด้วยเทคนิคมือเปล่าโดยใช้ตำแหน่งทางกายวิภาคศาสตร์ถือเป็นหัตถการฉุกเฉินทางประสาทศัลยศาสตร์ในการประเมินและรักษาความผิดปกติของความดันในสมองของผู้ป่วยในภาวะวิกฤติ การทำหัตถการนี้ต้องเจาะรูผ่านกะโหลกศีรษะ ซึ่งตำแหน่งที่เหมาะสมในการเจาะกะโหลกศีรษะจึงเป็นปัจจัยสำคัญที่มีผลต่อความสำเร็จในการทำหัตถการ

วัตถุประสงค์: เพื่อวัดระยะในกะโหลกศีรษะที่ช่วยในการกำหนดตำแหน่งเจาะกะโหลกศีรษะในผู้ป่วยชาวไทย

วัสดุและวิธีการ: ทำการวัดระยะที่กระดูกหน้าผากในศพดองจำนวน 65 ราย (เพศชาย 33 ราย และเพศหญิง 32 ราย) และในกระดูกกะโหลกศีรษะจำนวน 729 กะโหลก (เพศชาย 349 ราย และเพศหญิง 380 ราย) ณ ภาควิชากายวิภาคศาสตร์ คณะแพทยศาสตร์ มหาวิทยาลัยขอนแก่น ประเทศไทย

ผลการศึกษา: จากการวัดระยะที่กะโหลกศีรษะ พบว่าระยะค่าเฉลี่ยจาก *nasion* ถึง *bregma* 127.9 มม. ในเพศชาย และ 124.0 มม. ในเพศหญิง ค่าเฉลี่ยระหว่าง *mid-supraorbital rim* ถึง *coronal suture* ข้างขวา 105.9 มม. ในเพศชาย และ 99.6 มม. ในเพศหญิง ส่วนข้างซ้ายนั้นมีค่า 100.0 มม. ในเพศชาย และ 94.2 มม. ในเพศหญิง พบว่าระยะที่วัดได้ในเพศชายมีค่ายาวกว่าเพศหญิงอย่างมีนัยสำคัญทางสถิติ และทั้งในเพศชายและเพศหญิงระยะที่วัดได้ในข้างขวามีค่ายาวกว่าข้างซ้ายอย่างมีนัยสำคัญทางสถิติ ทั้งนี้ระยะที่วัดในกระดูกกะโหลกศีรษะมีค่าน้อยกว่าการวัดที่หนังศีรษะของศพดองประมาณ 8 มม.

สรุป: ได้ค่าเฉลี่ยของระยะที่วัดจาก *nasion* ไปยัง *bregma* และจาก *mid-supraorbital rim* ถึง *coronal suture* ที่ชัดเจน ซึ่งเป็นการศึกษาเบื้องต้นเพื่อเพิ่มอัตราความสำเร็จของการทำหัตถการนี้ในผู้ป่วยชาวไทย

---