

Case Report

Upper Extremity Deep Vein Thrombosis Related to Fatal Massive Pulmonary Embolism after Spinal Surgery

Maliwan Oofuvong MD*, Thakul Oearsakul MD**,
Voravit Chittithavorn MD***, Pongtep Viboonjuntra MD, PhD****

* Department of Anesthesiology, Faculty of Medicine, Prince of Songkla University, Hat Yai, Songkhla, Thailand

** Division of Neurologic Surgery, Department of Surgery, Faculty of Medicine,
Prince of Songkla University, Hat Yai, Songkhla, Thailand

*** Division of Cardiovascular Thoracic Surgery, Department of Surgery, Faculty of Medicine,
Prince of Songkla University, Hat Yai, Songkhla, Thailand

**** Division of Clinical Hematology, Department of Internal Medicine, Faculty of Medicine,
Prince of Songkla University, Hat Yai, Songkhla, Thailand

Upper extremity deep vein thrombosis (UEDVT) is an increasingly important clinical entity with potential for considerable morbidity, especially pulmonary embolism (PE). Here, the authors report a fatal case of the massive PE after spinal surgery, along with the UEDVT of superior vena cava (SVC).

Keywords: Spinal surgery, Upper extremity deep vein thrombosis, Massive pulmonary embolism

J Med Assoc Thai 2012; 95 (2): 279-81

Full text. e-Journal: <http://www.jmat.mat.or.th>

Pulmonary embolism (PE) related to upper extremity deep vein thrombosis (UEDVT) is uncommon. Owens et al⁽¹⁾ reviewed that UEDVT was 14 times less common than lower extremity deep vein thrombosis (LEDVT). The rates of PE related to UEDVT varied from 5.6 to 12% with 0.7 to 6% associated mortality^(2,3), whereas the rate of PE related to LEDVT was much higher (9 to 30%) with only 0.1% to 0.7% developing fatal events⁽⁴⁾. Schizas et al⁽⁵⁾ reported the incidence of PE related to LEDVT varied from 2.2 to 4.2% in spinal surgery when using low molecular weight heparin prophylaxis with no fatal events. The authors reported UEDVT at the superior vena cava related to a massive PE that led to a fatal condition after extensive spinal surgery and multiple transfusions.

Case Report

A fit 56-year-old Thai man underwent a transpedicular screw fixation with discectomy at L1-5. He was diagnosed as having spondylosis at L1-5. He had no underlying disease except paraplegia grade 3

below both knees. Preoperative hematological profiles were normal and there was no evidence of leg vein thrombosis. A central venous pressure measurement was not applicable in the presented case. The operation time was unexpectedly prolonged (11 hours) due to extensive multiple spine segments surgery and excessive bleeding (4,000 ml). Multiple transfusions of packed red cells, fresh frozen plasma and leukocyte depleted platelets were given and also Vitamin K 10 mg and tranexamic acid 500 mg. The patient remained intubated and was transferred to the surgical intensive care unit with intermittent pneumatic compression on both legs. The patient did not receive low molecular weight heparin postoperatively because of a prolonged International Normalized Ratio (INR) of 1.26 and a risk of a spinal hematoma. He was successfully extubated 13.5 hours postoperatively, and was transferred to the ward. He began to ambulate a few hours later.

Forty-five hours after the operation, he developed severe hypotension and eventually went into cardiac arrest twice. A high dose infusion of noradrenaline and dopamine were administered after successful cardiopulmonary resuscitation. A bedside transthoracic echocardiography revealed a clot in the main pulmonary artery (PA) and the proximal right main PA, moderate right ventricular dysfunction with tricuspid regurgitation with good ejection fraction.

Correspondence to:

Oofuvong M, Department of Anesthesiology, Faculty of Medicine, Prince of Songkla University, Hat Yai, Songkhla 90110, Thailand.

Phone: 074-451-651, Fax: 074-429-621

E-mail: malewan@yahoo.com

Normal flow with no thrombosis in both femoral veins was reported. Spiral computer tomography revealed massive thrombi in the main PA, right PA, left PA and in both lobar segments of the PA (Fig. 1a, b). There was a massive thrombosis along the superior vena cava (SVC) extending upward to the right brachiocephalic vein. An eighty percent circumferential thrombosis in the SVC was seen (Fig. 1c). There was no clot in the right atrium, right ventricle, or the inferior vena cava. There was good flow in the bilateral femoral veins. Anticoagulant and thrombolytic agents were not administered due to a prolonged INR.

An emergency cardiopulmonary bypass with a pulmonary embolectomy was performed immediately. Multiple large thrombi from the PA and SVC were evacuated (Fig. 1d). The patient developed acute renal failure and severe coagulopathy with a low platelet count (25,000 μ L) postoperatively. The patient's condition did not improve and he responded poorly to blood product transfusions. His condition deteriorated gradually with multiple cardiac arrests and eventually he died 20 hours after the embolectomy.

Discussion

The etiologies of UEDVT were primary DVT (20%) and secondary DVT (80%) such as a central venous catheter insertion, underlying malignancy, surgery on the arm or shoulder,

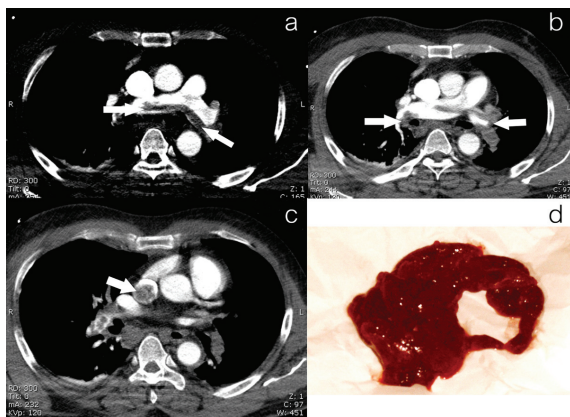


Fig. 1 Preoperative spiral computer tomography of the chest demonstrated a) clot in the right and left pulmonary artery (arrows); b) clot in the right and left lobar segments of the pulmonary artery (arrows); c) clot in the superior vena cava (arrow); and d) multiple massive thrombi, 6 cm long, 2 cm thick from the pulmonary circulation

pregnancy, a thrombophilic state and previous leg vein thrombosis^(1,2,6). The symptoms of UEDVT typically present with pain and swelling of the affected arm, paresthesia, pruritis and vein tenderness, whereas a number of cases have been asymptomatic. The signs account low-grade fever, edema, palpable cord, extremities cyanosis, and dilated cutaneous veins on chest or arms. Making a diagnosis of UEDVT can be difficult, especially asymptomatic subjects^(6,7). With absence of the secondary causes and mechanical vessel compression, the conclusive diagnosis of the presented case has been likely to be true idiopathic UEDVT.

The role of hypercoagulable states in causing both primary and secondary UEDVT remains controversial, mainly due to lack of data. In contrast, the hypercoagulability seems to be a demonstrated risk factor of DVT⁽⁸⁾. Besides, screening for coagulation disorders is arguable, unless idiopathic, recurrent, family history of UEDVT, or recurrent pregnancy loss⁽⁹⁾. The other involving disorders should be considered such as protein C and protein S deficiency and antithrombin III, factor V Leiden, prothrombin gene mutation and hyperhomocystinemia and anti-phospholipid antibodies. The effective diagnosis can be made using ultrasound with color flow Doppler and venography, eventually magnetic resonance angiography⁽¹⁰⁾.

In cases where the thrombosis is severe enough, the patient may appear to have the symptomatic feature of overt UEDVT. The effective treatment of UEDVT is still controversial due to lack of evidence-based support, as randomized controlled trial. Because of high incidence of PE⁽⁶⁾, it is consensus that the minimal appropriation is an anticoagulation intervention, to prevent clot propagation. Contrarily, asymptomatic UEDVT is therefore crucial to concern the indices of suspicion, especially in the case of indwelling catheter, and cancer patients who frequently are asymptomatic carriers of UEDVT⁽¹¹⁾. The sufficient management is based on early diagnosis and therapy. Despite anticoagulation, long-term sequelae and mortality are remarkably high.

Acknowledgements

The authors wish to thank the academic section of the Anesthesia department for providing the artwork.

Potential conflicts of interest

None.

References

1. Owens CA, Bui JT, Knuttinen MG, Gaba RC, Carrillo TC. Pulmonary embolism from upper extremity deep vein thrombosis and the role of superior vena cava filters: a review of the literature. *J Vasc Interv Radiol* 2010; 21: 779-87.
2. Kucher N. Clinical practice. Deep-vein thrombosis of the upper extremities. *N Engl J Med* 2011; 364: 861-9.
3. Margey R, Schainfeld RM. Upper extremity deep vein thrombosis: the oft-forgotten cousin of venous thromboembolic disease. *Curr Treat Options Cardiovasc Med* 2011; 13: 146-58.
4. Geerts WH, Heit JA, Clagett GP, Pineo GF, Colwell CW, Anderson FA Jr, et al. Prevention of venous thromboembolism. *Chest* 2001; 119: 132S-75S.
5. Schizas C, Neumayer F, Kosmopoulos V. Incidence and management of pulmonary embolism following spinal surgery occurring while under chemical thromboprophylaxis. *Eur Spine J* 2008; 17: 970-4.
6. Prandoni P, Polistena P, Bernardi E, Cogo A, Casara D, Verlato F, et al. Upper-extremity deep vein thrombosis. Risk factors, diagnosis, and complications. *Arch Intern Med* 1997; 157: 57-62.
7. Hicken GJ, Ameli FM. Management of subclavian-axillary vein thrombosis: a review. *Can J Surg* 1998; 41: 13-25.
8. Thomas D. Pathogenesis of venous thrombosis. In: Bloom AL, Forbes CD, Thomas DP, Tuddenham EG, editors. *Hemostasis and thrombosis*. 3rd ed. Edinburgh: Churchill-Livingstone; 1994: 1335-47.
9. Joffe HV, Goldhaber SZ. Upper-extremity deep vein thrombosis. *Circulation* 2002; 106: 1874-80.
10. Haire WD, Lynch TG, Lund GB, Lieberman RP, Edney JA. Limitations of magnetic resonance imaging and ultrasound-directed (duplex) scanning in the diagnosis of subclavian vein thrombosis. *J Vasc Surg* 1991; 13: 391-7.
11. Bernardi E, Pesavento R, Prandoni P. Upper extremity deep venous thrombosis. *Semin Thromb Hemost* 2006; 32: 729-36.

ภาวะลิ่มเลือดอุดตันหลอดเลือดดำของรยางค์ส่วนบนสัมพันธ์ต่อการเกิดภาวะลิ่มเลือดอุดตันหลอดเลือดแดงในปอดอย่างรุนแรงจนเสียชีวิตตามหลังการผ่าตัดกระดูกสันหลัง

มลิวัดย์ ออฟูวงศ์, สุภากุล เอี้ยวสกุล, วรวิทย์ จิตติถาวร, พงษ์เทพ วิบูลย์จันทร์

ภาวะลิ่มเลือดอุดตันหลอดเลือดดำของรยางค์ส่วนบนเป็นสิ่งที่อยู่ซึ่งมีความสำคัญทางคลินิกเพิ่มพูนมากขึ้น มีศักยภาพซ่อนแฝงต่อการตายอย่างมาก โดยเฉพาะอย่างยิ่งจากภาวะลิ่มเลือดอุดตันหลอดเลือดแดงในปอด ผู้บริหารรายงานผู้ป่วยเสียชีวิตจากภาวะลิ่มเลือดอุดตันหลอดเลือดแดงในปอดอย่างรุนแรง ด้วยเหตุจากภาวะลิ่มเลือดอุดตันหลอดเลือดดำของรยางค์ส่วนบนของหลอดเลือดใหญ่กลางตัวส่วนบน