

# Case Report

## Radiotherapy in Kimura's Disease: A Report of Eight Cases

Imjai Chitapanarux MD\*, Charin Ya-in MD\*\*,  
Rungaroon Kittichest MD\*, Pimkhuan Kamnerdsupaphon MD\*,  
Vicharn Lorvidhaya MD\*, Vimol Sukthomya MD\*,  
Pichit Sittitrai MD\*\*\*, Tienchai Pattarasakulchai MD\*\*\*

\* Division of Therapeutic Radiology and Oncology, Faculty of Medicine, Chiang Mai University, Chiang Mai

\*\* Department of Pathology, Faculty of Medicine, Chiang Mai University, Chiang Mai

\*\*\* Department of Otolaryngology, Faculty of Medicine, Chiang Mai University, Chiang Mai

---

*Kimura's disease is a rare condition of chronic inflammatory disorder affecting the skin and subcutaneous tissue. It is predominantly in the head and neck region. The lesion is benign but may be persistent/recurrent and difficult to eradicate. Several forms of treatment have been used, including surgical excision, intralesional and oral corticosteroid, cryotherapy and radiotherapy. The authors report eight cases with histopathology consistent with Kimura's disease who received radiation therapy as a primary treatment or secondary treatment for recurrence after surgical excision in the Division of Therapeutic Radiology and Oncology, Chiang Mai University. The prescribed radiation doses varied from 30-40 Gy. With the mean follow-up time of 21 months, all eight patients were still free from disease at the time of analysis.*

**Keywords:** Kimura's disease, Head and neck, Radiotherapy

**J Med Assoc Thai 2007; 90 (5): 1001-5**

**Full text. e-Journal:** <http://www.medassocthai.org/journal>

---

Kimura's disease or eosinophilic lymphfolliculoid granuloma was first described by Kimura et al in 1948<sup>(1)</sup>. The most common clinical manifestation of this disease is a unilateral soft tissue mass in the head and neck area, particularly around the ear. It is also associated with regional lymphadenopathy and subcutaneous mass<sup>(2,3)</sup>. There are some reports in other sites including oral mucosa, nasal cavity, bone, muscle, salivary glands, orbit, lacrimal gland, and tympanic membrane<sup>(4,5)</sup>.

Kimura's disease affects young men. The incidence is high in the 2<sup>nd</sup> and 3<sup>rd</sup> decades<sup>(1,6)</sup>. It appears more common in Oriental men than Caucasians<sup>(8,9)</sup>.

Kimura's disease shares some histopathological features with angiolymphoid hyperplasia with eosinophilia (ALHE). These two lesions have repeatedly been confused and designations used interchangeably<sup>(12)</sup>. The consistent histological features are follicular hyperplasia, eosinophilic infiltrates, and pro-

liferation of post capillary venules<sup>(13)</sup>. The plump endothelial cells (cuboidal to dome-shaped) characteristic of ALHE remains the keys to separation of these entities<sup>(10,14)</sup>. However, many clinical and histopathological features remain distinctly different<sup>(6)</sup>.

### Material and Method

From January 2002 to December 2004, eight patients with Kimura's disease were treated in the Division of Therapeutic Radiology and Oncology, Chiang Mai University, Thailand.

Histological examination was performed and reviewed by two pathologists. All showed the same histopathology of Kimura's disease.

The authors collected all data from the medical records including; age, sex, site of disease, primary treatment, time to recurrence (in case of recurrence disease), radiotherapy technique, total dose of radiotherapy, and the result of treatment.

### Results

#### Patient and tumor characteristics

There were six males and two females. The

---

Correspondence to : Chitapanarux I, Division of Therapeutic Radiology and Oncology, Faculty of Medicine, Chiang Mai University, Chiang Mai 50200, Thailand. Phone & Fax: 053-945-491, E-mail: [imjai@hotmail.com](mailto:imjai@hotmail.com)

mean age was 39 years, range from 24 to 54 years. Five patients had local recurrence after surgical excision. All of them recurred at the same site with time of recurrence from 1 to 15 years. The other three patients had the first time diagnosed. Incisional biopsies were performed in all eight patients. The histopathology of all specimens revealed well circumscribed lesions with separated lymphoid follicles and prominent germinal centers. Proliferation of small vessels with flat to low cuboidal endothelial cells and tissue eosinophilia, some with eosinophilic micro-abscesses, were noted in interfollicular area. Prominent fibrosis around small vessels and lymphoid follicles was observed. The histopathology of the presented patients is shown in Fig. 1. The presenting symptoms in eight patients were painless mass in head and neck area. The most common site of involvement were parotid region in six patients, followed by post auricular region in one patient and submandibular region in the remaining patient.

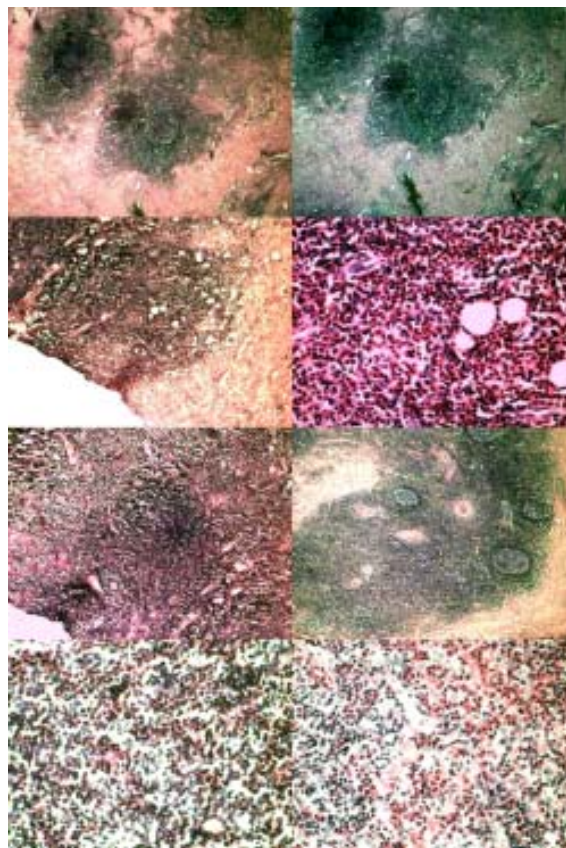
All the baseline characteristics are shown in Table 1.

#### **Radiation therapy**

Radiotherapy was given to all eight patients, nine lesions. Seven patients were treated with appositional fields; mixed beam of electron and photon, one patient who had submandibular lesion was treated with parallel opposing two lateral techniques. The prescribed radiation doses varied from 3000 to 4000 cGy, with 200 cGy per fraction, five fractions per week.

#### **Outcome of treatment**

With the mean follow-up time of 21.75 months (range from 21 to 43 months), local control of the lesion was obtained in all eight patients and nine lesions. At the end of radiotherapy, the authors observed a marked



**Fig. 1** Histopathology of our patients

reduction in tumor size in all lesions and achieved excellent local control at the time of analysis. Only one patient experienced a new lesion in the contralateral parotid region after 18 months of radiotherapy (patient No. 5). She also received radiotherapy to the left parotid area 3000 cGy, the mass disappeared and is still

**Table 1.** Baseline characteristics

No.	Sex	Age	Site	Primary Rx	Time to recurrence (year)	Site of recurrence
1	M	50	Parotid Rt.	Superficial parotidectomy	2	Same
2	M	24	Postauricular Rt, Lt	-	-	-
3	M	33	Parotid Lt.	-	-	-
4	M	30	Parotid Lt.	-	-	-
5	F	40	Parotid Rt.	Surgical excision	2	same
6	M	45	Parotid Rt.	Superficial parotidectomy	1	same
7	F	54	Submandibular Rt.	Surgical excision	15	same
8	M	36	Parotid Rt.	Superficial parotidectomy	4	same

M = Male, F = Female, Rt. = Right, Lt. = Left

**Table 2.** Radiotherapy and outcome

No.	RT technique	RT dose	Result	Follow up time (months)	New lesion
1	Mixed beam	3000	Control	22	-
2	Mixed beam	3600	Control	22	-
3	Mixed beam	3000	Control	25	-
4	Mixed beam	4000	Control	38	-
5	Mixed beam	3000	Control	36	Contralateral parotid mass
6	Mixed beam	4000	Control	31	-
7	Photon: two lateral	4000	Control	43	-
8	Mixed beam	3000	Control	21	-

AP-PA = anteroposterior-posteroanterior

free from recurrence. Table 2 shows the result of treatment. Fig. 2 and 3 show the pictures of patients No. 5 and No. 3 before and after treatment.

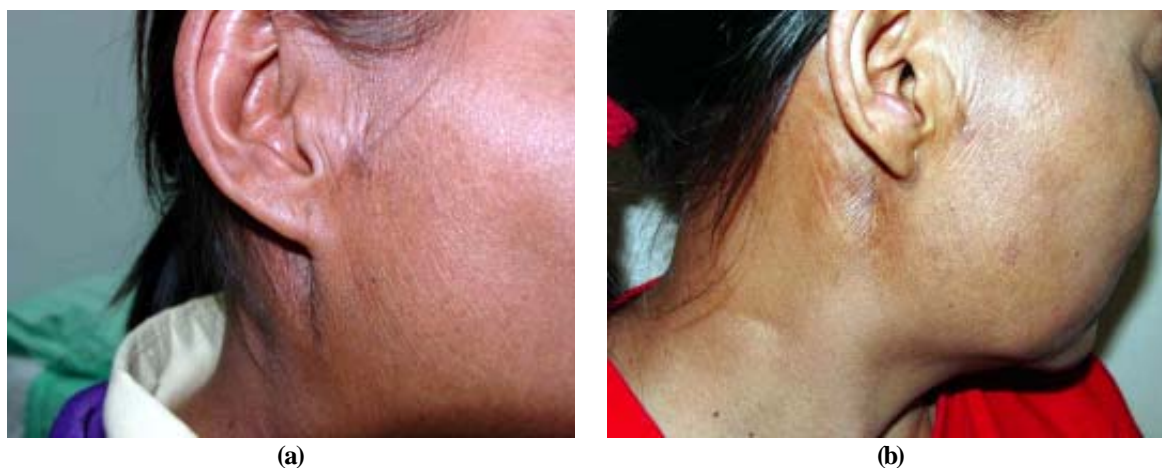### Discussion

Kimura's disease is a chronic inflammatory soft tissue disorder of unknown etiology. This condition is benign but it has been misdiagnosed as a malignant lesion or serious disease, leading to unnecessary radical surgery<sup>(10)</sup>. The most common presentation is a unilateral soft tissue mass in the head and neck area. The authors' result also found the same natural history with only one patient who had bilateral lesions.

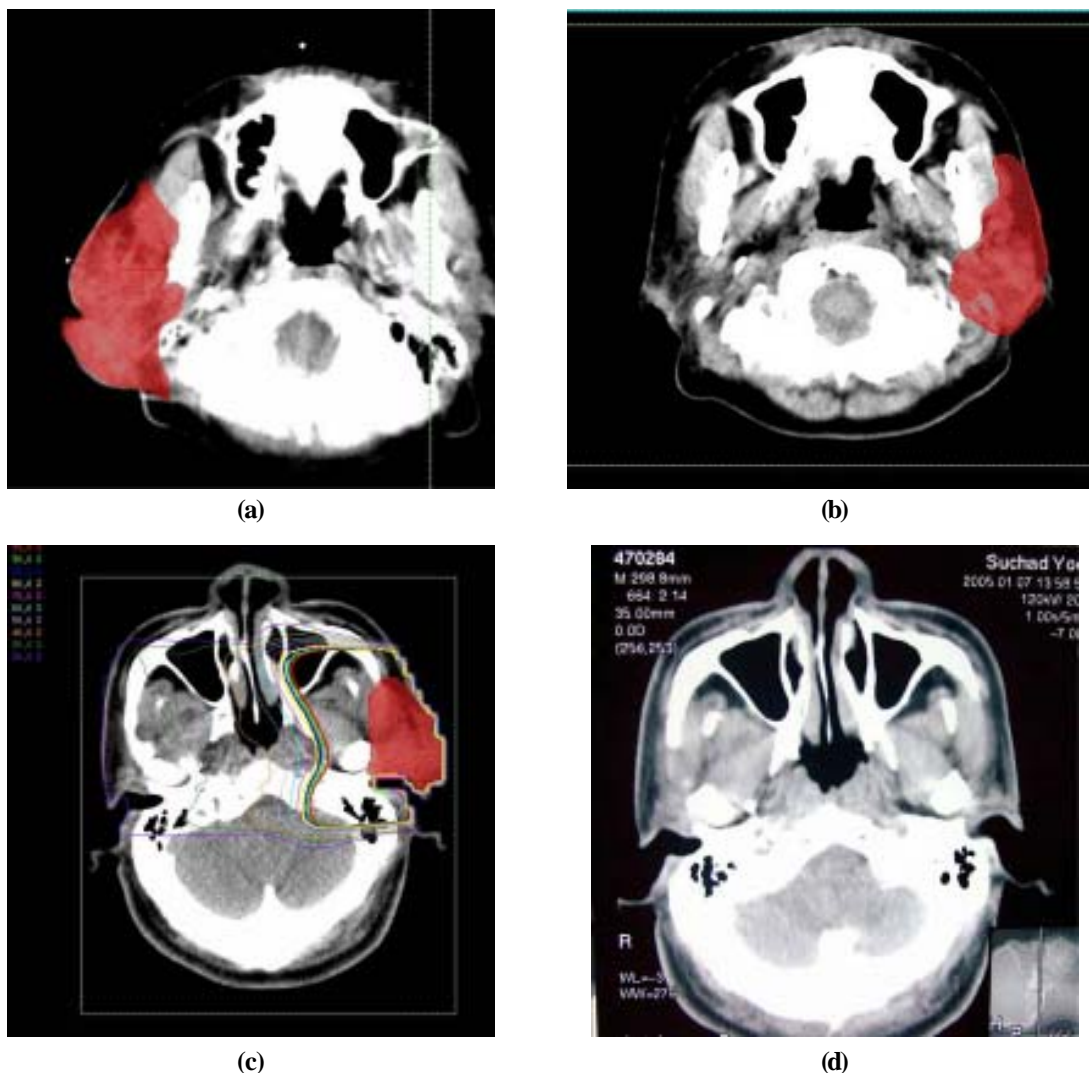
Kimura's disease occurs predominantly in young adult males. Of the eight patients in the present study, only two patients were females, and six patients (75%) were males. The one thing that the authors found

differently from the literatures was the age of the patient. The mean age of the presented patients was 39 years, and two male patients were 45 and 50 years old respectively.

Surgery, radiotherapy, and steroid therapy have been tried, but none has proved to be the optimum modality. Steroid therapy has produced marked response in reduction of tumor size, but after weaning, the tumors often increase in size<sup>(11)</sup>. Surgery with complete excision is very difficult because the infiltrative nature of the tumor and swelling of regional lymph nodes<sup>(11)</sup>. Five patients (62%) in the present study were treated by local excision/radical surgery before. All of them eventually had local recurrence after surgical excision from 1-15 years (mean 4.8 years). However, the authors could control this recurrent disease with radiation therapy.



**Fig. 2** Photographs of case No. 5  
(a) before radiotherapy  
(b) after radiotherapy



**Fig. 3** (a) CT scan of case No. 5: right parotid, before radiotherapy  
 (b) CT scan of case No. 5: right parotid, after radiotherapy; left parotid, recurrence  
 (c) CT scan of case No. 3: left parotid before radiotherapy  
 (d) CT scan of case No. 3: left parotid after radiotherapy

Hareyama et al recommended the limited field of radiotherapy (cover only the lesion and adjacent lymph node) with a dosage of 26-30 Gy<sup>(11)</sup>. The authors gave 30-40 Gy to the lesions and swelling lymph node and had a satisfactory result in every lesion.

The present results suggest that radiotherapy is an effective alternative approach for the primary treatment of Kimura's disease and should be applied for the recurrent disease after surgical excision. The role of adjuvant radiotherapy after surgery is still controversial and needs to be studied.

## References

1. Li TJ, Chen XM, Wang SZ, Fan MW, Semba I, Kitano M. Kimura's disease: a clinicopathologic study of 54 Chinese patients. *Oral Surg Oral Med Oral Pathol Oral Radiol Endod* 1996; 82: 549-55.
2. Katayama H. Bilateral swelling of lacrimal and parotid gland-A case of Mikulicz's disease. *J Jpn Surg Soc* 1904; 9: 411-23.
3. Miller RW, Gilman PA, Sugano H. Differences in lymphocytic disease in the United States and Japan. *J Natl Cancer Inst* 1981; 67: 739-40.



4. Kimura Y, Tsutsumi T, Kuroishikawa Y, Kishimoto S. Angiolymphoid hyperplasia with eosinophilia arising from the facial artery. J Laryngol Otol 2003; 117: 570-3.
5. Krapohl BD, Machens HG, Reichert B, Mailander P. A rare vasoproliferative lesion: angiolymphoid hyperplasia with eosinophilia of the hand. Br J Plast Surg 2003; 56: 168-70.
6. Chan JK, Hui PK, Ng CS, Yuen NW, Kung IT, Gwi E. Epithelioid haemangioma (angiolymphoid hyperplasia with eosinophilia) and Kimura's disease in Chinese. Histopathology 1989; 15: 557-74.
7. Hui PK, Chan JK, Ng CS, Kung IT, Gwi E. Lymphadenopathy of Kimura's disease. Am J Surg Pathol 1989; 13: 177-86.
8. Xoang-Xuan D, Rybojad M, Verola O, Borradori L, Tesseraud F, Gouthi C, et al. Maladie de kimura et hyperplasie angiolymphoide avec eosinophilie. Discussion nosologique and proposde 4 cas. Rev Eur Dermatol MST 1990; 2: 143-54.
9. Hamrick HJ, Jennette JC, LaForce CF. Kimura's disease: report of a pediatric case in the United States. J Allergy Clin Immunol 1984; 73: 561-6.
10. Tseng CF, Lin HC, Huang SC, Su CY. Kimura's disease presenting as bilateral parotid masses. Eur Arch Otorhinolaryngol 2005; 262: 8-10.
11. Hareyama M, Oouchi A, Nagakura H, Asakura K, Saito A, Satoh M, et al. Radiotherapy for Kimura's disease: the optimum dosage. Int J Radiat Oncol Biol Phys 1998; 40: 647-51.
12. Seregard S. Angiolymphoid hyperplasia with eosinophilia should not be confused with Kimura's disease. Acta Ophthalmol Scand 2001; 79: 91-3.
13. Chen H, Thompson LD, Aguilera NS, Abbondanzo SL. Kimura disease: a clinicopathologic study of 21 cases. Am J Surg Pathol 2004; 28: 505-13.
14. Shetty AK, Beaty MW, McGuirt WF Jr, Woods CR, Givner LB. Kimura's disease: a diagnostic challenge. Pediatrics 2002; 110: e39.

## รังสีรักษาในโรคคิมูระ: รายงานผู้ป่วย 8 ราย

อัมใจ ชิตาพนารักษ์, ชรินทร์ ยานินทร์, รุ่งอรุณ กิตติเชษฐ์, พิมพ์ขวัญ กำเนิดศุภผล, วิชาญ หล่อวิทยา, วิมล สุขถมยา, พิชิต สิทธิไตรย์, เฉียรไชย ภัทรสกุลชัย

**ภูมิหลัง:** โรคคิมูระเป็นภาวะการอักเสบเรื้อรังของผิวหนังและเนื้อเยื่อใต้ผิวหนัง พบบ่อยที่บริเวณศีรษะและลำคอ ถือเป็นโรคก้อนท่อน้ำที่ไม่ใช่มะเร็งร้าย แต่มักกลับเป็นซ้ำ, และยากในการกำจัดโรคให้หมดได้ด้วยการผ่าตัด มีการรักษาหลายวิธี ที่นิยมใช้ได้แก่การผ่าตัดเอาก่อนออก, การฉีดคอร์ติโคสเตียรอยด์เข้าไปในก้อน, การกินคอร์ติโคสเตียรอยด์, การใช้เครื่องจี้เย็นและการฉายรังสี

**วัตถุประสงค์:** เพื่อนำเสนอผลการใช้รังสีรักษาในผู้ป่วยโรคคิมูระ

**วัสดุและวิธีการ:** ทำการศึกษาในผู้ป่วยโรคคิมูระ ในหน่วยรังสีรักษาและมะเร็งวิทยา ภาควิชารังสีวิทยา คณะแพทยศาสตร์ มหาวิทยาลัยเชียงใหม่ ที่รับการรักษาตั้งแต่เดือนมกราคม พ.ศ. 2545 ถึงเดือน ธันวาคม พ.ศ. 2547 ด้วยการฉายรังสี ทั้งที่เป็นการรักษาครั้งแรกและเป็นการรักษาหลังจากเกิดการกลับเป็นซ้ำหลังจากทำการผ่าตัด

**ผลการศึกษา:** ผู้ป่วยที่ได้รับการรักษา 8 ราย มีจำนวนรอยโรค 9 แห่ง ได้รับการรักษาด้วยการฉายรังสี 30-40 Gy หลังจากการตรวจติดตามหลังการรักษานานกว่า 21 เดือน พบว่าผู้ป่วยทั้ง 8 ราย ไม่พบมีรอยโรคเกิดซ้ำและไม่พบภาวะแทรกซ้อนหลังการฉายรังสีที่รุนแรง

**สรุป:** การใช้รังสีรักษาไม่จำเป็นการรักษารักษาแรก หรือ ใช้เป็นการรักษาหลังจากที่ผู้ป่วยกลับเป็นซ้ำ ในการรักษาโรคคิมูระมีประสิทธิภาพที่ดีในการควบคุมโรคเฉพาะที่