

# Effect of Concentration of Contrast Medium on Coronary CT Angiography

Thanongchai Siriapisith MD\*, Supavadee Karuwanarint BSc (RT)\*,  
Chulaluk Boonma BSc (RT)\*, Venus Wisetsaeng BSc (RT)\*

\* Department of Radiology, Faculty of Medicine Siriraj Hospital, Mahidol University, Bangkok

**Objective:** To compare concentration of contrast medium for vascular opacification at ascending aorta using retrospective reconstruction of coronary CT angiography.

**Study design:** Retrospective study.

**Material and Method:** Eighty-four patients undergoing coronary CT angiography with 16 multi-detector rows at Siriraj Hospital between September 2003 and July 2004 were included in this study. The patients were categorized into two groups. The first group was administered with 350 mgI/ml contrast medium and the second group was administered with 370 mgI/ml contrast medium. The total amount of contrast medium was about 140 ml (20 ml for timing bolus and 120 ml for CT angiography) in both groups. The CT density on peak contrast administration at ascending aorta was measured and compared between the two groups.

**Results:** The mean density at ascending aorta in 350 mgI/ml and 370 mgI/ml were 362.96 HU (SD 67.53) and 354.44 (SD 59.39), respectively. There was no statistically significant difference in mean density at the ascending aorta between the two groups.

**Conclusion:** Administration of contrast medium with different concentrations of 350 or 370 mgI/ml showed no statistical difference on enhancement of the ascending aorta in coronary CT angiography ( $p < 0.05$ ).

**Keywords:** Coronary artery, CT angiography, Multidetector row CT, Cardiac imaging, Contrast media, Contrast enhancement

*J Med Assoc Thai* 2008; 91 (3): 372-6

Full text. e-Journal: <http://www.medassocthai.org/journal>

Coronary CT angiography (CTA) has become a study of choice for coronary imaging<sup>(1)</sup> in patients with known or suspected coronary artery disease by using multidetector row helical CT (MDCT) with retrospective reconstruction of imaging data<sup>(2,3)</sup>. A retrospective reconstruction is different from the conventional reconstruction of imaging data. However, there is very little raw data using the reconstructive reconstruction technique. The lower amount of data can be compensated by increasing amount of x-ray during scanning. Several protocols suggested that 370-400 mgI/ml<sup>(4-6)</sup> of contrast medium was appropriate for coronary CTA. Normally, the higher concentration of contrast medium is not only expensive but also has increased osmolarity. The purpose of the present study was to verify the effect of different iodine concentra-

tions on ascending aortic enhancement under the conditions of the same injection rate, retrospective reconstruction and time at MDCT using timing bolus technique.

## Material and Method

### Patient

This was a retrospective study in 84 patients undergoing coronary CT angiography with known or suspected coronary artery disease at Siriraj Hospital from September 2003 to July 2004. The inclusion criteria were stable angina pectoris, a stable heart rhythm less than 80 beats per minute, and ability to hold breath for 20 seconds. Exclusion criteria were previous allergic reaction to iodinated contrast medium, renal impairment (serum creatinine level more than 120  $\mu\text{mol/L}$ ), pregnancy, pronounced heart failure, respiratory failure, poor general condition, irregular heart beat (e.g. premature ventricular contraction, atrial fibrillation,

Correspondence to : Siriapisith T, Department of Radiology, Faculty of Medicine, Siriraj Hospital, Mahidol University, Bangkok 10700, Thailand. E-mail: [sitsa@mahidol.ac.th](mailto:sitsa@mahidol.ac.th)

supraventricular tachycardia) and technical failure. All patients had written informed consent. Upon review of the CT images, 17 patients were excluded because technical failure scanning became apparent. Then the 84 enrolled patients were intervened a contrast medium of 350 mgI/ml (group A) or 370 mgI/ml (group B) of iodine concentrations.

### CT scanning

The routine CT angiography was performed in all patients with 16 slices multidetector CT (MDCT) using 0.625 mm interval from 1 cm just below the carina to the base of the heart or 1.25 mm interval from the supraclavicular region to the base of the heart for patients who had a history of coronary bypass graft. The radiation exposure was about 120 kV, 440 mA. The scan time ranged from 18-25 seconds. The reconstruction of images was retrospective reconstruction depending on heart rate.

### Contrast medium

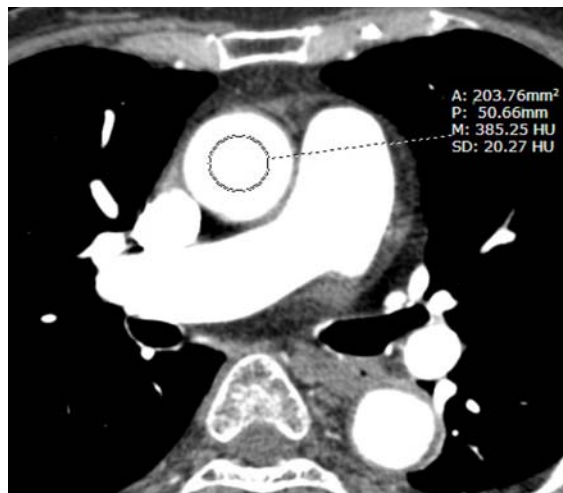
The contrast medium of 350 mgI/ml and 370 mgI/ml was used in group A and group B, respectively. The total amount of contrast medium was the same in all groups (120 ml for scanning plus 20 ml for timing bolus). The contrast medium was intravenously administered with single syringe power injector via antecubital or wrist veins using a 20 or 22 gauge catheter. The scanning delay was determined by testing contrast medium about 20 ml. The peak concentration was measured at the ascending aorta just below the carina 1 cm using a circular region-of-interest (ROI) (Fig. 1, 2). Then coronary scanning was performed after delay times and a bolus of 120 ml of contrast medium injection.

### Statistical analysis

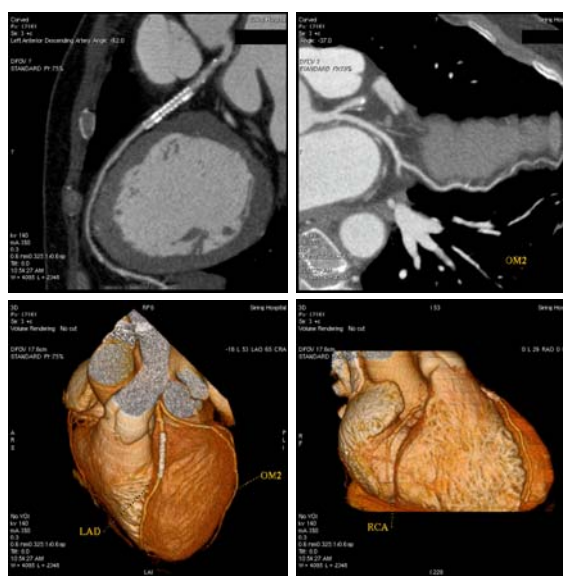
Descriptive statistics were to describe the continuous variables. The peak concentration of contrast medium was measured in mean Hounsfield unit (HU) at the ascending aorta by placing ROI at first reconstruction image. The differences between the two groups were compared by unpaired t-test. The differences were considered significant when p-value was less than 0.05.

### Results

The characteristic of 84 patients were described in Table 1. The mean density at the ascending aorta of males and females in group A was  $354.64 \pm 55.7$  (range 260.95-508.22) and  $374.80 \pm 77.1$  (range 283.70-584.33), respectively. The mean density at the ascend-



**Fig. 1** The first image of retrospective reconstruction of coronary CT angiography  
The ROI is placed at ascending aorta



**Fig. 2** Curved reformation and 3D volume rendering of coronary CT angiography using 350-370 mgI/ml contrast medium with retrospective reconstruction  
The size of coronary is small about 2-3 mm  
There is well opacification of coronary arteries form proximal to distal parts

ing aorta of males and females in group B was  $336.05 \pm 37.7$  (range 291.16-401.46) and  $391.23 \pm 77.5$  (range 279.12-496.80) respectively (Table 2). There were no significant differences in gender.

**Table 1.** Characteristic of 84 patients

	Group A (n = 66)	Group B (n = 18)	Total (n = 84)
Sex			
Male	37	12	49
Female	29	6	35
Age (years)			
Mean $\pm$ SD	64.3 $\pm$ 12.8	60.6 $\pm$ 10.4	63.5 $\pm$ 12.4
Median	67	63	65
Range	15-89	39-84	15-89

**Table 2.** Contrast density at ascending aorta: The group A is concentration of contrast medium 350 mgI/ml and group B is concentration of contrast medium 370 mgI/ml. The patients were deviated by sex and concentration of contrast medium

	Group A (n = 66)	Group B (n = 18)	Total (n = 84)
Sex			
Male	354.64 $\pm$ 55.7 (n = 37)	336.05 $\pm$ 37.7 (n = 12)	350.09 $\pm$ 52.5 (n = 49)
Female	374.80 $\pm$ 77.1 (n = 29)	391.23 $\pm$ 75.5 (n = 6)	377.61 $\pm$ 77.09 (n = 35)
Both	362.96 $\pm$ 67.53 (n = 66)	354.44 $\pm$ 59.39 (n = 18)	361.13 $\pm$ 65.96 (n = 84)

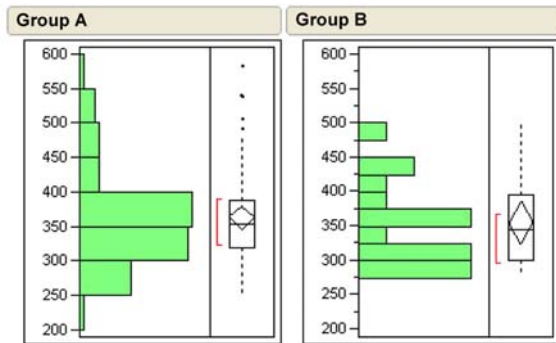
The mean enhancement of ascending aorta in the HU was 362.96  $\pm$  67.53 in group A and 354.44  $\pm$  59.39 in group B (Fig. 3) with no statistical significance ( $p > 0.05$ ).

**Discussion**

Coronary CT angiography has become the CT technique for excluding coronary artery disease. The retrospective reconstruction is different from the

conventional method. The conventional CT and spiral CT have completely 360 degrees of data acquisition for conventional reconstruction but retrospective technique for coronary CT angiography has only 270 degrees, so the data acquisitions are limited for retrospective reconstruction. The concentration of contrast should be concerned for coronary CT angiography because of two reasons; the first one is the very small size of the coronary artery about 2-3 millimeters that needs more contrast for visualization (Fig. 2) and the second one is fewer amounts of data acquisition for reconstruction that need more contrast for data compensation. In addition, the retrospective reconstruction, the concentration of contrast may interfere with CT density in vascular structures. The authors believe that the lower concentration of contrast should yield the same coronary CT images the same as higher concentration.

The ascending aorta is the easiest part of vascular structures for comparison of the effect of different contrast medium concentrations on this retrospective reconstruction of coronary CT angiography. The first image of scanning is at the peak of contrast following calculating timing bolus curve, so the first image is proved to be the maximum concentration of contrast in the present study. There is no statistical difference between two iodine concentrations at the



**Fig. 3** The distribution graph (y-axis: CT density at ascending aorta, x-axis: number of patients) shows similar distribution of mean density (HU) at ascending aorta in group A (350 mgI/ml) and group B (370 mgI/ml)

ascending aorta ( $p < 0.05$ ). Thus, the higher concentration of contrast medium (370 mgI/ml) does not produce more enhancements at the ascending aorta.

The previous comparison study for two iodine concentrations in abdominal aorta, portal vein and liver demonstrated no significant difference between iodine concentrations of 300 and 370 mgI/ml<sup>(8,9)</sup>. In patients with cirrhosis, an increased concentration of iodine improves liver-to-lesion contrast and might improve the detection of hepatocellular carcinoma<sup>(10)</sup>. There was a recent report<sup>(11)</sup> that the rapid administration of moderate concentration of contrast medium was more effective than that of high concentration of contrast medium.

However, Flippo et al<sup>(12)</sup> showed that the increasing iodine concentration yielded proportionally higher vascular attenuation. Awai et al<sup>(13)</sup> recently reported that significantly higher aortic enhancement was obtained with a 370 mgI/ml material than with 300 mgI/ml.

Becker et al<sup>(14)</sup> considered attenuation of 250-300 HU to be optimal for coronary CT angiography, so both concentrations of contrast medium in the present study were enough for vascular enhancement (mean 362.96 for 350mgI/ml and 354.44 mgI/ml for 370 mgI/ml). The lower concentration of contrast medium has several advantages such as being less expensive and has less osmolarity.

Ideally, the best way to assess the efficacy of contrast medium on coronary artery should be to measure attenuation on each branch of coronary from the proximal part to the distal part. The presence of stenosis or occluded vessels can affect enhancement of the coronary artery, particularly on the distal part.

## Conclusion

Administration of contrast medium with an iodine concentration of 350 or 370 mgI/ml had the same effect on enhancement of ascending aorta in retrospective reconstruction images of coronary CT angiography. The lower concentration of contrast gains popularity of lower cost, less osmolarity and less toxicity.

## References

1. Schoepf UJ, Becker CR, Ohnesorge BM, Yucel EK. CT of coronary artery disease. *Radiology* 2004; 232: 18-37.
2. Ohnesorge B, Flohr T, Becker C, Kopp AF, Schoepf UJ, Baum U, et al. Cardiac imaging by means of electrocardiographically gated multisection spiral CT: initial experience. *Radiology* 2000; 217: 564-71.

3. Becker CR, Ohnesorge BM, Schoepf UJ, Reiser MF. Current development of cardiac imaging with multidetector-row CT. *Eur J Radiol* 2000; 36: 97-103.
4. van Hoe L, Marchal G, Baert AL, Gryspeerdt S, Mertens L. Determination of scan delay time in spiral CT-angiography: utility of a test bolus injection. *J Comput Assist Tomogr* 1995; 19: 216-20.
5. Haage P, Schmitz-Rode T, Hubner D, Piroth W, Gunther RW. Reduction of contrast material dose and artifacts by a saline flush using a double power injector in helical CT of the thorax. *AJR Am J Roentgenol* 2000; 174: 1049-53.
6. Cademartiri F, van der LA, Luccichenti G, Pavone P, Krestin GP. Parameters affecting bolus geometry in CTA: a review. *J Comput Assist Tomogr* 2002; 26: 598-607.
7. Platt JF, Reige KA, Ellis JH. Aortic enhancement during abdominal CT angiography: correlation with test injections, flow rates, and patient demographics. *AJR Am J Roentgenol* 1999; 172: 53-6.
8. Suzuki H, Oshima H, Shiraki N, Ikeya C, Shibamoto Y. Comparison of two contrast materials with different iodine concentrations in enhancing the density of the the aorta, portal vein and liver at multi-detector row CT: a randomized study. *Eur Radiol* 2004; 14: 2099-104.
9. Fleischmann D, Rubin GD, Bankier AA, Hittmair K. Improved uniformity of aortic enhancement with customized contrast medium injection protocols at CT angiography. *Radiology* 2000; 214: 363-71.
10. Marchiano A, Spreafico C, Lanocita R, Frigerio L, Di Tolla G, Patelli G, et al. Does iodine concentration affect the diagnostic efficacy of biphasic spiral CT in patients with hepatocellular carcinoma? *Abdom Imaging* 2005; 30: 274-80.
11. Awai K, Inoue M, Yagyu Y, Watanabe M, Sano T, Nin S, et al. Moderate versus high concentration of contrast material for aortic and hepatic enhancement and tumor-to-liver contrast at multi-detector row CT. *Radiology* 2004; 233: 682-8.
12. Cademartiri F, Mollet NR, van der LA, McFadden EP, Stijnen T, de Feyter PJ, et al. Intravenous contrast material administration at helical 16-detector row CT coronary angiography: effect of iodine concentration on vascular attenuation. *Radiology* 2005; 236: 661-5.
13. Awai K, Takada K, Onishi H, Hori S. Aortic and hepatic enhancement and tumor-to-liver contrast: analysis of the effect of different concentrations of contrast material at multi-detector row helical CT. *Radiology* 2002; 224: 757-63.

14. Becker CR, Hong C, Knez A, Leber A, Bruening R, Schoepf UJ, et al. Optimal contrast application for

cardiac 4-detector-row computed tomography. Invest Radiol 2003; 38: 690-4.

---

## การศึกษาผลของการใช้สารทึบรังสีในการตรวจหลอดเลือดหัวใจด้วยเครื่องเอกซเรย์คอมพิวเตอร์ ชนิด 16 หัววัด

ทองชัย สิริอภิสิทธิ์, สุภาวดี คุรุวารินทร์, จุฬาลักษณ์ บุญมา, วินัส วิเศษแสง

**วัตถุประสงค์:** เพื่อศึกษาเปรียบเทียบความเข้มข้นของ contrast medium ในหลอดเลือดแดงใหญ่ส่วน ascending aorta ในการตรวจด้วยเอกซเรย์คอมพิวเตอร์หลอดเลือดหัวใจ

**รูปแบบการศึกษา:** การศึกษาแบบย้อนหลัง

**วัสดุและวิธีการ:** ผู้ป่วยจำนวน 84 รายที่มีอาการสงสัยว่าจะมีโรคหลอดเลือดหัวใจ ซึ่งได้รับการตรวจด้วยเอกซเรย์คอมพิวเตอร์หลอดเลือดหัวใจที่โรงพยาบาลศิริราช ตั้งแต่กันยายน พ.ศ. 2546 จนถึง กรกฎาคม พ.ศ. 2547 ผู้ป่วยเหล่านี้ได้รับ contrast medium ที่แตกต่างกัน 2 ความเข้มข้น กลุ่มแรกได้รับ contrast medium ที่มีความเข้มข้น 350 mgI/mL ส่วนกลุ่มที่สองได้รับ contrast medium ที่มีความเข้มข้น 370 mgI/mL โดยทั้งสองกลุ่มได้รับปริมาณ contrast medium เท่ากันประมาณ 140 มิลลิลิตร (20 mL สำหรับวัดค่าเวลาที่ contrast medium เข้าสู่ตำแหน่งที่ต้องการ และ 120 ml สำหรับ ใช้ตรวจจริง) จากนั้นจึงทำการวัดค่าความเข้มข้นที่หลอดเลือดแดงใหญ่ส่วน ascending aorta เปรียบเทียบกันระหว่างสองกลุ่ม

**ผลการศึกษา:** จากการศึกษาพบว่าความเข้มข้นที่หลอดเลือดแดงใหญ่ส่วน ascending aorta ที่ความเข้มข้นของ contrast medium 350 และ 370 mgI/mL มีค่าเท่ากับ 362.96HU (SD 67.53) และ 354.44 (SD 59.39) ตามลำดับ ซึ่งไม่พบมีความแตกต่างกันอย่างมีนัยสำคัญทางสถิติสำหรับการใช้ contrast medium ทั้งสองกลุ่ม

**สรุป:** ความเข้มข้นของหลอดเลือดแดงใหญ่ส่วน ascending aorta ด้วยการใช้ contrast medium ทั้งสองชนิดในการตรวจเอกซเรย์คอมพิวเตอร์หลอดเลือดหัวใจ ไม่พบมีความแตกต่างกันอย่างมีนัยสำคัญทางสถิติ

---