

# Case Report

## An Extra-adrenal Pheochromocytoma of the Organ of Zuckerkandl: Report of a Case

Supparerk Prichayudh MD\*,  
Kritaya Kritayakirana MD\*, Thiti Snabboon MD\*,  
Suvit Sriussadaporn MD\*, Sukanya Sriussadaporn MD\*,  
Rattaplee Pak-art MD\*, Pornthep Sirimahachaiyakul MD\*,  
Taichiro Tsunoyama MD\*\*, Allan Capin MD\*\*

\* Department of Surgery, Chulalongkorn University, Bangkok, Thailand

\*\* University of Miami, Jackson Memorial Hospital, Miami, Florida, USA

---

*The authors report a case of extra-adrenal pheochromocytoma of the organ of Zuckerkandl presenting with hypertension and an abdominal mass in a young adult. Preoperative diagnosis was made by biochemical and imaging studies. The operation to remove the tumor was successfully performed. The patient remains normotensive and symptom free at 15-month follow-up. The authors also discuss the diagnostic modalities and surgical technique used in the presented patient.*

**Keywords:** Extra-adrenal pheochromocytoma, Organ of Zuckerkandl

**J Med Assoc Thai 2009; 92 (11): 1532-7**

**Full text. e-Journal:** <http://www.mat.or.th/journal>

---

Pheochromocytomas are rare tumors arising from chromaffin cells of adrenal medulla that can secrete catecholamine and are responsible for less than 1% of adult hypertension<sup>(1,2)</sup>. Pheochromocytomas are most commonly found in adrenal glands (adrenal medulla). Extra-adrenal pheochromocytomas (EAPs), sometimes-called paragangliomas, are even rarer tumors accounting for 10-25% of pheochromocytomas<sup>(1,2)</sup>. The most common site (53%) of EAPs is at the organs of Zuckerkandl (O of Z), which are a collection of paraganglia located just below the origin of the inferior mesenteric artery<sup>(1)</sup>. In the present article, the authors describe a patient with a large, functioning EAP of the O of Z who underwent successful surgical treatment.

### Case Report

A 23-year-old female patient presented with headache, palpitations, and diaphoresis that started 9 years ago. At that time, she was diagnosed as having hypertension and had been receiving anti-hypertensive medication from a rural hospital. She had

no family history of cancer or endocrine disease. Two years prior to admission in Chulalongkorn Hospital, she started to feel a mass in her lower abdomen devoid of pain or gastrointestinal symptoms. In addition to this presentation, the patient also described a worsening of the aforementioned symptoms and had a measured blood pressure of 200/120 mmHg. She was then admitted to a provincial hospital and worked up. Magnetic resonance imaging (MRI) of the abdomen showed a lobulated, 13.0 x 8.5 x 9.0 cm hyperintense mass at the prevertebral area extending from just below the origin of inferior mesenteric artery to just below the aortic bifurcation, with pressure effect to the aorta (Fig. 1). Her blood pressure was controlled by multiple anti-hypertensive drugs consisting of prazosin, atenolol, and propranolol and subsequently, she was referred to Chulalongkorn Hospital for definitive treatment.

At Chulalongkorn Hospital, her vital signs were normal (blood pressure of 110/70 mmHg) and her physical examination revealed no abnormality besides a non-tender well-defined, 13 x 10 cm mass at lower abdomen. The mass was firm, fixed, and had no thrill or bruit. The authors obtained an endocrine consult based on strong suspicion of an EAP (hypertension in a

---

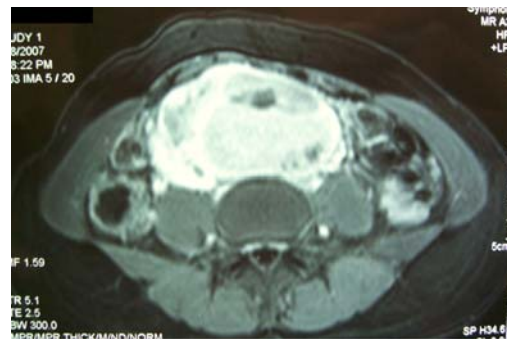
Correspondence to: Prichayudh S, Department of Surgery, Chulalongkorn University, Rama 4 Rd, Bangkok, Thailand. Phone: 0-2256-4117, Fax: 0-2256-4117, E-mail: Supparerk.P@Chula.ac.th

young patient and abdominal mass). Her 24-hour urinary hormonal analysis showed an increase in epinephrine, norepinephrine, metanephrine, normetanephrine, and vanillylmandelic acid (VMA) levels.

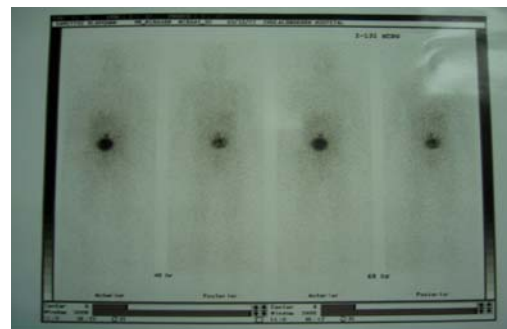
Her MRI was reviewed again by radiologists. There was no adrenal tumor, liver metastasis, or any abnormal mass other than the tumor previously described. However, the possibility of inferior vena cava and/or aortic invasion by the mass could not be ruled out. There was no evidence of renal vessel involvement by the tumor. To rule out multiple neuroendocrine tumors, the authors ordered serum calcium, carcinoembryonic antigen, calcitonin, parathyroid hormone, and cortisol levels. All results came back normal.

At this point, the diagnosis of extra-abdominal pheochromocytoma was confirmed. To rule out extra abdominal tumors, the authors obtained I-131 metaiodobenzyl guanidine (MIBG) scan. Upon completion of study day 3, no evidence of other functioning tumor tissue was detected besides the lower abdominal mass (Fig. 2).

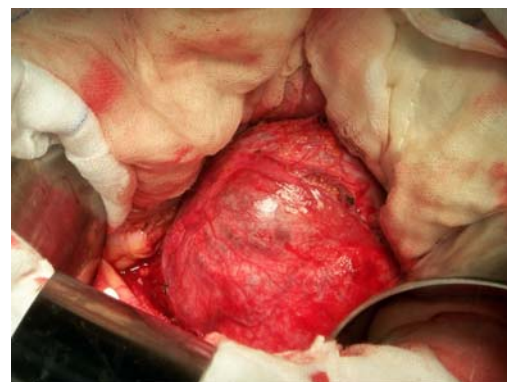
The patient's blood pressure had been well controlled using a combination of alpha (prazosin) and beta-blockers (propranolol). After thorough discussion about procedural risks and benefits with our patient, the authors decided to perform a laparotomy to excise the tumor. Preparation of abdominal skin and bilateral thighs (for possible saphenous vein graft harvesting) was performed, followed by a lower midline incision. Upon initial exploration, the authors found a 13 x 10 x 8 cm lobulated, well-encapsulated retroperitoneal mass located anterior to the bifurcation of the aorta and the inferior vena cava, just below the origin of inferior mesenteric artery (Fig. 3). The authors began with a thorough exploration of the entire peritoneal cavity including bilateral adrenal glands to rule out a co-existing adrenal tumor. The authors then obtained exposure to the mass by mobilizing the entire small intestine to the right, and incising the peritoneum overlying the mass. Great care was taken not to over-manipulate the mass to prevent iatrogenic catecholamine release from the tumor. Meticulous dissection was initiated to identify and preserve both ureters, which were displaced anterolateral to the tumor mass with no evidence of tumor invasion. Subsequently, dissection was continued to the inferior aspect of the mass. During dissection, the authors encountered several small sized vascular arterial branches of aortic origin, as well as, similar sized venous drainage to the inferior vena cava. Both were carefully controlled by individual ligation and clipping. The plane of dissection was



**Fig. 1** The T2-weighted magnetic resonance imaging of the abdomen at the level of aortic bifurcation after gadolinium injection shows an enhanced, lobulated, 13.0 x 8.5 x 9.0 cm hyperintense mass at the prevertebral area



**Fig. 2** The whole body I-131 metaiodobenzyl guanidine (MIBG) scan image at 48 hours after radiotracer administration shows a large I-131 MIBG avid tumor at mid abdomen region. No evidence of other functioning tumor tissue was detected



**Fig. 3** A 13 x 10 x 8 cm, lobulated, well-encapsulated retroperitoneal mass was found upon abdominal exploration

between the posterior aspect of the mass and the anterior aspect of both the aorta and inferior vena cava. Direction of dissection was from inferior to superior. There was no evidence of direct invasion of the tumor to the great vessels. The authors were able to remove the mass after 120 minutes of operative time. The abdomen was closed by primary fascial closure. Intra-operatively, blood pressure was controlled with intravenous nicardipine drip, and had been stable throughout the operation. At the end of the operation, an estimated blood loss was 1,500 cc, mainly from small feeding vessels bleeding despite attempts to control them. The patient received four units of packed red blood cells and four units of fresh frozen plasma.

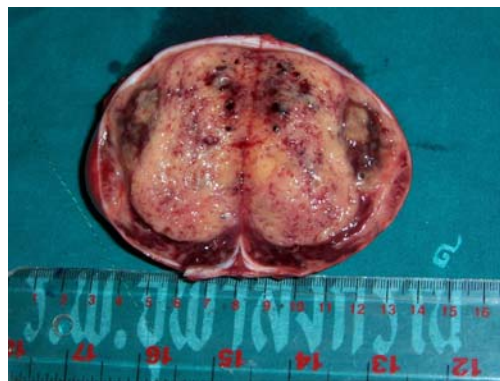
Post-operatively, the patient was observed in a surgical intensive care unit for one day and subsequently, transferred to a regular surgical floor. Her blood pressure was within normal range without the use of anti-hypertensive drugs. The patient was discharged uneventfully on post operative day 7.

Pathologic report of the mass revealed a yellowish-brown colored well-circumscribed mass. Cut surface described a rubbery-firm, yellow, homogenous mass. Microscopic examination showed neoplastic cells arranged in an organoid pattern with basophilic cytoplasm. Each tumor cell nest was surrounded by spindle-shaped sustentacular cells (Fig. 4A, 4B). The margins of resection were free. Immunohistochemical study showed a strongly positive stain to chromogranin and focally positive stain to synaptophysin. S-100 protein were also positive in both chief cells and sustentacular cells. All of the findings were suggestive of an extra-adrenal pheochromocytoma.

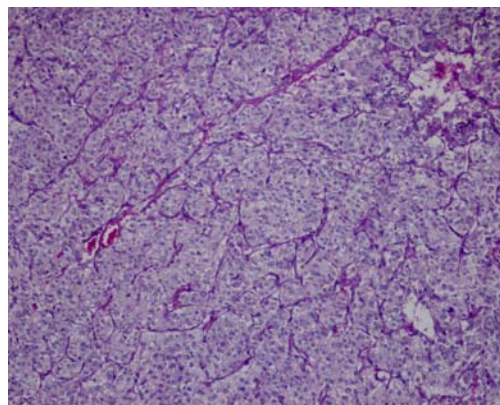
Upon the third week follow-up, the patient was normotensive and did not require any anti-hypertensive drug. Her 24 hour urinary metanephrine descended to 254.17 µg and urinary normetanephrine went down to 291.70 µg. Genetic based study for a mutation in the succinate dehydrogenase subunit B (SDHB) was found negative. At the 15<sup>th</sup> month follow-up (January 2009), the patient remained normotensive and had no recurrent mass detected.

## Discussion

Pheochromocytomas are catecholamine releasing tumors and cause hypertension in only 0.1% of all hypertensive patients<sup>(3)</sup>. About 75-90% of pheochromocytomas are in the medulla of the adrenal glands and other 10-25% are extra-adrenal<sup>(1)</sup>. The most common site of EAPs has been reported to be the



**Fig. 4A** Gross pathology revealed a yellowish, brown colored well circumscribed mass. Cut surface unveils a homogenous rubbery to firm yellow appearance



**Fig. 4B** Microscopic examination shows neoplastic cells arranged in an organoid pattern with basophilic cytoplasm

superior para-aortic region, specifically with location to the renal hilus<sup>(4)</sup>. Recently, Madani et al reported 53% of all EAPs to be located at the inferior para-aortic region (*i.e.* the O of Z)<sup>(1)</sup>. Paraganglia in the inferior para-aortic region located just below the origin of the inferior mesenteric artery are called O of Z. The O of Z is well developed in the infant and child until age 3, but in the adult, it may be indistinguishable from a small lymph node

Seventy-seven percent of EAPs in the O of Z are functioning clinically, causing signs of sympathetic stimulation such as headache, palpitations, diaphoresis, and anxiety<sup>(5)</sup>. Because of these nonspecific symptoms, the diagnosis is often delayed. The most common sign is hypertension, which is seen in 74% of patients with



EAPs of the O of Z<sup>(6)</sup>. Other symptoms include abdominal pain, lower back pain, and presence of an abdominal mass. Atypical presentations of EAPs of the O of Z include deep vein thrombosis of lower extremities<sup>(7)</sup>, small bowel obstruction<sup>(8)</sup>, and spontaneous retroperitoneal bleeding<sup>(6)</sup>.

Because of the pathological difficulty in differentiation between benign and malignant EAPs, malignancy is therefore based on the presence of local invasion and/or metastases (bone, liver, or lungs). The incidence of malignancy in extra-adrenal paragangliomas is 2 to 4 times greater than the often-quoted 10% for pheochromocytomas<sup>(2)</sup>. The largest case review of 135 EAPs of the O of Z discovered that 41% of these tumors were malignant<sup>(6)</sup>.

Most pheochromocytomas are sporadic, but about 10% are familial with an autosomal dominant inheritance. Examples of these familial disorders are multiple neuroendocrine neoplasm type IIa and IIb, von Hippel Lindau syndrome, and neurofibromatosis<sup>(2)</sup>. DNA sequence analysis determined that a heterozygous germline mutation in the Succinate Dehydrogenase Subunit B (SDHB) gene on chromosome 1p36 is associated with familial paraganglioma and familial pheochromocytoma<sup>(9)</sup>.

To establish a catecholamine-secreting property of the tumor, the traditional method is to obtain a 24-hour urine collection for norepinephrine, epinephrine, and VMA levels<sup>(6)</sup>. Madani et al reported that in 19 patients with EAPs, most of tumors secreted only norepinephrine (63%), while 11% of tumors secreted only epinephrine. Sixteen percent of EAPs were found to secrete both norepinephrine and epinephrine as occurred in our patient<sup>(1)</sup>.

Computed tomography (CT) and MRI have been utilized to determine the EAPs location, number, and presence of invasion to adjacent organs. CT scanning has limitations in detecting tumors smaller than 2 cm and might also be hypertensive-inducing secondary to intravenous contrast injection<sup>(6,10)</sup>. MRI has higher sensitivity and specificity than CT, particularly in para-aortic regions and urinary bladder. EAPs are hypo-intense to iso-intense on T1W sequences, hyper-intense on T2W sequences, and enhance intensely following Gadolinium injection as shown in Fig. 1<sup>(2)</sup>. I-131 MIBG scan is suited for an initial localization of functioning EAPs and metastatic lesions, but its' role in non-functioning EAPs is not clear<sup>(6)</sup>. In patients with metastatic pheochromocytoma<sup>(11)</sup>, newer imaging studies such as positron emission tomography (PET) has demonstrated

superiority to IMBG scan, particularly in localizing metastatic disease sites.

If the patient has a functional tumor, the patient generally receives preoperative medication to prevent life threatening complications. Alpha 1-adrenergic antagonists are used to control hypertension. Major alpha 1-adrenergic antagonists are phentolamine (short half-life) and phenoxybenzamine (long half-life). Beta-adrenergic antagonists are added if the patient is either tachycardic or arrhythmogenic. Beta-blockade should never be used before alpha-blockade because this will cause unopposed vasoconstriction. Furthermore, due to concerns of postoperative hypotensive exacerbation, some institutions discourage routine administration of adrenergic antagonists. If the drug is given, surgeons can be deprived of hypertension as a sign of additional occult tumors<sup>(12)</sup>. The presented patient received a preoperative combination of the alpha-blocker (prazosin) and beta-blocker (atenolol). Satisfactory blood pressure control and no postoperative hypotension were experienced.

Surgery remains the treatment of choice for EAPs of the O of Z<sup>(6)</sup>. All efforts should be made to remove the entire tumor in order to maximize the chance of curative resection<sup>(13)</sup>. Although the successful cases of laparoscopic resection of EAPs of the O of Z have been reported, it seems that laparoscopy is suited for small (less than 7 cm), benign appearing tumors without adjacent organ invasion<sup>(14-16)</sup>. In the presented case, the tumor appeared to be large (13 x 10 x 8 cm) and invasion of the aorta and the inferior vena cava could not be ruled out preoperatively. Thus, it seemed safer to perform an open surgery in this patient.

In the presented patient, dissection started at the inferior aspect of the tumor and progressed towards the superior aspect in the plane between the tumor and the great vessels (*i.e.* the aorta and the inferior vena cava). In the authors' opinion, this approach facilitated tumor removal substantially. Care should be taken to control several small vessels from the aorta and the inferior vena cava, and to identify and preserve both ureters. Fortunately, there was no vascular invasion by the tumor in the presented case. Major vascular invasions require more aggressive resections and reconstructions, which historically, have been performed successfully<sup>(7,17)</sup>.

## Conclusion

EAPs of the O of Z are rare tumors that can cause secondary hypertension or other symptoms

related to the mass. Pre-operative evaluations include biochemical studies (to determine catecholamine secretory) and imaging studies (to localize tumors). The possibilities of multiple neuroendocrine tumors and familial tendency should always be considered. Surgery remains the only cure and all attempts should be made to completely remove the mass, whenever possible.

## References

1. Madani R, Al Hashmi M, Bliss R, Lennard TW. Ectopic pheochromocytoma: does the rule of tens apply? *World J Surg* 2007; 31: 849-54.
2. Salanitri J, Smith P, Schlicht S. Multifocal malignant extra-adrenal paragangliomas of the Organ of Zuckerkandl and urinary bladder. *Australas Radiol* 2001; 45: 229-32.
3. Manger WM, Gifford RW Jr, Hoffman BB. Pheochromocytoma: a clinical and experimental overview. *Curr Probl Cancer* 1985; 9: 1-89.
4. Schwartz EL, Mao P, Hernried O, Born EE, Waldmann EB. Catecholamine-secreting paraganglioma. The problem of classification. *Arch Intern Med* 1975; 135: 978-85.
5. Hendry DT. Functioning phaeochromocytoma of the organ of Zuckerkandl. *S Afr Med J* 1970; 44: 564-5.
6. Subramanian A, Maker VK. Organs of Zuckerkandl: their surgical significance and a review of a century of literature. *Am J Surg* 2006; 192: 224-34.
7. Stevenson S, Ramani V, Nasim A. Extra-adrenal pheochromocytoma: an unusual cause of deep vein thrombosis. *J Vasc Surg* 2005; 42: 570-2.
8. Blecha M, Galanopoulos C, Dharkar D, Salti G. Massive organ of Zuckerkandl inducing small bowel obstruction. *J Am Coll Surg* 2005; 201: 480-1.
9. Donahue J, Sahani D, Tso L, Cusack JC Jr. Extra-adrenal pheochromocytoma involving the organ of Zuckerkandl. *Surgery* 2008; 143: 830-2.
10. Doppman JL, Reinig JW, Dwyer AJ, Frank JP, Norton J, Loriaux DL, et al. Differentiation of adrenal masses by magnetic resonance imaging. *Surgery* 1987; 102: 1018-26.
11. Ilias I, Yu J, Carrasquillo JA, Chen CC, Eisenhofer G, Whately M, et al. Superiority of 6-[18F]-fluorodopamine positron emission tomography versus [131I]-metaiodobenzylguanidine scintigraphy in the localization of metastatic pheochromocytoma. *J Clin Endocrinol Metab* 2003; 88: 4083-7.
12. Gifford RW Jr, Manger WM, Bravo EL. Pheochromocytoma. *Endocrinol Metab Clin North Am* 1994; 23: 387-404.
13. Sclafani LM, Woodruff JM, Brennan MF. Extraadrenal retroperitoneal paragangliomas: natural history and response to treatment. *Surgery* 1990; 108: 1124-9.
14. Kravarusic D, Pinto-Rojas A, Al Assiri A, Sigalet D. Laparoscopic resection of extra-adrenal pheochromocytoma - case report and review of the literature in pediatric patients. *J Pediatr Surg* 2007; 42: 1780-4.
15. Thapar PM, Dalvi AN, Kamble RS, Vijaykumar V, Shah NS, Menon PS. Laparoscopic transmesocolic excision of paraganglioma in the organ of Zuckerkandl. *J Laparoendosc Adv Surg Tech A* 2006; 16: 620-2.
16. Nadler EP, Hackam DJ. Laparoscopic resection of a pheochromocytoma at the organ of Zuckerkandl in a 13-year old child. *Surg Endosc* 2008; 22: 1348.
17. Dossett LA, Rudzinski ER, Blevins LS, Chambers EP Jr. Malignant pheochromocytoma of the organ of Zuckerkandl requiring aortic and vena caval reconstruction. *Endocr Pract* 2007; 13: 493-7.

---

## เนื้องอกฟีโอโครโมไซโตมา ที่อวัยวะชัศเคอร์แคนเดล: รายงานผู้ป่วย

ศุภฤกษ์ ปรีชายุทธ, กฤตยา กฤตยาภิรม, ธิดิ สันบุญ, สุวิทย์ ศรีอัมภพร, สุกัญญา ศรีอัมภพร,  
รัฐพลี ภาคอรธ, พรเทพ สิริมหาไชยกุล, ไทชิโร่ ทสึโนยามา, อลัน เคป็น

ได้รายงานผู้ป่วยเนื้องอกฟีโอโครโมไซโตมา ที่อวัยวะชัศเคอร์แคนเดลที่มีภาวะความดันโลหิตสูงตั้งแต่อายุน้อย และก่อนที่จะมีอาการนำผู้ป่วยได้รับการวินิจฉัยก่อนผ่าตัดโดยการตรวจทางชีวเคมีและการตรวจทางรังสีวิทยา และได้รับการผ่าตัดเพื่อเอาเนื้องอกออกในเวลาต่อมา จากการตรวจติดตามผู้ป่วยที่เวลา 15 เดือนหลังผ่าตัด พบว่า ผู้ป่วยมีความดันโลหิตปกติและไม่มีอาการผิดปกติแต่อย่างใด ผู้วิจัยได้รายงานถึงการเลือกวิธีการตรวจวินิจฉัยที่เหมาะสม และวิธีการผ่าตัดก่อนเนื้องอกด้วย

---