

Case Report

Atypical Manifestation of Progressive Outer Retinal Necrosis in AIDS Patient with CD4⁺ T-Cell Counts More Than 100 Cells/ μ L on Highly Active Antiretroviral Therapy

Pornpattana Vichitvejpaisal MD*,
Somporn Reeponmahar MD*, Woraphot Tantisiriwat MD**

* Department of Ophthalmology, Faculty of Medicine, Srinakharinwirot University, Nakhon Nayok, Thailand

** Department of Preventive and Social Medicine, Faculty of Medicine,
Srinakharinwirot University, Nakhon-nayok, Thailand

Typical progressive outer retinal necrosis (PORN) is an acute ocular infectious disease in acquired immunodeficiency syndrome (AIDS) patients with extremely low CD4⁺ T-cell counts. It is a form of the Varicella-zoster virus (VZV) infection. This destructive infection has an extremely rapid course that may lead to blindness in affected eyes within days or weeks. Attempts at its treatment have had limited success. We describe the case of a bilateral PORN in an AIDS patient with an initial CD4⁺ T-cell count >100 cells/ μ L that developed after initiation of highly active antiretroviral therapy (HAART). A 29-year-old Thai female initially diagnosed with human immunodeficiency virus (HIV) in 1998, presented with bilaterally decreased visual acuity after initiating HAART two months earlier. Multiple yellowish spots appeared in the deep retina without evidence of intraocular inflammation or retinal vasculitis. Her CD4⁺ T-cell count was 127 cells/ μ L. She was diagnosed as having PORN based on clinical features and positive VZV in the aqueous humor and vitreous by polymerase chain reaction (PCR). Despite combined treatment with intravenous acyclovir and intravitreal ganciclovir, the patient's visual acuity worsened with no light-perception in either eye. This case suggests that PORN should be included in the differential diagnosis of reduced visual acuity in AIDS patients initiating HAART with higher CD4⁺ T-cell counts. PORN may be a manifestation of the immune reconstitution syndrome.

Keywords: Progressive outer retinal necrosis, Varicella-zoster virus, Acquired immunodeficiency syndrome, Highly active antiretroviral therapy

J Med Assoc Thai 2009; 92 (Suppl 3): S52-6

Full text. e-Journal: <http://www.mat.or.th/journal>

Patients with acquired immunodeficiency syndrome (AIDS) are susceptible to several ophthalmic opportunistic infections within the members of the herpes virus family, *Toxoplasma gondii*, *Cryptococcus neoformans*, *Pneumocystis jirovecii*, *Candida* species, and bacteria⁽¹⁾. Necrotizing herpetic retinopathies (NHR) are disorders induced by herpes viruses including cytomegalovirus (CMV), varicella-zoster virus (VZV), and herpes simplex virus (HSV). The clinical presentation of these retinopathies depends

on the immune status of the patients. Usually we find cytomegalovirus (CMV) retinitis in patients with AIDS who have extremely low CD4⁺ T-cell counts (< 50 cells/ μ L). Varicella-zoster virus (VZV) retinitis produces one of the two patterns of retinal involvement, each with its own characteristic clinical features. The two patterns are acute retinal necrosis syndrome (ARN) and progressive outer retinal necrosis (PORN). ARN can be caused either by herpes simplex virus (HSV) or varicella-zoster virus (VZV) or both. ARN may develop in immuno-compromised patients as well as in healthy people.

PORN has been established as a clinically distinct form of viral retinitis in AIDS patients, since

Correspondence to: Tantisiriwat W, Department of Preventive and Social Medicine, Faculty of Medicine, Srinakharinwirot University, Nakhon Nayok 26120, Thailand. E-mail: woraphot@swu.ac.th

the first report by Foster et al⁽²⁾, described this disease in two patients with AIDS in 1990. PORN can be differentiated from other forms of viral retinitis by its characteristic deep retinal lesions at the onset, frequent macular involvement, rapid progression course, no or minimal ocular inflammation in the aqueous and vitreous humor, and the absence of the retinal vasculitis⁽³⁾. Most patients with PORN have a poor ophthalmologic prognosis because the retinal necrosis tends to be followed by rhegmatogenous retinal detachment, and responds poorly to antiviral treatment. Progression to the loss of light-perception occurs in two thirds of the patients because of the photoreceptor necrosis involving the atrophic retina. Treatment with acyclovir alone seems to be ineffective, but the combination of the antiviral treatment with ganciclovir and foscarnet has been reported to have better outcome⁽⁴⁾.

We report an atypical manifestation of PORN in an AIDS patient after two months of Highly Active Antiretroviral Therapy (HAART) and CD4⁺ T-cell counts > 50 cells/ μ L.

Case Report

A 29-year-old Thai female patient presented with decreased visual acuity in both eyes for 20 days duration. The patient was pregnant with the first child at the age of seventeen, when she was found to be infected with human immunodeficiency virus (HIV) in 1998. In January 2003, she was pregnant again with the second child and came to our hospital. Her CD4⁺ T-cell count was 380 cells/ μ L and HIV viral load was 214,188 copies/mL. She received HAART (AZT, 3TC, Nevirapine) to prevent maternal-child HIV transmission but was lost to follow-up after delivery.

In January 2008, she presented with severe headache and dyspnea. She was diagnosed with cryptococcal meningitis, pulmonary tuberculosis (TB) and AIDS. She received treatment for cryptococcal infection and TB. One month later, she was initiated on HAART (d4T, 3TC and efavirenz).

After 2 months of HAART, the patient complained of painless visual disturbance in left eye for 2 weeks, and markedly decreased vision in her right eye for 3 weeks. Visual acuity was poor for light-projection in the right eye and no light-perception at all in the left eye. Slit-lamp examination showed no inflammatory cells in the anterior chamber of the right eye, but moderate cells and flare in the anterior chamber of the left eye. Ophthalmoscopic examination revealed deep, multifocal coalescent whitish cellular

infiltrates at the outer retina posteriorly positioned mainly along the superior major retinal vascular arcade with inferior extensions to macular region of the right eye with few outer retinal blot hemorrhages. The major retinal veins shown some degree of dilatation and tortuosity. Optic disc edema was also noted in the right eye (Fig. 1). The left eye could not be examined because of dense vitreous hemorrhage with the anterior chamber filled with cells (later proved to be red blood cells).

The patient was referred to the infectious disease specialist, who made a presumptive diagnosis of immune reconstitution syndrome (IRIS) based upon a preserved CD4⁺ T-cell count (127 cells/ μ L, tested 2 months before the presentation) and recent initiation of antiretroviral therapy. She was then given prednisolone 1mg/kg/day.

Five days later, she came for the follow-up at the eye clinic. Retinitis had worsened by ophthalmoscopic examination. The outer retinal infiltration had progressed in areas of preexisting lesions with new emerging focal lesions. New areas of involvement included the major vascular arcade and nearly the entire peripheral-retina from the inferior retina to the posterior pole with partial sparing in the maculopapular areas. There was disappearance of previous outer retinal blot shaped hemorrhages with new hemorrhage sites (Fig. 2). The lesion was diagnosed as PORN on the basis of the clinical appearance and its rapid progression.

The patient, then, was admitted to the hospital for intravenous and intravitreal treatment. Intravenous acyclovir, 500 mg every 8 hours, was

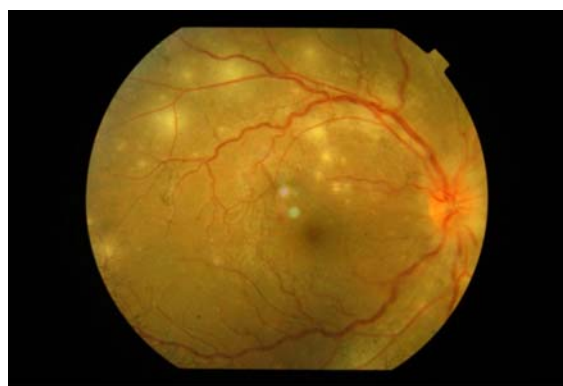

Fig. 1 Ophthalmoscopic appearance in the right eye on the initial visit. Optic disc edema and the absence of vitreous or signs of active vasculitis

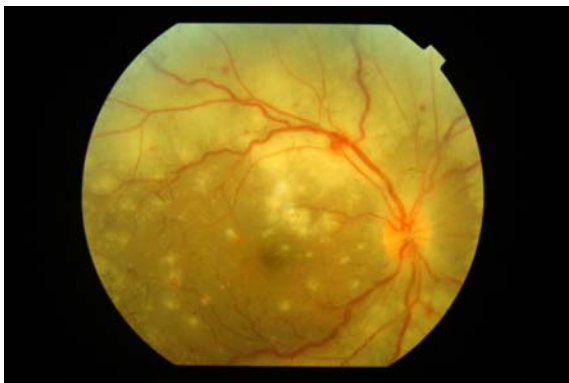


Fig. 2 Subsequent fundus photographs of right eye demonstrating rapid spread from the posterior pole to involve the entire retina within 5 days

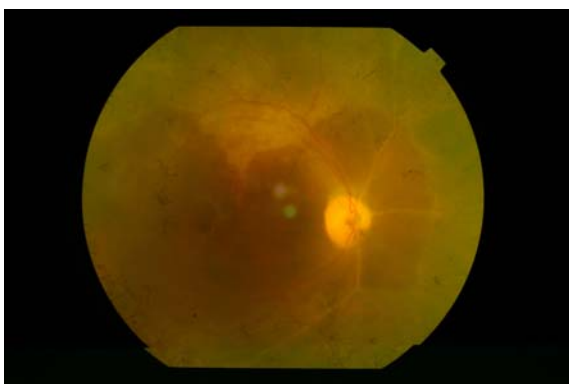


Fig. 3 The right fundus demonstrating severe disease end-stage disease after one month

administered for 2 weeks. Intravitreal ganciclovir was injected in the right eye. Vitreous humor from the left eye was sent for PCR analysis. Prednisolone was tapered off.

The PCR analysis of the vitreous humor was positive for VZV and negative for HSV and CMV. Despite therapy, she had no light-perception at all in either eye (17 days after the first visit). We, therefore, sent the aqueous humor and vitreous humor from the right eye to PCR again, and the result was again positive for VZV, but negative for HSV and CMV. Her current CD4⁺ T-cell count was now 167 cells/ μ L. Retinal detachment did not occur at any time during the clinical course.

Discussion

PORN is a form of NHR caused by VZV and found predominantly in patients with advanced

AIDS⁽²⁾. It is thought to be the second most common AIDS-related opportunistic retinal infection after CMV retinitis. PORN is rare and found mostly in people with AIDS, but there are also reports in non-AIDS cases⁽⁵⁻⁷⁾. Common clinical features in PORN are decreased visual acuity or constricted peripheral fields⁽²⁾. Clinical findings of PORN rarely include inflammatory responses or vasculitis. Multifocal, discrete, opacified lesions begin in the outer retinal layers of the periphery and/or posterior pole that rapidly coalesce over the course of the days or weeks sparing the macular area initially. PORN is further characterized by an extremely poor prognosis with a poor response to antiviral treatment. Progression to loss of light-perception occurs in most patients. Several reports identify VZV as a causative agent of PORN. Polymerase chain reaction (PCR) testing of specimens from vitreous aspirates has detected VZV DNA⁽⁸⁻¹⁰⁾. There is one report of HSV-1 in association with PORN in a patient with AIDS⁽¹¹⁾.

The differential diagnosis includes ARN, another form of NHR, also caused by VZV. ARN occurs in persons with and without AIDS. The American Uveitis Society proposed standard diagnostic criteria in 1994⁽¹²⁾. These include the following required clinical observations: focal, well-demarcated retinal necrotic areas in the periphery beyond the major temporal vascular arcades; rapid, circumferential coalescence and progression of necrosis when not treated with antiviral therapy; evidence of occlusive vasculopathy; and prominent anterior chamber and vitreal inflammatory reaction. Other clinical findings that may support diagnosis but are not required include optic atrophy, scleritis, and pain⁽⁵⁾.

The initial diagnostic consideration in our case was immune reconstitution uveitis and retinitis because of recent resumption of antiretroviral therapy, higher level of CD4⁺ T-cell count, and fundoscopic findings of chorioretinitis in the absence with a possible inflammatory response in the left eye. However, after 5 days of prednisolone the chorioretinitis worsened. The lesion was diagnosed as PORN on the basis of the clinical appearance and its aggressive progression pattern. Compared to ARN and CMV retinitis, the diagnosis of PORN in our case was supported by the following findings; absence of intraocular inflammation, vasculitis and rapid deterioration involving the macular area in without evidence of CMV infection. Two distinct features confirm the likelihood that PORN was the correct diagnosis, namely the presence of an immune deficiency state with retinal hemorrhage

in her left eye that was initially misinterpreted as uveitis; and the right eye that demonstrated classical outer retinal level hemorrhage which later spread over the posterior pole as limited subretinal hemorrhage rapidly progressing over four weeks. Importantly, there was no sign of retinal tear or detachment.

The CD4⁺ T-cell counts observed in this case at the onset of re-initiation of HAART and the diagnosis of PORN (127 cells/ μ L, and 167 cells/ μ L, respectively) were relatively higher than those of previously reported cases. In addition, the HIV viral load was also undetectable a few months later. Previous case series demonstrated that the CD4⁺ T-cell counts of patients diagnosed with PORN were lower (20-50 cells/ μ L)^(3,4,9,11). There have been two recent case reports of PORN with CD4⁺ T-cell counts higher than previously found (380 cells/ μ L, and 230 cells/ μ L). In both cases, PORN occurred during a period of rapid HAART induced immune recovery^(13,14). Thus, it is possible that PORN is a retinal manifestation of IRIS. Physicians should be aware of this illness in HIV-infected persons initiating HAART who develop progressive visual disturbances.

Conclusion

The case demonstrates an atypical clinical presentation of PORN after initiation of HAART in an AIDS patient with CD4⁺ T-cell count >100 cells/ μ L. PORN should be included in the differential diagnosis of reduced visual acuity in AIDS patients responding to HAART. The diagnosis is based upon clinical examination. The differential diagnosis includes ARN, CMV or HSV retinitis. Tissue samples are useful in determining the etiology of PORN. Prompt initiation of specific antiviral therapy may preserve vision in eyes with PORN though the prognosis is generally poor.

Acknowledgement

We thank Dr. Carl J Fichtenbaum for reviewing and giving advice for our paper.

References

1. Cunningham ET Jr, Margolis TP. Ocular manifestations of HIV infection. *N Engl J Med* 1998; 339: 236-44.
2. Forster DJ, Dugel PU, Frangieh GT, Liggett PE, Rao NA. Rapidly progressive outer retinal necrosis in the acquired immunodeficiency syndrome. *Am J Ophthalmol* 1990; 110: 341-8.
3. Austin RB. Progressive outer retinal necrosis syndrome: a comprehensive review of its clinical presentation, relationship to immune system status, and management. *Clin Eye Vis Care* 2000; 12: 119-29.
4. Moorthy RS, Weinberg DV, Teich SA, Berger BB, Minturn JT, Kumar S, et al. Management of varicella zoster virus retinitis in AIDS. *Br J Ophthalmol* 1997; 81: 189-94.
5. Carrillo-Pacheco S, Vazquez-Marouschek MC, Lopez-Checa F, Sanchez-Roman J. Progressive outer retinal necrosis in an immunocompetent patient. *Acta Ophthalmol Scand* 1996; 74: 506-8.
6. Benz MS, Glaser JS, Davis JL. Progressive outer retinal necrosis in immunocompetent patients treated initially for optic neuropathy with systemic corticosteroids. *Am J Ophthalmol* 2003; 135: 551-3.
7. Nakamoto BK, Dorotheo EU, Biousse V, Tang RA, Schiffman JS, Newman NJ. Progressive outer retinal necrosis presenting with isolated optic neuropathy. *Neurology* 2004; 63: 2423-5.
8. Pavesio CE, Mitchell SM, Barton K, Schwartz SD, Towler HM, Lightman S. Progressive outer retinal necrosis (PORN) in AIDS patients: a different appearance of varicella-zoster retinitis. *Eye* 1995; 9(Pt 3): 271-6.
9. Yin PD, Kurup SK, Fischer SH, Rhee HH, Byrnes GA, Levy-Clarke GA, et al. Progressive outer retinal necrosis in the era of highly active antiretroviral therapy: successful management with intravitreal injections and monitoring with quantitative PCR. *J Clin Virol* 2007; 38: 254-9.
10. Knox CM, Chandler D, Short GA, Margolis TP. Polymerase chain reaction-based assays of vitreous samples for the diagnosis of viral retinitis. Use in diagnostic dilemmas. *Ophthalmology* 1998; 105: 37-44.
11. Kashiwase M, Sata T, Yamauchi Y, Minoda H, Usui N, Iwasaki T, et al. Progressive outer retinal necrosis caused by herpes simplex virus type 1 in a patient with acquired immunodeficiency syndrome. *Ophthalmology* 2000; 107: 790-4.
12. Holland GN. Standard diagnostic criteria for the acute retinal necrosis syndrome. Executive Committee of the American Uveitis Society. *Am J Ophthalmol* 1994; 117: 663-7.
13. Woo SJ, Yu HG, Chung H. A case of atypical progressive outer retinal necrosis after highly active antiretroviral therapy. *Korean J Ophthalmol* 2004; 18: 65-9.
14. Ramsay A, Young S, Lightman S. Failure of antiretroviral therapy to control Varicella zoster retinitis. *Clin Experiment Ophthalmol* 2001; 29: 433-4.

การแสดงออกที่ผิดปกติของ progressive outer retinal necrosis (PORN) ในผู้ป่วยเอดส์ที่มี CD4⁺ T-cell counts มากกว่า 100 cell/ μ L ในขณะที่ได้รับยาต้านไวรัสเอชไอวีความแรงสูง

พรพัฒนะ วิจิตรเวชไพศาล, สมพร ธีพัฒน์, วรพจน์ ตันติศิริวัฒน์

Progressive outer retinal necrosis (PORN) เป็นโรคติดเชื้อทางตาที่รุนแรง มักพบในผู้ป่วยเอดส์ที่มีค่า CD4⁺ T-cell counts ต่ำมาก สาเหตุจากการติดเชื้อ Varicella-zoster virus (VZV) ซึ่งจะพบการดำเนินโรคที่รวดเร็ว และมักนำไปสู่ภาวะตาบอดได้ภายในระยะเวลาไม่นาน ปัจจุบันความสำเร็จในการพยายามรักษายังถูกจำกัด ผู้เขียนได้รายงานผู้ป่วยที่มาด้วย PORN ทั้งสองตาในผู้ป่วยเอดส์ซึ่งมีค่า CD4⁺ T-cell counts มากกว่า 100 cell/ μ L แม้ขณะได้รับยาต้านไวรัสเอชไอวีความแรงสูง (HAART) โดยผู้ป่วยหญิงไทยอายุ 29 ปี ทราบว่า ตนเองติดเชื้อเอชไอวีเมื่อปี พ.ศ. 2541 มาด้วยเรื่องตามัวทั้งสองตาลงหลังจากได้รับยาต้านไวรัสเอชไอวีความแรงสูงไปสองเดือน ตรวจพบพยาธิสภาพหลายจุดในชั้นจอประสาทตา โดยไม่พบการอักเสบในลูกตา โดยในขณะนั้นผู้ป่วยมีค่า CD4⁺ T-cell counts 127 cell/ μ L ได้รับการวินิจฉัย PORN จากพยาธิสภาพที่ตรวจพบและพบ VZV ในน้ำลูกตาและวุ้นตา ซึ่งตรวจโดย PCR โดยได้ให้การรักษาทั้ง acyclovir ฉีดเข้าทางหลอดเลือดดำและ ganciclovir ฉีดเข้าทางลูกตา สุดท้ายผู้ป่วยสูญเสียการมองเห็นทั้งสองตา จากรายงานผู้ป่วยนี้ควรนึกถึง PORN ในผู้ป่วยเอดส์ที่มาด้วยเรื่องตามัว แม้ว่าผู้ป่วยนั้นจะได้รับยาต้านเชื้อไวรัสเอชไอวีความแรงสูงและพบ CD4⁺ T-cell counts ที่มีค่าสูง โดย PORN อาจจะเป็นอาการแสดงของ immune reconstitution syndrome ได้
