

Normal Radiographic Values of the Forefoot in the Thai Women Population

Suriyapong Saowaprut MD*,
Anuchart Lalitwongchai MD*, Sasipong Rohitopakarn MD*

**Arthroscopic and Sports Medicine Unit, Institute of Orthopaedics, Lerdsin Hospital, Bangkok, Thailand*

Background: Diseases of the forefeet are common problems in orthopedics. Evaluation of forefoot radiography has played an important role to determine the forefoot deformity. Previous studies have shown that normal radiographic values of the western population were different from the Asian population values.

Objective: To examine the normal range of radiologic values of forefoot in Thai women

Material and method: The data collected at out-patient division of the hospital for screening 100 women (200 feet). All patients have been radiographed in the AP standing position (to measure the HVA, 1st IMA, DMAA, sesamoid AP and 1st metatarsal length) and weight bearing tangential view to determine the SRA angle.

Results: The average results of the right and the left foot HVA = 10.75 degrees, 9.39 degrees/1st IMA = 10.24 degrees, 9.20 degrees/DMAA = 3.72 degrees, 3.32 degrees/sesamoid AP grade 0 -1 = 85 percent, 82 percent/SRA = 9.14 degrees, 8 degrees respectively, 1st metatarsal length was shorter than the 2nd metatarsal length in most cases (70%) and when comparing between the right and the left foot, no statistical significant difference were found ($p > 0.05$).

Conclusion: Study found that the values of HVA, DMAA and the 1st metatarsal length in Thai women were less than the values found in the foreign literatures but it was similar to the Asian population figures.

Keywords: Forefoot radiography, Forefoot radiography in Thai women, Hallux valgus

J Med Assoc Thai 2009; 92 (Suppl 6): S251-7

Full text. e-Journal: <http://www.mat.or.th/journal>

Diseases of the forefeet are common problems in orthopedics. Evaluation of forefoot radiography has played an important role to determine the forefoot deformity. Previous studies have shown that normal radiographic values of the western population were different from the Asian population values⁽¹⁻⁸⁾. Normal radiographic values of European and American people were 13-28 degrees for HVA while the values observed in Asian were 8-13 degrees for HVA⁽¹⁻⁸⁾. This might be due to the variation of the bony structures and the other related factors such as activities, occupation, styles of shoes wearing.

Up to date, there was only one study of the normal values of forefoot radiograph in Thai

people⁽⁷⁾. However, it included both women and men aged over 40 years in which the measurement accuracy might be confounded by the aged-related osteoarthritic change of the metatarsophalangeal joint or tarsometatarsal joint⁽¹⁴⁾. The objective of this study was to examine the normal range of radiologic values of forefoot in Thai adult women the dominant gender diagnosed with Hallux Valgus.

To obtain the clinical meaningful data related to this disease in addition to what have already reported in previous local research, we included women aged under 40 years and measure the relevant angular parameter of foot which some of them were rarely reported in previous studies including HVA (hallux valgus angle), 1st IMA (first intermetatarsal angle), DMAA (distal metatarsal articular angle), Sesamoid AP (sesamoid anteroposterior), SRA (sesamoid rotation angle), and 1st metatarsal length.

Correspondence to: Suriyapong Saowaprut, Arthroscopic and Sports Medicine Unit, Institute of Orthopaedics, Lerdsin Hospital 190 Silom Road, Bangkok 10500, Thailand. Phone: 0-2353-9844, Fax: 0-2353-9845. E-mail: lerdsin@hotmail.com

Material and Method

Study design and patients

We prospectively collected data in 100 Thai women who visited at an out-patient department, Lerdsin hospital during January 2007-January 2008. Patients aged between 20-40 years and had no any deformity or feet diseases were included in the analysis. All radiographs were obtained from weight bearing AP and weight bearing tangential view. We obtained the approval from the hospital committee. Only patients who signed the consent form were included in the study.

Radiological imaging

Weight bearing AP

Cassette was placed on plantar surface of foot. Patient stood on cassette in plantegrade foot position in which the distance between cassette and x-ray source were 40 inches and the angle was 15 degree to cephalad centered on base of the third metatarsal.

Weight bearing Tangential

By using tangential position device (Fig. 1), the long axis of foot was parallel to the block. By standing in full knee extension and full extend of interphalangeal joint. Cassette is placed distal to the block. Distance between cassette and x-ray source is 40 inches. X-ray beam are parallel to the floor from posterior to the anterior centered between both foot (Fig. 2).

Angular parameter measurements

Weight bearing AP

HVA Angle between long axis of first metatarsal bone and proximal phalange of first toe was measured by making three dots in a diaphyseal area 1 cm from joint line on both side of the joint and drawing a straight line connecting all center dots together (Fig 3,A).

1st IMA

An angle between long axis of first and second metatarsal bone was measured (Fig 3,B).

DMAA

An angle between long axis of first metatarsal and distal metaphyseal line (line drawn from medial edge of joint surface to the lateral edge) (Fig. 3,90°C).

Length of the first metatarsal (Fig. 4)

1) The differences of length between first and second metatarsal was measured. We drew a



Fig. 1 Weight bearing tangential device (240 mm x 270 mm x 40 mm)

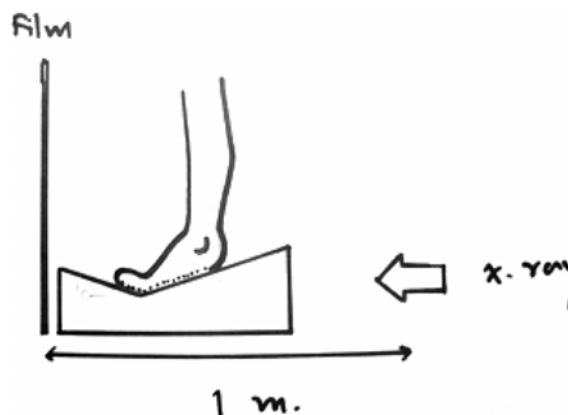


Fig. 2 Foot position and direction of radiographic beam

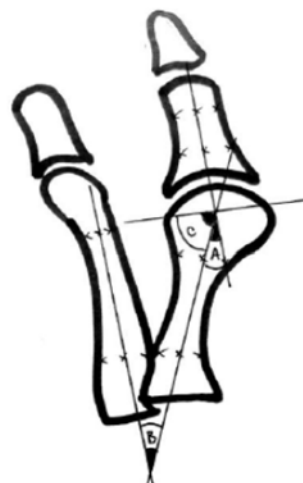


Fig 3 HVA, 1st IMA and DMAA measurement

transverse line from the outermost of calcaneocuboid joint to innermost of talonavicular joint and then the longitudinal axis of the second toe was drafted to connecting with the first line.

2) A curve line using intersection point as a center of a circle was drafted passing by the distal articular surface of the first and second metatarsal. The distance between these two lines was measured as shown in Fig. 6 and recorded in the following values;

- Negative values when the first metatarsal is shorter than second metatarsal
- Positive values when the first metatarsal is longer than second metatarsal

We allowed the measurement error to be 1 mm then if the recorded differences were 1 or -1, it was interpreted as there was no difference.

Sesamoid AP view

Position of tibial Sesamoid compare with long axis of first metatarsal (Fig. 5) were reported in the following grading levels;

Grade 0: position medial to long axis without overlapping

Grade 1: less than 50% overlapping

Grade 2: more than 50% overlapping

Grade 3: position lateral to long axis without overlapping

Sesamoid rotation angle (SRA) from weight bearing tangential view

Angle between sesamoid tangential line and line parallel to the floor was measured. Tangential line is a line connecting between the bottommost of tibial and fibular sesamoid (Fig. 6).

To assure the reliability of these measurements, the separately repeated means.

Statistical analysis

The matched pair *t*-test was used to compare the mean of radiologic values obtained from left and right feet in the same patient. Descriptive statistic (mean and standard deviation) was used to describe the angle measured. The reliability test was done by using the intraclass correlation coefficient based on inter-observer and intra-observer errors.

Results

The average age of the sample population was 32 years (22 to 39 years). The average weight was 55 kg and mean height was 160 cm.

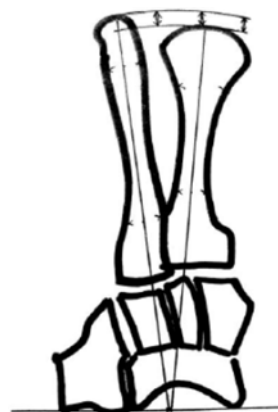

Fig. 4 Length of 1st metatarsal measurement

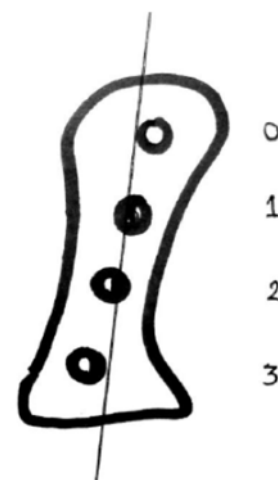


Fig. 5 Position of tibial sesamoid comparing to long axis of first metatarsal

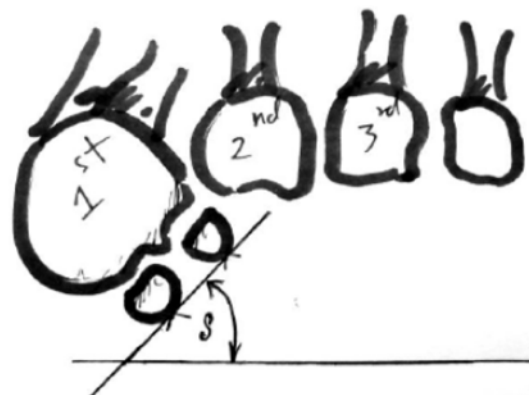


Fig. 6 Sesamoid rotation angle from weight bearing tangential view

There was no statistical difference of all radiographic parameters from AP view, including HVA, the first IMA, and DMAA between left and right foot (p-value = 0.0725, 0.062, 0.125) as shown in Table 1. From tangential view, we found no statistical difference of SRA between left and right side (p-value = 0.081).

Majority of positions of tibial sesamoid were in grade 0-1 (82% of right foot and 85% of left foot), as shown in Table 2.

Fig. 7 demonstrated the comparison of the length of first and second metatarsal bone. We found this length differs in total 200 cases, with a mean difference of (3.5 mm).

We found the good correlation of intra-observer (ICC ranging from 0.75-0.99) and inter-observer (ICC ranging from 0.66-0.95) resulting in the reliable measurements (Table 3).

Discussion

Finding the literature review was different values in the Europe and American studies. Values have some higher value than study in Asia. In addition, the majority of values in each study not complete and in some study are wide range data. The small number of sample was caused for this several reasons or incorrect in measurement method (Low ICC).

This study was a large series of 200 feet and consisted of Thai women 22-39 years old. It should represent normal values of mature Thai women. Weight bearing radiography was essential to evaluate the foot problems and the weight bearing tangential sesamoid view provides more and accurate information of sesamoid bone.

There was no statistical difference between Right side and Left side in all parameters. It can be used interchangeably. The angular measurements were useful and can be used as normal values for Thai women. The values were similar to there found in Asian population^(7,8) but difference from European and American population^(1,2,4,6,11,12). This might be due to comparable bony structures, lifestyles and shoe wearing^(8,14). This assumption should be further explored.

In Thailand's data which is quite complete but cannot represent normal parameters in Thai women because it includes wide range in age (19-77 years) and also include male population. Two hundred images are included in this study also using two new techniques in measuring weight bearing tangential view which decrease errors measuring from AP view.

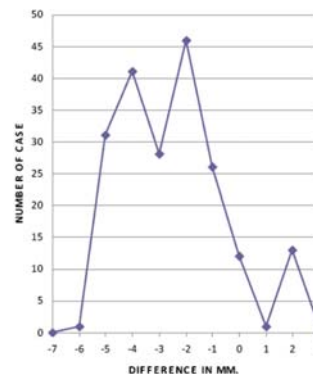


Fig. 7 Comparison of length of the first and second metatarsal bone (expressed the differences in mm)

Table 1. Radiographic parameters from AP view and tangential view

Variables		Max	Min	Mean	SD	t-test
HVA	Rt.	30	0	9.39	6.83	p > 0.05
	Lt.	34	0	10.75	6.56	
1 st IMA	Rt.	18	5	10.24	3.93	p > 0.05
	Lt.	18	3	9.20	2.69	
DMAA	Rt.	13	20	3.72	4.46	p > 0.05
	Lt.	-10	-4	3.32	5.67	
SRA*	Rt.	25	0	9.14	5.66	p > 0.05
	Lt.	22	0	8	4.96	

Table 2. Grading of positions of tibial sesamoid

Position	No.	
	Rt.	Lt.
Grade 0	16	20
Grade 1	69	62
Grade 2	11	14
Grade 3	4	4

Table 3. Intraobserver ICC and interobserver ICC

Variable	Intra observer ICC	Inter observer ICC
HVA	0.9922	0.9255
IMA (M ₁ M ₂)	0.9772	0.9191
DMAA	0.7531	0.6184
SAP	0.9419	0.9520
SRA	0.8930	0.6653
M ₁ Length	0.7754	0.6998

This literature is the first which study in Thailand female population age from 22-39 years which deformity often occurs.

Regarding the Hallux Valgus Angle, Hardy and Clapham (1951) reported of HVA = 16 degree (0-32), Scott GR (1980) HVA = 13 degree (2-25), Fuhrman (1977) HVA = 20 degree (0-32). Tanaka (1997) reported result in Japanese population HVA = 10 degree. The study of Kamolporn (2000) report normal angle = 11 degree (0-26). This study showed that HVA = 10 degree (0-23) which imply that if HVA of 23 degree or more should be considered an abnormal value. However, some of hallux valgus patient do have HVA less than 23 degree the diagnosis of Hallux valgus should be clinical correlation.

It is interesting that angular parameter in this study are similar to the study in Japan by Tanaka⁽¹⁹⁹⁷⁾ and study in Thailand by Kamolporn⁽²⁰⁰⁰⁾ which can be explain by bony structure and lifestyle (such as shoe wear and occupation). Further study should be conduct.

We found our study results were similar to values reported by Tanaka and Kamolporn. This might be due to comparable bony structure and lifestyles of patients *i.e.* shoe wearing, occupation, however, this assumption should be further explored.

1st IMA was the first intermetatarsal angle, it represent the way to evaluate the amount of metatarsus primus varus associated with hallux valgus. Most reports defined a normal angle at less than 10^(1,2,3,4,6,7). The absolute value has been used to determine appropriated correction of hallux valgus. This study reported an average of 9.72 that closed to the others studies.

DMAA angle correlated with HVA. From literature reviews, there is wide variation of DMAA^(1,2,3,4,6,7) (normal = 5-10 degrees). It may also be the error of methods of measurement and method to determine articular reference line. (ICC = 0.6184). Mean DMAA of this study is 3.52 degree which is less than the other studies. DMAA also is a useful parameter for selecting extraarticular correction technique such as double osteotomy. The less values of DMAA in Thai women in this study, the double osteotomy technique for correct HV deformity should not be considered.

Evaluation of sesamoid bone can be done from both AP and tangential view. The first technique recommended by the American Foot and Ankle Society (4 grade 0-3) was used with popularity because of its convenience. However, it does not demonstrate

the metatarsosesamoid joint^(8,13) and the value may be misinterpreted from the rotation of the first metatarsal. The second technique, SRA measurement, is more accurate and is able to measure both the tibial and fibular sesamoids. This is closely correlated with the hallux valgus deformity and this technique is now getting more popularity but it still lack of the supporting data in the Thai population. Therefore, our study has been the first study of SRA measurement in Thai women.

Mostly the position of sesamoid bone was grade 0-1 (80-90%). In our study, it was 85% in the right foot and 82% in the left foot. SRA were 9 degrees in the right and 8 degrees in the left which were similar to the study of Kuwano⁽¹⁹⁷⁷⁾ of 7.4 degrees. Hence, we recommend both the SRA and the sesamoid AP angle for high HVA or severe deformity of the forefeet.

The data from our study can be applied in the clinical use, such as surgery in hallux valgus which emphasize the position of sesamoid in grade 0-1 and pay more attention to the position of metatarsosesamoid joint and SRA (should not be exceed 8.57 degrees).

Length of the first metatarsal is now debated about the correlation between length of metatarsal and hallux valgus⁽¹⁾ The shorten first metatarsal can alter forefoot biomechanics⁽¹²⁾. Technique of Hardy and Clapham is quite accurate because it is not affected by variation of IMA⁽¹⁾ Harris et al⁽¹²⁾ run a study in 7,167 feet which the length are quite equal (-12 to 10 mm).

From our study the mean value was -3.5 mm (-2 to -5 mm) in 70%. This result has shown that less different in length and most of the first metatarsals were shortened than the second metatarsal. For clinical application, ratio between first and second metatarsals should be used and emphasized not to shorten the first metatarsal or it may alter the foot mechanics.

From this study, we report high ICC (0.6184-0.9922) and found that the intraobserver ICC are greater than the interobserver ICC, especially the DMAA and the SRA.

Limitation of this study are the small samples size, some angles were not included (*e.g.* PAA, other IMA's). This study is preliminary, which require further investigation to complete the angular parameters and would truly represent the Thai women population.

Conclusion

Our study demonstrated the radiologic values of the forefoot in the Thai women but the data

could not represent the true values since the sample size was small. Larger sample size would be needed in the further studies and more descriptive information would be required such as occupation, lifestyles and shoes wearing in order to correlate with the foot problems (*e.g.* hallux valgus).

We found that the HVA, the DMAA and the first metatarsal length in this study are less values than other studies (USA and Europe) but closely to the Asian figures which may be explained by the difference in the anatomical structure (bone and soft tissue) or the foot sizes.

The result of this study can be applied in the clinical practices to help surgeons choosing the right surgical procedures in correcting forefoot angles for Thai women.

References

- Hardy RH, Clapham JC. Observations on hallux valgus; based on a controlled series. *J Bone Joint Surg Br* 1951; 33-B: 376-91.
- Scott G, Wilson DW, Bentley G. Roentgenographic assessment in hallux valgus. *Clin Orthop Relat Res* 1991; (267): 143-7.
- Tanaka Y, Takakura Y, Takaoka T, Akiyama K, Fujii T, Tamai S. Radiographic analysis of hallux valgus in women on weightbearing and non-weightbearing. *Clin Orthop Relat Res* 1997; (336): 186-94.
- Fuhrmann RA, Layher F, Wetzel WD. Radiographic changes in forefoot geometry with weightbearing. *Foot Ankle Int* 2003; 24: 326-31.
- Pique-Vidal C, Maled-Garcia I, Arabi-Moreno J, Vila J. Radiographic angles in hallux valgus: differences between measurements made manually and with a computerized program. *Foot Ankle Int* 2006; 27: 175-80.
- Panchbhavi VK, Trevino S. Comparison between manual and computer-assisted measurements of hallux valgus parameters. *Foot Ankle Int* 2004; 25: 708-11.
- Kaewpornawan K, Tachapaitoon W. Normal values for the radiological measurement of the adult Thai foot and comparison with the values in common foot problems. *Siriraj Hosp Gas* 2000; 52: 393-400.
- Kuwano T, Nagamine R, Sakaki K, Urabe K, Iwamoto Y. New radiographic analysis of sesamoid rotation in hallux valgus: comparison with conventional evaluation methods. *Foot Ankle Int* 2002; 23: 811-7.
- Chi TD, Davitt J, Younger A, Holt S, Sangeorzan BJ. Intra- and inter-observer reliability of the distal metatarsal articular angle in adult hallux valgus. *Foot Ankle Int* 2002; 23: 722-6.
- Farber DC, Deorio JK, Steel MW III. Goniometric versus computerized angle measurement in assessing hallux valgus. *Foot Ankle Int* 2005; 26: 234-8.
- Saragas NP, Becker PJ. Comparative radiographic analysis of parameters in feet with and without hallux valgus. *Foot Ankle Int* 1995; 16: 139-43.
- Harris RI, Beath T. The short first metatarsal; its incidence and clinical significance. *J Bone Joint Surg Am* 1949; 31A: 553-65.
- Talbot KD, Saltzman CL. Assessing sesamoid subluxation: how good is the AP radiograph? *Foot Ankle Int* 1998; 19: 547-54.
- Cho NH, Kim S, Kwon DJ, Kim HA. The prevalence of hallux valgus and its association with foot pain and function in a rural Korean community. *J Bone Joint Surg Br* 2009; 91: 494-8.

ค่าปกติของภาพรังสีเท้าส่วนหน้าในผู้หญิงไทย

สุริยพงษ์ เสาวฤทธิ์, อนุชาติ ลลิตวงศ์ชัย, ศศิพงษ์ โรหิตไพบการ

ภูมิหลัง: ปัจจุบันโรคของเท้าส่วนหน้าเป็นปัญหาที่สำคัญในผู้ป่วยออร์โธปิดิกส์การประเมินค่าปกติของมุมต่าง ๆ ในเท้ามีความสำคัญ และข้อมูลค่าเฉลี่ยของประชากรหญิงเอเชียแตกต่างค่าเฉลี่ยของประชากรจากยุโรปและอเมริกา

วัตถุประสงค์: เพื่อศึกษาค่าเฉลี่ยมุมของเท้าในผู้หญิงไทย

วัสดุและวิธีการ: คณะผู้รายงานได้ทำการศึกษาเพื่อวัดค่าต่าง ๆ ของภาพรังสีเท้าส่วนหน้าปกติในผู้หญิงไทยอายุระหว่าง 22-39 ปี เฉลี่ย 32 ปี โดยทำการศึกษานับรวม 100 คน รวมเท้า 200 เท้า คัดเลือกผู้ป่วยที่ได้รับการตรวจที่แผนกผู้ป่วยนอกโรงพยาบาลเลิดสินทุกรายได้รับการถ่ายภาพรังสีเท้าในท่ายืนลงน้ำหนัก โดยหาค่ามุมดังนี้ HVA, 1st IMA, DMAA, Sesamoid AP และ 1st metatarsal Length และทำเส้นลงน้ำหนัก Tangential โดยหาค่ามุม SRA

ผลการศึกษา: ผลการศึกษาค่าเฉลี่ยในแต่ละค่าเรียงเท้าขวา และซ้ายตามลำดับเป็นดังนี้ค่า HVA เท้ากับ 10.75, 9.39 องศา ค่า 1st IMA เท้ากับ 10.24, 9.20 องศา ค่า DMAA เท้ากับ 3.72, 3.32 องศา ค่า Sesamoid AP เกรด 0-1 เท้ากับร้อยละ 85, 82 ค่า SRA เท้ากับ 9.14, 8 องศา และส่วนใหญ่ 1st metatarsal length สั้นกว่า 2nd metatarsal length (ร้อยละ 70) และเมื่อเปรียบเทียบเท้าขวาและซ้ายไม่พบความแตกต่างระหว่างกันอย่างมีนัยสำคัญทางสถิติ ($p > 0.05$)

สรุป: จากการศึกษาครั้งนี้พบว่าค่ามุม HVA, DMAA และ 1st metatarsal Length ของผู้หญิงไทยมีค่าน้อยกว่าค่าที่ได้ในการศึกษาในวรรณกรรมต่างประเทศ แต่มีความใกล้เคียงกับการศึกษาในคนไทย
