

# Clinical Outcomes of Minisubvastus Approach for Minimally Invasive Total Knee Arthroplasty

Samart Muangsiri MD\*,  
Sompob Ruxasagulwong MD\*, Jatupon Kongthawornskul MD\*,  
Viroj Larbpaiboonpong MD\*, Thana Turajane MD\*

\* Police General Hospital, Bangkok, Thailand

---

**Objective:** To examine the clinical outcome of minisubvastus approach, a true quadriceps-sparing approach for minimally invasive knee arthroplasty.

**Material and Method:** Between January 2005 and January 2008, 398 knees were included in this study. We evaluated the results of primary total knee arthroplasties performed with minisubvastus approach in patients at a minimum 1-year follow-up period. A retrospective review of the patient medical records was used.

**Results:** The mean wound length was 11 centimeters and mean blood loss was about 478 milliliters. An average total operative time was 112 minutes. The mean femorotibial angle was corrected from 8 degrees varus preoperatively to 4 degrees valgus postoperatively. Pain assessed by WOMAC score was much improved as the mean score decreased from 50.84 at preoperative to 26.81 at one-year postoperative period.

**Conclusion:** Minisubvastus arthroplasty is effective and can be performed in almost of knee deformities.

**KeywordS:** Minimally invasive, Minisubvastus, Total knee arthroplasty, Knee deformity

*J Med Assoc Thai* 2009; 92 (Suppl 6): S75-9

**Full text. e-Journal:** <http://www.mat.or.th/journal>

---

Since the Total Condylar knee was first implanted in 1973<sup>(1)</sup>, total knee arthroplasty (TKA) has been the standard treatment for severe arthritis of the knee. Historically, most of surgeons did midline 20-25 cm skin incision and medial parapatellar approach. Following minimally invasive surgery for unicompartmental knee arthroplasty by Repicci<sup>(2)</sup> in early 1990s, Tria and Coon<sup>(3)</sup> introduced minimal incision TKA in 2001. The minimal incision approach is less invasive, which minimizes soft tissue dissection, but can be converted to a standard approach if necessary. The concept of minimally invasive surgery includes patient selection, surgical technique, and implant design<sup>(3-9)</sup>. The patient should be of less severe deformity. Surgical techniques include reduced incision, non-everted patella, *in situ* bone cut, no joint dislocation, mobile skin window, downsized instrumentation and quadriceps-sparing approach. A number of surgical approaches for minimal incision surgery TKA have been proposed

such as minimidvastus, minisubvastus, and quadriceps-sparing.

Quadriceps-sparing approach is the minimally invasive TKA, in which the quadriceps muscle on the front of the thigh is not cut. Pagnano and colleagues reported the inferior edge of the vastus medialis obliquus inserted at or near the midpole of the patella<sup>(10)</sup>. Thus, in the quadriceps-sparing approach, the capsular incision should not be extended proximal more than the midpole of the patella. The subvastus approach and its modifications are the true quadriceps-sparing approaches.

The subvastus approach has been originally described in German literature by Erkes in 1929<sup>(11)</sup>. A modified version was re-introduced in English language by Hofmann in 1991<sup>(12)</sup>. A so-called "minisubvastus approach" was defined as short skin incision, short capsular incision and the vastus medialis obliquus muscle complete intact. The subvastus approach to the knee joint has been recommended as an alternative option to traditional approaches which involve a large arthrotomy with partial division of the quadriceps

---

Correspondence to: Muangsiri S, Police General Hospital, Bangkok 10330, Thailand. Phone: 0-2207-6000, E-mail: samartm@yahoo.com

mechanism. As reported in several studies, the subvastus approach offers the advantage of preserving the extensor mechanism<sup>(12-14)</sup>. In Police General Hospital, the subvastus approach for the TKA has performed since 2000 and changed to minisubvastus approach in 2004, due to the benefit in improved outcomes and widespread use of the minimally invasive surgery in recent years. Thus, the objective of this study was to evaluate the intraoperative and postoperative clinical outcome of these two techniques.

## Material and Method

The study was a retrospective patients' chart review at the Police General Hospital. Approval was obtained from the Institution Review Board. Patients with no neuromuscular disease that could be disturb their rehabilitation who underwent minisubvastus TKA between January 2005 and January 2008 and have follow-up data not less than 1 year were included in the analysis. Other inclusion criteria were related to details of minisubvastus TKA that had to follow the full Police General Hospital minisubvastus total knee replacement protocol in which performed at a single knee surgery in one admission. We excluded the revision TKA.

In total, there were 517 arthroplasties using minimally invasive techniques in 459 patients with using the mini-subvastus approach. According to the inclusion criteria, there were 398 arthroplasties that had complete medical records including radiographs. Demographic data of these patients were presented in Table 1. From these patients, the mean age of the patients was 69 years (59-79 years). Sixty of them were males and 338 were females. The mean BMI was 24.8 kg/m<sup>2</sup> (22.1-32.0). Primary osteoarthritis was found in majority of patients (387) and only 11 of them were diagnosed with rheumatoid arthritis.

The preoperative protocol included medical clearance by internist, discontinuity of anticoagulant and antiplatelet and participation in education program for TKA. Epidural spinal anesthetic technique was performed and tourniquet was used to control

bleeding in all cases. Minisubvastus was done by skin incision at medial to the patella by approximately 8 to 12 centimeters in length. Capsular incision was done along the border of the patella and vastus medialis obliquus muscle. The patella was laterally retracted and the muscle was bluntly dissected proximally in case of the difficult exposure. Bone cut could be done through a mobile window using small instruments. Fixed-bearing total knee implant was used in all knees. Multimodal postoperative pain control was used including local marcaine skin injection, oral pain killer, and epidural morphine. Gradual muscle exercise on ankle, leg and knee were practiced as tolerated. Discharge criteria included sufficient wound healing, minimal pain on walking independently with walking aid, and knee flexion to approximately 90 degrees. Preoperative, intraoperative, and postoperative data were evaluated.

The mean preoperative parameters, including hematocrit level and WOMAC (Western Ontario and McMaster Universities) scores, and theirs postoperative were compared with use of one-way ANOVA test. A p-value of less than 0.05 was considered significant. Analyzed were performed using SPSS for Windows statistical package (Version X; SPSS, Chicago, IL).

## Results

Table 2 showed the clinical assessment of key parameters in studied patients. There was no significant difference in hematocrit level between preoperative and postoperative TKA (preoperative Hct = 35.39% vs. postoperative Hct = 31.08%; p = 0.105). The mean tourniquet time was 92 minutes. The average of operating time was 112 minutes. Mean blood loss collected in the drain was 478 ml. The mean visual analogue scale (VAS) of pain on the first postoperative day was 6.45. Mean length of stay was 6 days. An average preoperative femorotibial and postoperative femorotibial angle was 8 degrees varus and 4 degrees valgus respectively. The mean tibial varus angle was

**Table 1.** Demographic data (left:right, 198:200) (mean  $\pm$  standard deviation)

Sex	Male (n = 60)*	Female (n = 338)*	Total (n = 398)*
Age	68.8 $\pm$ 6.3 (61,78)	68.9 $\pm$ 5.7 (59, 79)	68.9 $\pm$ 5.8 (59, 79)
BMI	25.7 $\pm$ 5.9 (23.4-32.0)	24.8 $\pm$ 7.9 (22.1, 30.1)	24.8 $\pm$ 4.1 (22.1, 32.0)

\* The values are given as the number of patients

**Table 2.** Clinical assessment of minisubvastus TKA

Parameter	Mean	SD	Min	Max	p-value*
Hct pre-op	35.39	2.24	31	45	0.105
Hct post-op	31.08	2.59	26	38	0.105
Blood loss (mL)	478.10	66.82	350	870	
Tourniquet time (min)	92	0.08	81	112	
Op time (min)	112	0.10	108	127	
Length of stay (day)	6	0.75	4	10	
Incision length (cm)	11.13	1.37	8	14	
Flexion at 1 year (degree)	129.6	10.8	90	138	

Hct pre-op = preoperative hematocrit, Hct post-op = post-operative hematocrit, Op time = total operative time

\* Statistically significant ( $p < 0.05$ )

**Table 3.** WOMAC score

Time	Mean	SD	Min	Max
Pre-op	50.84	1.06	34	68
Post-op 2 wks	43.21	1.21	20	63
Post-op 24 wks	29.76	0.93	15	46
Post-op 1 yr	26.81	0.8	14	43

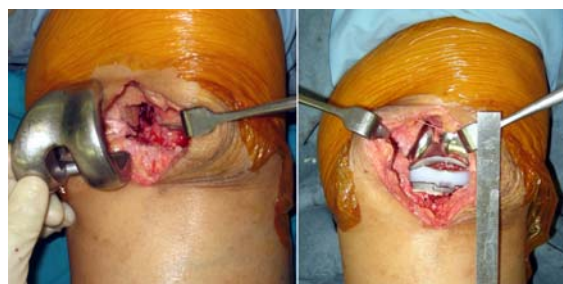
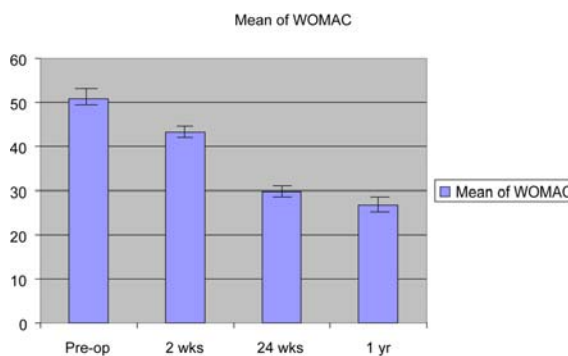
Pre-op = pre-operation, post-op = postoperative week

1.38 degrees. The ratio of non-outlier was 85 percent where 3 degrees was the upper limit. Mean knee flexion at one year at post-operation ranged from 100 to 129.6 degrees.

The WOMAC (Western Ontario and McMaster Universities) scores were evaluated at preoperative day, 2<sup>nd</sup> week, 24<sup>th</sup> week, and 1-year after operation. The mean WOMAC were 50.84, 43.21, 29.76 and 26.81 at these collecting data timepoints (Table 3). Comparison of mean preoperative and those of postoperative WOMAC score was shown in Fig. 2. The preoperative WOMAC score was significant greater than all WOMAC scores ( $p = 0.00001$ ) at post-operation. We found 3 cases with deep vein thrombosis and one case with deep infection, they were successfully treated with chemotherapy for deep vein thrombosis and with two-stage reimplantation for deep infection.

### Discussion

In Police General Hospital, the subvastus approach to the knee joint has been used since 2000 and changed to minisubvastus approach in 2004. According to the mobile window technique, new

**Fig. 1** Minisubvastus exposure (left) and completion of arthroplasty (right)**Fig. 2** Comparison of WOMAC score at pre-operative and post-operative period

smaller instruments, development of surgical technique, and the accumulation of more experience, we performed knee arthroplasty with the minisubvastus approach in all patients except in the revision of TKAs. Similarly to other surgical procedures, the patient selection is paramount to success and not all patients are clinically eligible for this approach. Obesity (weight > 200 lbs)

and revision surgery were contraindications for the minisubvastus approach due to limited exposure<sup>(12)</sup>. However, from our experiences, the indications can be expanded. Thus, we have also applied this approach to treatment of these patients, who have severe deformity and got previous knee surgery. In patients expected having difficult exposure during surgery, the extended skin incision and dissected proximal origin of the vastus medialis obliquus were done to gain wide exposure and to decrease muscle contusion during traction of the muscle laterally.

Many studies demonstrated significantly superior benefits of this approach in patients over traditional approaches. These included more rapid recovery time, better preservation of peripatellar vascularity. In addition, its advantages included the reduction of blood loss, postoperative pain, need for lateral release, quadriceps scar tissue formation, and length of hospitalization<sup>(12-15)</sup>. Still this technique has some drawbacks including limited exposure and injured vastus medialis muscle.

Considering the blood loss reported in this study, the average blood loss, 478 mL, should be less than any exposure due to no muscle incision. However, our result was comparable to a previous study in 136 consecutive minimally invasive TKAs which was 470 mL<sup>(16)</sup>. Bleeding may be due not only to the exposure technique, but also was related to the uncovered bony surface of the implant and medullary-drilled hole of the femur. Operation time gradually shortened in the past five years, but prolonged operation time was still observed in some cases due to large muscular mass of the thigh, severe deformity, and/or obesity of patients. The average wound length was 11 cm, but close to 8 cm in new arthroplasties. Average wound length was shorter in later cases. We expected that this is due to our learning experiences in previous cases. The cases with difficulty of persistently particular were of patella baja, particularly in previous knee surgery.

Regardless of prolonged hospitalization, all patients were able to walk with walking aids, flex and maintain the knee at more than 90 degrees, and then can be discharged on the fourth postoperative day. The mean femorotibial angle was corrected from 8 degrees varus preoperatively to 4 degrees valgus postoperatively and no early arthroplasties were revised from mechanical failure. The rate of complications found in the present study (3 cases), deep vein thrombosis (2 cases) and deep infection (1 case), was less than the range of general incidence after primary TKA (1-2%)<sup>(17,18)</sup>.

## Conclusion

The minisubvastus approach was found effective and safe. When surgeon was customized to the minisubvastus approach and used new smaller instrument, they were able to reduce the incision length, soft tissue stripping and improve functional result.

## Conflicts of interest

No financial support was received for this study. The authors have no conflicts of interest.

## References

1. Insall J, Ranawat CS, Scott WN, Walker P. Total condylar knee replacement: preliminary report. *Clin Orthop Relat Res* 1976; (120): 149-54.
2. Repicci JA, Eberle RW. Minimally invasive surgical technique for unicondylar knee arthroplasty. *J South Orthop Assoc* 1999; 8: 20-7.
3. Tria AJ Jr, Coon TM. Minimal incision total knee arthroplasty: early experience. *Clin Orthop Relat Res* 2003; (416): 185-90.
4. Laskin RS, Beksac B, Phongjunakorn A, Pittors K, Davis J, Shim JC, et al. Minimally invasive total knee replacement through a mini-midvastus incision: an outcome study. *Clin Orthop Relat Res* 2004; (428): 74-81.
5. Haas SB, Cook S, Beksac B. Minimally invasive total knee replacement through a mini midvastus approach: a comparative study. *Clin Orthop Relat Res* 2004; (428): 68-73.
6. Laskin RS. Minimally invasive total knee arthroplasty: the results justify its use. *Clin Orthop Relat Res* 2005; 440: 54-9.
7. Bonutti PM, Mont MA, McMahon M, Ragland PS, Kester M. Minimally invasive total knee arthroplasty. *J Bone Joint Surg Am* 2004; 86-A (Suppl 2): 26-32.
8. Boerger TO, Aglietti P, Mondanelli N, Sensi L. Mini-subvastus versus medial parapatellar approach in total knee arthroplasty. *Clin Orthop Relat Res* 2005; 440: 82-7.
9. Scuderi GR, Tenholder M, Capecci C. Surgical approaches in mini-incision total knee arthroplasty. *Clin Orthop Relat Res* 2004; (428): 61-7.
10. Pagnano MW, Meneghini RM, Trousdale RT. Anatomy of the extensor mechanism in reference to quadriceps-sparing TKA. *Clin Orthop Relat Res* 2006; 452: 102-5.
11. Erkes F. Weitere erfahrungen mit physiologischer schnitt führung zur eröffnung des kniegelenks. *Bruns Beitr Klin Chir* 1929; 147: 221.

12. Hofmann AA, Plaster RL, Murdock LE. Subvastus (Southern) approach for primary total knee arthroplasty. Clin Orthop Relat Res 1991; (269): 70-7.
13. Faure BT, Benjamin JB, Lindsey B, Volz RG, Schutte D. Comparison of the subvastus and paramedian surgical approaches in bilateral knee arthroplasty. J Arthroplasty 1993; 8: 511-6.
14. Bindelglass DF, Vince KG. Patellar tilt and subluxation following subvastus and parapatellar approach in total knee arthroplasty. Implication for surgical technique. J Arthroplasty 1996; 11: 507-11.
15. Matsueda M, Gustilo RB. Subvastus and medial parapatellar approaches in total knee arthroplasty. Clin Orthop Relat Res 2000; (371): 161-8.
16. Tanavalee A, Thiengwittayaporn S, Itiravivong P. Results of the 136 consecutive minimally invasive total knee arthroplasties. J Med Assoc Thai 2005; 88 (Suppl 4): S74-8.
17. Insall JN, Hood RW, Flawn LB, Sullivan DJ. The total condylar knee prosthesis in gonarthrosis. A five to nine-year follow-up of the first one hundred consecutive replacements. J Bone Joint Surg Am 1983; 65: 619-28.
18. Wilson MG, Kelley K, Thornhill TS. Infection as a complication of total knee-replacement arthroplasty. Risk factors and treatment in sixty-seven cases. J Bone Joint Surg Am 1990; 72: 878-83.

---

## ผลการรักษาทางคลินิกด้วยการผ่าตัดเปลี่ยนข้อเข่าเทียม แบบบาดเจ็บต่อน้อยเยื่อเล็กน้อยโดยวิธีไม่ตัดกล้ามเนื้อ

สามารถ ม่วงศิริ, สมพบ รักษาสกุลวงศ์, จตุพล คงถาวรสกุล, วิโรจน์ ลาภไพบุลย์พงศ์, ธนา ธุระเจน

**วัตถุประสงค์:** การผ่าตัดแบบบาดเจ็บต่อน้อยเยื่อเล็กน้อยได้รับความนิยมในปีที่ผ่านมา ผู้นิพนธ์จึงต้องการศึกษาผลการผ่าตัดรักษาเปลี่ยนข้อเข่าเทียมแบบบาดเจ็บต่อน้อยเยื่อเล็กน้อยด้วยวิธีไม่ตัดกล้ามเนื้อเลย

**วัสดุและวิธีการ:** ทำการศึกษาข้อเข่าของผู้ป่วยที่ได้รับการผ่าตัดระหว่างเดือนมกราคม พ.ศ. 2548 ถึงเดือนมกราคม พ.ศ. 2551 จำนวน 398 เข่า ซึ่งเป็นการผ่าตัดเปลี่ยนข้อเข่าเทียมครั้งแรกด้วยวิธีไม่ตัดกล้ามเนื้อเลย โดยผู้นิพนธ์ได้ทำการประเมินผลการผ่าตัดข้อเข่าของผู้ป่วยแบบย้อนหลังจากแบบบันทึกข้อมูลทางการแพทย์ของผู้ป่วย

**ผลการศึกษา:** จากการติดตามผลการรักษาอย่างน้อย 1 ปีพบว่าค่าเฉลี่ยความยาวแผลผ่าตัดอยู่ที่ 11 เซนติเมตร มีการเสียเลือดเฉลี่ยที่ 478 มิลลิลิตร เวลาโดยเฉลี่ยที่ใช้ในการผ่าตัดโดยเฉลี่ยอยู่ที่ 112 นาที สามารถแก้ไขขาโก่งเข้าในเฉลี่ยรวมกัน 8 องศา เป็นขาปกติเอียงออกนอกเฉลี่ยรวมกัน 4 องศา คะแนน WOMAC มีค่าเฉลี่ยก่อนผ่าตัดเท่ากับ 50.84 ซึ่งมีการเปลี่ยนแปลงที่ดีขึ้นหลังการผ่าตัดไปแล้ว 1 ปี โดยมีคะแนนเท่ากับ 26.81

**สรุป:** การผ่าตัดรักษาเปลี่ยนข้อเข่าเทียมแบบไม่ตัดกล้ามเนื้อมีประสิทธิภาพในการรักษา และสามารถใช้ผ่าตัดข้อเข่าเสื่อมได้เกือบทุกข้อเข่า โดยมีได้จำกัดเฉพาะข้อเข่าที่มีความเสื่อมเพียงเล็กน้อยเท่านั้น

---