

## Transcutaneous Esophageal Ultrasonography in Children with Suspected Gastroesophageal Reflux Disease

Busara Charoenwat MD<sup>1</sup>, Palittiya Sintusek MD<sup>1</sup>,  
Nataruks Chaijitraruch MD<sup>1</sup>, Atchara Mahayosnond MD<sup>2</sup>,  
Sukuma Suksri RN<sup>3</sup>, Tanisa Patcharatrakul MD<sup>3</sup>, Voranush Chongsrisawat MD<sup>1,3</sup>

<sup>1</sup> Division of Gastroenterology and Hepatology, Department of Pediatrics, Faculty of Medicine, Chulalongkorn University, Bangkok, Thailand

<sup>2</sup> Division of Diagnostic Radiology, Department of Radiology, Faculty of Medicine, Chulalongkorn University, Bangkok, Thailand

<sup>3</sup> Center of Excellence for Neurogastroenterology and Motility, Department of Medicine, Faculty of Medicine, Chulalongkorn University, Bangkok, Thailand

**Objective:** To evaluate the esophageal morphological parameters and occurrence of refluxate using transcutaneous esophageal ultrasonography [US] in children with suspected gastroesophageal reflux disease [GERD].

**Materials and Methods:** Twenty-two children with suspected GERD and 23 healthy controls were enrolled during November 2015 to January 2017. GERD was defined as reflux index and/ or liquid refluxate evaluated by multichannel intraluminal impedance-pH (MII-pH) monitoring greater than the 95<sup>th</sup> percentile of age-specific values. All subjects underwent transcutaneous esophageal US to assess the occurrence of refluxate and the esophageal morphology.

**Results:** Median age of patients (50% male) and controls (57% male) were 1.6 years (interquartile range 0.6 to 5 years) and 1.7 years (interquartile range 0.5 to 7.5 years), respectively. GERD symptoms were divided into esophageal (n = 11) and extraesophageal (n = 11) manifestations. Occurrence of refluxate and esophageal morphological parameters detected by transcutaneous esophageal US were not different between study and control groups. However, study group tended to have shorter abdominal esophageal length compared with controls (16.8±4.3 mm vs. 18.2±6.5 mm). Study group with GERD confirmed by MII-pH monitoring (n = 6) tended to have higher cervical/ abdominal esophageal wall thickness and diameter, and degree of gastroesophageal angle than those with normal MII-pH monitoring (n = 16), however the differences were not statistically significant. The number of occurrence of refluxate identified by transesophageal US was not significantly different between study group with and without abnormal refluxate detected by MII-pH monitoring.

**Conclusion:** The number of occurrence of refluxate and esophageal morphology evaluated by transcutaneous esophageal US do not correlate well with the MII-pH monitoring results.

**Keywords:** Children, Combined multichannel intraluminal impedance-pH monitoring, Gastroesophageal reflux disease, Transcutaneous esophageal ultrasonography

**J Med Assoc Thai 2018; 101 [Suppl. 4]: S1-S7**

**Full text. e-Journal:** <http://www.jmatonline.com>

Gastroesophageal reflux [GER] is the physiologic passage of gastric contents into the

esophagus, which commonly occurs in 50 to 70% of infants during the first 3 to 6 months of life and decreases inversely with age<sup>(1)</sup>. However gastroesophageal reflux disease [GERD] is the abnormal reflux causing troublesome symptoms or complications. Due to the heterogeneous manifestations, children with suspected GERD need further evaluation to confirm the diagnosis before

**Correspondence to:**

Chongsrisawat V, Division of Gastroenterology and Hepatology, Department of Pediatrics, Faculty of Medicine, Chulalongkorn University, Bangkok 10330, Thailand.

**Phone:** +66-2-2564951, **Fax:** +66-2-2564911

**E-mail:** voranush.c@chula.ac.th

**How to cite this article:** Charoenwat B, Sintusek P, Chaijitraruch N, Mahayosnond A, Suksri S, Patcharatrakul T, Chongsrisawat V. Transcutaneous esophageal ultrasonography in children with suspected gastroesophageal reflux disease. J Med Assoc Thai 2018;101;Suppl.4:S1-S7.

initiating treatment<sup>(2)</sup>.

Combined multichannel intraluminal impedance-pH [MII-pH] monitoring is considered the best investigation for the diagnosis of GERD by measuring electrical potential differences and pH of the reflux. However, MII-pH monitoring is an invasive, time-consuming, costly study and not widely available. Transcutaneous esophageal ultrasonography [US] is a non-invasive, readily available, and repetitive method for the diagnosis of GERD. It not only detects the visualized refluxate, but also the morphology of the esophagus and gastroesophageal junction<sup>(3-6)</sup>. There has been no study correlating the findings of transcutaneous esophageal US with those evaluated by MII-pH monitoring.

This was the first study to assess the result of MII-pH monitoring in comparison with transcutaneous esophageal US in children with suspected GERD. The primary objective of this study was to evaluate the esophageal morphological parameters and occurrence of refluxate using transcutaneous esophageal US in children with suspected GERD. The secondary purpose was to compare the esophageal morphological parameters using transcutaneous esophageal US in children with abnormal and normal MII-pH monitoring results.

## Materials and Methods

This study was conducted at King Chulalongkorn Memorial Hospital between November 2015 and January 2017. The participants were divided into 2 groups: Group 1 (study group) included 22 children who were less than 18 years old, had clinical suspected GERD and had no history of anatomical abnormalities of the gastrointestinal tract or previous esophageal surgery. The participants were further categorized into either GERD (n = 6) or non-GERD (n = 16) depending on the results of MII-pH monitoring. Group 2 (control group) comprised of 23 healthy controls under 18 years of age without clinical suspected GERD.

All subjects underwent transcutaneous esophageal US while only the participants in the study group underwent both MII-pH monitoring and transcutaneous esophageal US.

This cross-sectional analytic study was approved by the Ethical Committee of the Faculty of Medicine, Chulalongkorn University and informed consents were obtained from participants' guardians. The US and MII-pH monitoring were performed at the same hospital admission or within 14 days<sup>(6)</sup>.

## Transcutaneous esophageal US

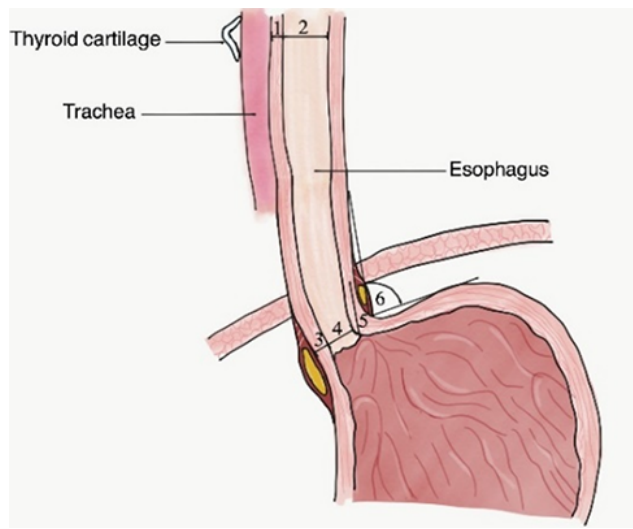
The procedure was performed by only one pediatric radiologist (AM) using 2 to 9 MHz curved transducers<sup>(7)</sup> for the abdominal part and 6 to 15 MHz linear transducers<sup>(3,8)</sup> for the cervical part (Logic E9, GE, Medical Systems Ultrasound and Primary Care Diagnostics United State of America). The US was performed within 30 minutes after a regular milk meal<sup>(5,9)</sup>. The radiologist used toys to calm down the children. The measurement was performed when children relaxed and were placed in a supine position with the head elevated approximately 30 degrees<sup>(7,9,10)</sup>.

The measured parameters included (1) cervical esophageal diameter and thickness, (2) abdominal esophageal diameter, thickness, and length, (3) angle of His<sup>(3,7,9)</sup> and (4) the occurrence of liquid refluxes above lower esophageal sphincter during 15 minutes of observation<sup>(3,5,7,9,10)</sup> as shown in Figure 1.

For evaluating the cervical esophagus, the linear transducer was placed left lateral to the thyroid cartilage in the transverse orientation with the children turning head 45 degrees to the right and slight neck flexing. By using thyroid gland as an acoustic window, the thickness of the esophagus was measured by using the distance between the adventitia and the mucosal layer (outermost to innermost hyperechoic layer) in millimeters and its inner diameter was measured by using the distance between mucosal surfaces (hyperechoic layer) in millimeters.

For evaluating abdominal esophageal length, the transducer was placed longitudinally at the midline just below the xiphisternum with the transducer tilted approximately 45 degrees upwardly. The length was measured in millimeters from the diaphragm to the base of the triangular pad of gastric folds at the anterior surface of the gastric fundus. For evaluating abdominal esophageal diameter and thickness, the transducer was placed at the midline just below the xiphisternum with the transducer in the transverse orientation. The esophageal diameter is defined as the distance between both mucosal surfaces (hyperechoic mucosal layer) in the non-peristaltic phase, and its thickness is defined as the distance between the adventitia and mucosal layer of the esophagus (outermost to innermost hyperechoic layer).

For evaluating angle of His, the transducer was placed longitudinally just below xiphisternum with tilting approximately 45 degrees upwardly. This angle formed by the tangent line passing from the gastric fundus to the long axis of the abdominal esophagus. It was categorized to 3 groups; completely obtuse (130



1. Cervical esophageal thickness
2. Cervical esophageal diameter
3. Abdominal esophageal thickness
4. Abdominal esophageal diameter
5. Abdominal esophageal length
6. Angle of His

**Figure 1** Landmarks of all parameters measured by transcutaneous esophageal ultrasonography.

to 180 degrees), obtuse (100 to 130 degrees) and right angle (70 to 100 degrees)<sup>(7)</sup>.

For evaluating gastroesophageal refluxate, the transducer was placed longitudinally in the midline just below the xiphisternum with tilting approximately 45 degrees upwardly. Refluxate is defined as luminal anechoic fluid and/or linear bright small lines indicating gas in refluxate, moving from the stomach to the lower esophagus. Any visualized refluxate above the gastroesophageal junction during a 15-minute period was considered as gastroesophageal reflux. The severity of liquid reflux was categorized to mild (1 to 3 reflux episodes), moderate (4 to 6 reflux episodes), and severe (>6 reflux episodes)<sup>(11)</sup>.

All parameters were not constant as a result of respiration and gastric filling. Therefore, all parameters were measured thrice, with the average value of each parameter recorded.

### MII-pH monitoring

Insertion of the catheter Medical Measurement Systems ([MMS], the Netherlands) was performed transnasally with the insertion depth of 87% of the calculated esophageal length followed the Strobel formula ( $0.252 \times \text{height [cm]} + 5$ )<sup>(12)</sup>. Proper positioning was confirmed by radiography<sup>(13)</sup>.

The MII-pH analysis and report were automatically generated by Medical Measurement Systems Investigation and Diagnostic Software, The Netherlands (version 9.3). A liquid reflux episode [RE] was defined by a retrograde drop in impedance of more

than 50% of baseline in the 2 distal channels. A gas RE was detected as an increase in impedance above 8,000 Ohms in any 2 consecutive channels that was excluded from the study result. A mixed RE met both liquid and gas RE<sup>(14)</sup>. Based on MII-pH result, liquid reflux was categorized into acid, weak acid, weak alkaline, and superimposed acid reflux. Acid reflux was defined by a drop in pH less than 4 for more than 5 seconds, while pH between 4 to 7 and pH above 7 were considered weak acid and weak alkaline reflux, respectively<sup>(12)</sup>. Superimposed acid reflux (acid re-reflux) was defined by acid reflux during acid clearance interval<sup>(15)</sup>. A reflux index [RI] was defined by the percentage of reflux time to the total monitoring time (more than 18 hours in all participants). GERD was diagnosed if the values of RI evaluated by pH monitoring was  $\geq 12\%$  for infants less than 1 year of age,  $\geq 6\%$  for children aged  $\geq 1$  year, and/or liquid and mixed reflux evaluated by impedance monitoring was greater than 95<sup>th</sup> percentile of age-specific values<sup>(12)</sup>.

### Statistical analysis

Continuous and categorical variables were described by median (interquartile range) or mean  $\pm$  SD as appropriate and frequency (%), respectively. Comparison of categorical data between the 2 groups used the Fisher exact test. Comparison of continuous data between the 2 groups used unpaired t-test. The  $p$ -value  $< 0.05$  was considered significant. The data was analyzed using Stata version 13.1 program (Texas, USA).

**Table 1.** Demographic data comparing between patients with clinical suspected GERD and healthy controls

Demographic data	Study group (n = 22)	Control group (n = 23)	p-value
Gender, male (%)	50	57	0.57
Age (year)	1.6 (0.6, 5)	1.7 (0.5, 7.5)	0.44
Height (meter)	0.81±0.31	0.84±0.33	0.73
Weight (kilogram)	13.20±13.60	11.40±12.5	0.66

Ages are expressed as median (interquartile range). Height and weight are expressed as mean ± SD

**Table 2.** Clinical characteristics of the 22 participants in the study group

Symptoms	Number (%)
Feeding intolerance	8 (36.4)
Recurrent vomiting	2 (9.1)
Heartburn	1 (4.6)
Recurrent pneumonia	5 (22.7)
Stridor	1 (4.6)
Reactive airway disease	1 (4.6)
Interstitial lung disease	1 (4.6)
Brief resolved unexplained events	3 (13.6)

## Results

### Demographics and clinical characteristics

Twenty-two children with clinical suspected GERD (50% male, median age 1.6 years [interquartile range 0.6 to 5 years]) and 23 healthy controls (57% male, median age 1.7 years [interquartile range 0.5 to 7.5 years]) were enrolled. There were no statistical differences between patients and controls for age, gender, height, and body weight (Table 1). Half of the participants with suspected GERD in the present study had gastrointestinal manifestations including feeding intolerance (n = 8), recurrent vomiting (n = 2), and heartburn (n = 1), while the others had extra-gastrointestinal manifestations including recurrent pneumonia (n = 5), stridor (n = 1), reactive airway disease (n = 1), interstitial lung disease (n = 1), and brief resolved unexplained event (n = 3) (Table 2).

### Transcutaneous esophageal US and MII-pH monitoring

Occurrence of refluxate and esophageal morphological parameters detected by transcutaneous esophageal US in participants who had clinical suspected GERD were not different from controls. However, participants who had clinical suspected GERD tended to have shorter abdominal esophageal

length compared with controls (Table 3).

Participants who were diagnosed with GERD by MII-pH monitoring (n = 6) tended to have higher cervical esophageal wall thickness and diameter, abdominal esophageal diameter, and degree of gastroesophageal angle than those with suspected GERD but having normal MII-pH monitoring (non-GERD). However, the differences were not statistically significant. The liquid reflux detected by transcutaneous esophageal US was not significantly different from abnormal reflux index and/or liquid reflux by MII-pH monitoring (Table 4).

## Discussion

The differentiation of GER from GERD is crucial to provide timely management of patients with GERD. The incidence of GERD is increasing because of physicians' awareness and the greater availability of diagnostic tests<sup>(16)</sup>. Transcutaneous esophageal US is a non-invasive technique with some evidence-based studies supporting its high diagnostic accuracy compared with pH monitoring for the diagnosis of GERD with good sensitivity and specificity of 76 to 100% and 50 to 100%, respectively<sup>(5,6,8,10,17)</sup>.

II-pH monitoring is currently considered the gold standard method for the diagnosis of GERD<sup>(18)</sup>. There have been numerous studies reporting on the superiority of MII-pH compared to pH monitoring in treated and untreated patients with GERD<sup>(19-21)</sup>. However, one of the factors affecting the accurate monitoring is the proper MII-pH catheter position. The suitable catheter positions in children are calculated by several methods<sup>(22-24)</sup> and mostly confirmed by chest radiography in the full expiration phase<sup>(18)</sup> instead of using esophageal manometry. Furthermore, normal reference values of MII-pH monitoring in children vary and depend on age. There are scarce data of normal MII-pH monitoring values in children due to the ethical issues to perform an invasive test on healthy children. The well-known study by Mousa et al<sup>(12)</sup>

**Table 3.** Comparison of parameters measured by transcutaneous esophageal US in the study and control groups

US parameters	Study group (n = 22)	Control group (n = 23)	p-value
Cervical esophageal thickness (mm)	1.84±0.78	1.88±0.39	0.86
Cervical esophageal diameter (mm)	5.71±1.96	6.26±1.79	0.49
Abdominal esophageal length (mm)	16.80±4.30	18.20±6.50	0.40
Abdominal esophageal length to height	0.02±0.01	0.02±0.01	0.88
Abdominal esophageal thickness (mm)	2.60±0.70	2.77±0.60	0.42
Abdominal esophageal diameter (mm)	7.10±1.40	7.00±2.20	0.90
His angle (degree)	120.90±17.20	129.00±18.60	0.14
Gastroesophageal angle			0.36
Completely obtuse (130° to 180°)	7 (32)	12 (53)	0.28
Obtuse (100° to 130°)	13 (59)	9 (39)	
Right angle (70° to 100°)	2 (9)	2 (8)	
Visualized refluxate (total)	6 (27)	3 (13)	0.28
Mild (1 to 3 refluxes)	5 (22)	2 (8)	
Moderate (4 to 6 refluxes)	0	1 (5)	
Severe (>6 refluxes)	1 (5)	0	

US = ultrasound

Data are expressed as mean ± SD or number (%)

**Table 4.** Comparison of parameters measured by transcutaneous esophageal US in GERD and non-GERD participants diagnosed by abnormal MII-pH monitoring

US parameters	GERD (n = 6)	Non-GERD (n = 16)	p-value
Cervical esophageal thickness (mm)	2.30±1.23	1.64±0.51	0.24
Cervical esophageal diameter (mm)	6.67±2.54	5.30±1.73	0.34
Abdominal esophageal length (mm)	17.70±4.20	16.42±4.50	0.57
Abdominal esophageal length to height	0.02±0.04	0.02±0.08	0.71
Abdominal esophageal thickness (mm)	2.66±0.70	2.47±0.47	0.58
Abdominal esophageal diameter (mm)	7.58±1.41	6.89±1.44	0.33
His angle (degree)	124.73±22.04	119.41±15.66	0.53
Gastroesophageal angle			0.25
Completely obtuse (130° to 180°)	3 (50)	4 (25)	0.73
Obtuse (100° to 130°)	2 (33)	11 (69)	
Right angle (70° to 100°)	1 (17)	1 (6)	
Visualized refluxate (total)	1 (16)	5 (31)	0.73
Mild (1 to 3 refluxes)	1 (16)	4 (25)	
Moderate (4 to 6 refluxes)	0	0	
Severe (>6 refluxes)	0	1 (6)	

GERD = gastroesophageal reflux disease; US = ultrasound

Data expressed as mean ± SD or number (percent)

provided a range of values characteristic of 46 infants and 71 children with no acid reflux and no positive temporal associations of reflux symptoms. These values were used as the normal references for the present study.

There have been studies reporting the

esophageal morphology evaluated by transcutaneous esophageal US in GERD patients diagnosed by pH monitoring. Comparing to normal children, GERD patients have more esophageal distension, thicker wall of cervical and abdominal esophagus, shorter abdominal esophagus, and more obtuse His angle. The



shortening of abdominal esophagus, in particular, has been observed in GERD patients<sup>(4,7,8,11)</sup>. Koumanidou et al<sup>(11)</sup> found that US measurement of the abdominal esophageal length is highly diagnostic for GER in neonates and infants, concluding that US should be suggested as the first imaging to be undertaken in infants with suspected GER. Fallahi et al<sup>(8)</sup> revealed that the length of the subdiaphragmatic part of the esophagus was significantly shorter in children with reflux than controls. Moreover mean esophageal diameter, wall and mucosal thickness, and hiatal diameter were all significantly larger compared to the control group. Halkiewicz et al and Karabulut et al<sup>(3,7)</sup> described the increased widening or more obtuse His angle found in children with reflux symptoms.

In the present study, occurrence of refluxate and esophageal morphological parameters detected by transcutaneous esophageal US in participants with suspected GERD were not significantly different from controls. However, participants with suspected GERD tended to have shorter abdominal esophageal length compared with controls. Participants who were diagnosed GERD by MII-pH monitoring had higher cervical/ abdominal esophageal wall thickness and diameter, and degree of gastroesophageal angle than those with non-GERD. These morphological findings might be related to the consequence of GERD. Changchien and Hsu<sup>(25)</sup> proposed that thickening of esophageal wall linked to inflammation caused by reflux content. Impaired esophageal peristalsis in GERD patients may contribute to higher esophageal diameter<sup>(3)</sup>. The widening of angle of His results in incompetent anti-reflux barrier which may cause reflux symptoms<sup>(7)</sup>.

The results of the present study in term of esophageal morphology that increases the risk of GERD, are different from previous studies. The conflicting result might be because this study used MII-pH monitoring instead of pH monitoring. MII-pH monitoring is able to diagnose both acid and non-acid refluxate which may cause abnormality of esophageal morphology differently. However, when the participants with GERD were divided into 2 subgroups, acid and non-acid GERD, the different esophageal morphology cannot be depicted because of the small number of participants in each group. Whether these esophageal morphologic findings are at risk for GERD are unclear. In term of occurrence of refluxate, the present study demonstrated that non-GERD participants tended to have greater number of visualized refluxate detected by transcutaneous esophageal US than those with

GERD. As the US was performed within 30 minutes after a regular milk meal, the visualized refluxate might be physiologic reflux from the normal transient esophageal sphincter relaxation. US examination might yield different results from MII-pH monitoring which measure the reflux parameters more physiologically. Other drawbacks of US examination are operator dependence and requirement of patient cooperation.

The novel and non-invasive tool that can detect the non-visualized refluxate should be developed. Further large well-designed studies focusing on esophageal morphology and promising novel parameters for acid and non-acid reflux detected by MII-pH study are merit.

## Conclusion

The number of occurrence of refluxate and esophageal morphology evaluated by transcutaneous esophageal US do not correlate well with the MII-pH monitoring results.

## What is already known on this topic?

Despite its invasiveness, MII-pH monitoring is considered the best method for the diagnosis of GERD. Transcutaneous esophageal US is a non-invasive tool demonstrated to be accurate in the demonstration of gastroesophageal reflux when using pH monitoring as the best method as previous studies reveal the good correlation of GERD with several esophageal anatomical abnormalities detected by transcutaneous esophageal US.

## What this study adds?

Occurrence of refluxate and esophageal morphology evaluated by transcutaneous esophageal US were not useful for diagnosing both acid and non-acid GERD when using MII-pH monitoring as the best method.

## Acknowledgements

The authors are grateful to the patients, volunteers and all the staffs of the Division of Gastroenterology and Hepatology, Department of Pediatrics, Department of Radiology and Center of Excellence for Neurogastroenterology and Motility, Faculty of Medicine, Chulalongkorn University. This study was supported by The Ratchadapisek Sompoch fund (RA 59/085).

## Potential conflicts of interest

None.

## References

- Osatakul S, Sriplung H, Puetaipoon A, Junjana CO, Chamnongpakdi S. Prevalence and natural course of gastroesophageal reflux symptoms: a 1-year cohort study in Thai infants. *J Pediatr Gastroenterol Nutr* 2002; 34: 63-7.
- Lightdale JR, Gremse DA. Gastroesophageal reflux: management guidance for the pediatrician. *Pediatrics* 2013; 131: e1684-95.
- Karabulut B, Bostanci I, Kacar M, Karaca G, Kosar P. Transcutaneous cervical and transabdominal ultrasonography as a diagnostic tool in gastroesophageal reflux in childhood. *ORL J Otorhinolaryngol Relat Spec* 2010; 72: 300-4.
- Gomes H, Menanteau B. Gastro-esophageal reflux: comparative study between sonography and pH monitoring. *Pediatr Radiol* 1991; 21: 168-74.
- Westra SJ, Derkx HH, Taminiu JA. Symptomatic gastroesophageal reflux: diagnosis with ultrasound. *J Pediatr Gastroenterol Nutr* 1994; 19: 58-64.
- Riccabona M, Maurer U, Lackner H, Uray E, Ring E. The role of sonography in the evaluation of gastro-oesophageal reflux—correlation to pH-metry. *Eur J Pediatr* 1992; 151: 655-7.
- Halkiewicz F, Kasner J, Karczewska K, Rusek-Zychma M. Ultrasound picture of gastroesophageal junction in children with reflux disease. *Med Sci Monit* 2000; 6: 96-9.
- Fallahi G, Saneian H, Mahdizadeh M, Farahm F. Children, gastroesophageal reflux and ultrasound. *Acta Medica Iranica* 2007; 45: 355-60.
- Savino A, Cecamore C, Matronola MF, Verrotti A, Mohn A, Chiarelli F, et al. US in the diagnosis of gastroesophageal reflux in children. *Pediatr Radiol* 2012; 42: 515-24.
- Farina R, Pennisi F, La Rosa M, Puglisi C, Mazzone G, Riva G, et al. Contrast-enhanced colour-Dopplersonography versus pH-metry in the diagnosis of gastro-oesophageal reflux in children. *Radiol Med* 2008; 113: 591-8.
- Koumanidou C, Vakaki M, Pitsoulakis G, Anagnostara A, Mirilas P. Sonographic measurement of the abdominal esophagus length in infancy: a diagnostic tool for gastroesophageal reflux. *AJR Am J Roentgenol* 2004; 183: 801-7.
- Mousa H, Machado R, Orsi M, Chao CS, Alhajj T, Alhajj M, et al. Combined multichannel intraluminal impedance-pH (MII-pH): multicenter report of normal values from 117 children. *Curr Gastroenterol Rep* 2014; 16: 400.
- Wenzl TG, Benninga MA, Loots CM, Salvatore S, Vandenplas Y. Indications, methodology, and interpretation of combined esophageal impedance-pH monitoring in children: ESPGHAN EURO-PIG standard protocol. *J Pediatr Gastroenterol Nutr* 2012; 55: 230-4.
- Black DD, Haggitt RC, Orenstein SR, Whittington PF. Esophagitis in infants. Morphometric histological diagnosis and correlation with measures of gastroesophageal reflux. *Gastroenterology* 1990; 98: 1408-14.
- Cho YK. How to interpret esophageal impedance pH monitoring. *J Neurogastroenterol Motil* 2010; 16: 327-30.
- Kacar S, Uysal S, Kuran S, Dagli U, Ozin Y, Karabulut E, et al. Transcutaneous cervical esophagus ultrasound in adults: relation with ambulatory 24-h pH-monitoring and esophageal manometry. *World J Gastroenterol* 2007; 13: 5245-52.
- Matrunola M, Grandin A, Mazza ML, Panetta A, Giardini V, Corrado G. Role of radiography and ultrasonography in the diagnosis of the pediatric gastro-oesophageal reflux disease. *Eur Rev Med Pharmacol Sci* 2003; 7: 147-9.
- Vandenplas Y, Rudolph CD, Di Lorenzo C, Hassall E, Liptak G, Mazur L, et al. Pediatric gastroesophageal reflux clinical practice guidelines: joint recommendations of the North American Society for Pediatric Gastroenterology, Hepatology, and Nutrition (NASPGHAN) and the European Society for Pediatric Gastroenterology, Hepatology, and Nutrition (ESPGHAN). *J Pediatr Gastroenterol Nutr* 2009; 49: 498-547.
- Rosen R, Lord C, Nurko S. The sensitivity of multichannel intraluminal impedance and the pH probe in the evaluation of gastroesophageal reflux in children. *Clin Gastroenterol Hepatol* 2006; 4: 167-72.
- Misra S. Can acid (pH) refluxes predict multichannel intraluminal impedance refluxes? A correlation study. *J Gastroenterol Hepatol* 2010; 25: 817-22.
- Francavilla R, Magista AM, Bucci N, Villirillo A, Boscarelli G, Mappa L, et al. Comparison of esophageal pH and multichannel intraluminal impedance testing in pediatric patients with suspected gastroesophageal reflux. *J Pediatr Gastroenterol Nutr* 2010; 50: 154-60.
- Moreau B, Kambites S, Levesque D. Esophageal length: esophageal manometry remains superior to mathematical equations. *J Pediatr Gastroenterol*