

Endoscopic Transaxillary Thyroid Lobectomy: Flexible vs Rigid Laparoscope

Suthep Udomsawaengsup MD*, Patpong Navicharern MD*,
Chadin Tharavej MD*, Suppa-ut Pungpapong MD*

* Department of Surgery, Faculty of Medicine, Chulalongkorn University

Background : The use of the endoscopic procedure for thyroid lobectomy in benign solitary thyroid nodule has been developed rapidly and increasingly refined in recent years. The early results are technically feasible, safe and mainly provide promising cosmetic results, some show a quicker recovery. The authors wanted to know if this procedure can be performed via rigid laparoscope which is simple, less expensive and widely available in many surgical centers.

Objectives : The aims of this study were to evaluate operative time, blood loss, complication of flexible compared to 30° rigid laparoscope in endoscopic transaxillary thyroid lobectomy for solitary thyroid nodule.

Method : From February 2004 to June 2004, 13 cases of benign solitary thyroid nodule underwent the endoscopic transaxillary thyroid lobectomy. Flexible laparoscope techniques were performed in 9 cases and 30° rigid laparoscope in the other 4 cases. Port site, number of ports and dissected method were the same in both procedures by the same surgeon. Operative time, blood loss, post-operative results were measured for evaluation.

Results : From 13 cases, 9 in the flexible laparoscope group and 4 in the rigid laparoscope group. All but one in the flexible group with torn internal jugular vein were successful. The mean operation time was 165.42 ± 35.06 minutes, which was 175.63 ± 35.70 minutes for flexible laparoscope group and 145 ± 26.45 minutes for rigid laparoscope group. There was no recurrent laryngeal nerve injury and no subcutaneous emphysema. The patients were satisfied with the cosmetic results.

Conclusion : On the basis of early experience with these 13 patients, the authors believe that endoscopic thyroidectomy using the rigid laparoscope has proved to be no different in the intra-operative results, so the authors do aimed to show that with the rigid laparoscope which is available in many surgical centers, less expensive and easy in maintenance will provide another surgical option for treatment of thyroid nodule, with maximized cosmetic effect.

Keywords : Endoscopic surgery, Endocrine surgery, Thyroidectomy, Thyroid lobectomy, Axillary approach, Rigid laparoscope

J Med Assoc Thai 2004; 87 (Suppl 2): S10-4

e-Journal: <http://www.medassocthai.org/journal>

The treatment of benign solitary thyroid nodule, according to many clinical practice guidelines is mainly medical treatment but thyroidectomy is still necessary in many specific cases. The open thyroidectomy is well developed and with good surgical results but these procedures require a collar incision in the exposed area of the neck especially in women which are a markedly higher incidence than in men⁽⁸⁾.

Since the 1980s, minimal access surgery has been developed and several years later, laparoscopic surgery has begun to replace the conventional technique. For neck surgery, Gagner⁽¹⁾ was the first to report the endoscopic subtotal thyroidectomy using gas insufflations in 1996, with good results and a small neck incision but neck scars are still highly unsatisfactory to many patients. Later on the surgery was improved to serve these cosmetic goals.

Correspondence to : Udomsawaengsup S. Department of Surgery, Faculty of Medicine, Chulalongkorn University, Bangkok 10330, Thailand.

Ikeda⁽²⁾ reported the axillary approach using the flexible laparoscope (EL2-TF410; Fujinon, Tokyo, Japan) with 3 axillary incisions in the year 2000 for hemithyroidectomy and obtained good clinical and cosmetic results.

Chantawibul⁽³⁾ et al from Rajavithi Hospital also reported the axillary approach using the flexible laparoscope with 4 incisions in 2003; the additional port was for the retraction and suction. The results provided promising cosmetic results.

Nowadays, the endoscopic thyroidectomy is still limited in some centers⁽⁹⁾. According to the time consumed for the long-learning curve and the equipment dependence because most of the published techniques used the flexible scope which is available only in some centers. From the manufactory information the rigid laparoscope is more durable and less expensive. As a result the authors adopted to use the rigid laparoscope for endoscopic thyroidectomy after had experience with the flexible laparoscope techniques.

Patients and Method

From February 2004 to June 2004, 13 cases of benign solitary thyroid nodule which were 50 mm or less in the largest diameter were eligible for endoscopic transaxillary thyroid lobectomy. Patients with previous neck surgery or thyroid cancer were considered as contraindication. After first, there were 9 cases of flexible laparoscope because of increased experience and were more comfortable with the procedure, The authors adopted to use the rigid scope.

All the patients had completed a preoperative evaluation (thyroid function test, ultrasonography and fine needle aspiration cytology) and pre-admission screening (complete blood count, basic biochemical assessment, chest x-ray, EKG (if age > 40 yr)).

The operative technique was briefly described. The patients were under general anesthesia, placed in the supine position, face turned slightly to the opposite side, the neck was slightly extend but not hyperextension half shoulder support as usual in the conventional technique. The ipsilateral forearm was hung over the face to expose the axilla.

The surgical team was composed of a surgeon and two assistants, one of them held the camera and one had the grasper or retractor for the sternocleidomastoid retraction. All the teams were sitting in between the patient axilla.

A 1.5 cm skin incision was performed about 1 cm behind the border of the anterior axillary fold. The subcutaneous flap was harvested above the pectorals fascia using the blunt technique above the clavicle and the anterior neck above the sternocleidomastoid up to the thyroid cartilage. The 5 mm diameters, 60 mm length disposable trocars (LiNA Ports) were inserted under direct vision on the planed position with the screwing technique to prevent air leakage. The endoscopic surgery was performed next as follows.

The 12 mm blunt tip trocar with smooth sleeve (Endopath Tristar 512 B; Ethicon Endo-Surgery, Cincinnati, Ohio, USA) was fixed with nylon # 3-0. The carbon dioxide was insufflated at 4 mmHg. The Fujinon 4-way tip deflection flexible laparoscope (EL2-TF410; Fujinon, Tokyo, Japan) for flexible-Fujinon group, the Olympus Laparo-Thoraco Videoscope (LTF-V3 Viscera; Olympus Optical, Tokyo, Japan) for flexible-Olympus group and the 10 mm, 30 degree rigid laparoscope (A 5254; Olympus Optical, Tokyo, Japan) for rigid laparoscope group were inserted through the 12 mm port. Then the instruments were inserted through the 5 mm ports. The Harmonic Scalpel (5 mm diameter, 33

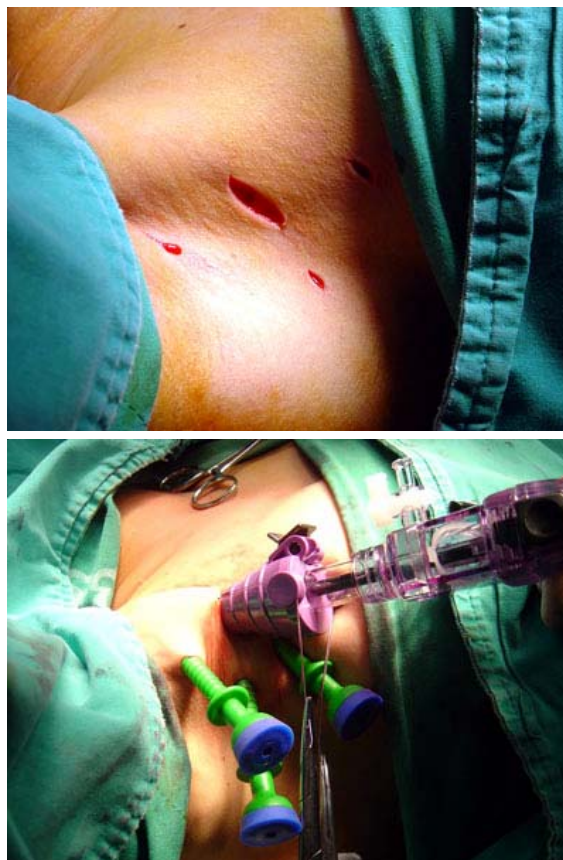

Fig. 1 Incisions and port positions

mm length; LCS5: Ethicon Endo-Surgery, Cincinnati, Ohio, USA) was used for tissue dissection and bleeding control, two 5 mm atraumatic graspers were used for tissue handling and sternocleidomastoid muscle retraction.

Orientation: Under the endoscopic vision, the medial border of the sternocleidomastoid which was the main landmark was dissected deep in between the strap muscle. The thyroid lobe was carefully dissected from the strap muscles by elevating the sternothyroid muscle up. The middle thyroid vein, if present was secured then the sheet between the thyroid and the carotid was completely opened to expose the pre-vertebral plane.

Recurrent laryngeal nerve and parathyroid glands: The traction over the thyroid with care taken to avoid any rupture was medially and superiorly to expose the tracheo-esophageal groove. The recurrent laryngeal nerve was identified in the groove or where it crosses the inferior thyroid artery is then dissected away from the thyroid lobe. Parathyroid glands were easily identified.

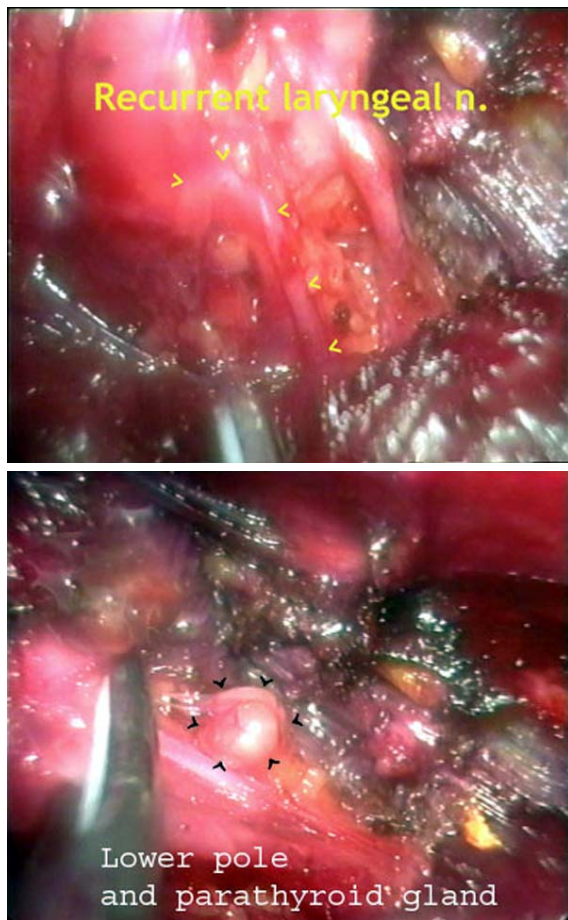


Fig. 2 Recurrent laryngeal nerve and parathyroid gland

The lower pole: The traction then cranially and medially to expose the lower pole where inferior thyroid gland and thyroid ima arteries are, and inferior thyroid vein are identified and controlled with the Harmonic scalpel.

The upper pole and external branch of superior laryngeal nerve: The thyroid lobe was retracted downward to expose the superior pole where

the vessels were controlled after the external branch of the superior laryngeal nerve was identified and preserved.

The Berry ligament and the isthmus: The Berry ligament was dissected and the thyroid lobe detached from the trachea with careful checks of the RLN and parathyroid gland. The isthmus was dissected with the harmonic scalpel.

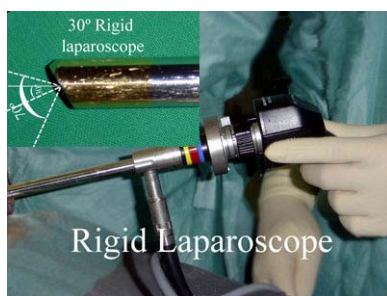After the hemostasis was checked and secured, 9 Fr Redivac drain was placed through the 5 mm trocar, the endoscopic procedure was completed, trocars were removed and the specimen was retrieved through the 1.5 cm incision. Incisions are closed with subcutaneous sutures.

Results

Thirteen cases were included in the present study. There were 12 females (92.3%) and 1 male (7.7%) with a mean age of 34.38 ± 13.22 Yr. Pre-operative diagnoses were as follows: 3 cystic nodule, 6 benign goiter, and 4 colloid nodule. The mean nodule diameter was 3.16 ± 1.01 cm.

The procedure was successfully carried out in 12 cases (92.3%) only one case in the flexible group converted to open because of partial jugular vein injury. In this case, the patient recovered well without any serious complication. The endoscopic transaxillary thyroid lobectomies were performed: 9 cases using the flexible laparoscope and 4 cases using the rigid laparoscope. The mean operative time was 165.42 ± 35.06 min, which was 175.63 ± 35.70 min for the flexible group and 145 ± 26.45 min for the rigid group. The mean blood loss was 40 ± 22.56 cc which was 45 ± 25.07 cc for the flexible group and 30.00 ± 14.14 cc for the rigid group.

Final histology showed 10 benign goiter, and 3 cystic nodule. There was no post-operative complication, no subcutaneous emphysema, and no voice changing. The cosmetic results were considered excellent in all the cases.



A 5254; Olympus



LTF-V3; Olympus



EL2-TF410; Fujinon

Fig 3. Rigid laparoscope, Flexible laparoscope

Table 1. Patient data

	Mean	Flexible gr (8)	Rigid gr (4)	range
Age (yr)	34.83±13.22	38.5±14.59	27.5±6.03	22-57
Male/Female	1/12	1/7	0/4	N/A
Tumor size (cm)	3.16±1.01	3.30±1.16	2.73±0.79	2.0-5.0
Operative time (min)	165.42±35.06	175.62±35.70	145±26.45	105-225
Blood loss (ml)	40.00±22.56	45.00±25.07	30.00±14.14	20-100
Hospital stay (day)	4.63±1.06	5.00±1.07	4.25±0.5	3-6

Discussion

The minimally invasive surgery for thyroid pathology has been described during the last 8 years^(1,9). The full endoscopic thyroidectomy is performed by remote access; there is no surgical scar in an exposed area of the neck which is superior to the conventional technique⁽²⁾. There are many sites for accessing such as the anterior chest⁽¹⁰⁾, breast⁽⁴⁾, and axilla⁽³⁾. The axillary approach has small scars in the axilla which are quite faint and difficult to demonstrate and completely covered with the patient's arm in its natural position^(2,3,6,7). By the endoscopic view, the thyroid gland is visualized clearly, the recurrent laryngeal nerve, the parathyroid glands, the external branch of the superior laryngeal nerve are easily identified and prevented from uneventful injury^(5,8). The previously published techniques were performed by flexible laparoscope^(2,3,7). From the present study by using the rigid laparoscope, there were no differences in all the aspects and can replace the need of a flexible scope.

The potential advantages of the rigid laparoscopic technique are 1) the basic, more durable, less expensive and easier maintenance laparoscopic set requirement. 2) decreasing the visual field interruption due to the blending of the tip of the flexible scope during the intra-operative instrument fencing effect. 3) diminishing the operative view, obstruction by the working instruments when dissection processed deeply into the deep cervical space where all the working instruments converged because of the 30 degree camera tip. 4) dissecting ports can be closed to the camera since the dissecting instrument usually travels parallel to the laparoscope 5) more comfortable for the camera person to handle and provide the working view even with one hand, and the surgical team can be reduced in to 2. 6) the rigid laparoscope acts indirectly as the pla-

tysmal flap lifting to provide the wider working space.

The disadvantages of the rigid laparoscope are 1) the fog effect due to higher temperature and humidity. To prevent this the scope is placed in a warmer body temperature or using the antifog solution 2) the 30 degree laparoscope make, the image much darker than 0 degree laparoscope but there is no significance with normal using light source. 3) the built in Len washing system (Fujinon EL2-FT410) reduces the need to remove the scope for tip cleaning. 4) long operative time compared to the conventional technique but there is no difference between the rigid and flexible group.

Conclusion

The 30 degree laparoscope which is widely available in many surgical centers is comparable to the flexible laparoscope in providing an excellent accessing view. There are some potential advantages of the rigid laparoscope in this procedure but it needs more cases for statistic evaluation.

References

1. Gagner M. Endoscopic subtotal parathyroidectomy in patients with primary hyperparathyroidism. *Br J Surg* 1996; 83: 875.
2. Ikeda Y, Takami H, Sasaki Y, Kan S, Niimi M. Endoscopic neck surgery by the axillary approach. *J Am Coll Surg* 2000; 191: 336-40.
3. Chantawibul S, Lokechareonlarp S, Pokawatana C. Total video endoscopic thyroidectomy by an axillary approach. *J parosc Adv Surg Tech* 2003; 13: 295-9.
4. Ogami M, Ishii S, Arisawa Y, et al. Scarless endoscopic thyroidectomy; breast approach for better cosmetics. *Surg Laparosc Endosc Percutan Tech*. 2000; 10: 339.
5. Miccoli P, Berti P, Raffaelli M, et al. Comparison between minimally invasive video-assisted thyroidectomy: a prospective randomized study. *Surgery* 2001; 130: 1039-43.
6. Ikeda Y, Takami H, Niimi M, Kan S, Sasaki Y, Takayama J. Endoscopic thyroidectomy and parathyroidectomy by the axillary approach: A preliminary report. *Surg Endosc* 2002; 16: 92-5.
7. Ikeda Y, Takami H, Sasaki Y, Takayama J, Niimi M, Kan S. Clinical benefit in endoscopic thyroidectomy by the axillary approach. *J Am Coll Surg* 2003; 196: 189-95.
8. Bliss R, Gauger P, Delbridge L. Surgeon's approach to the thyroid gland: surgical anatomy and the importance of technique. *World J Surg* 2000; 24: 891-7.
9. Miccoli M, Bellantone R, Mourad M, Walz M, Raffaelli M, Berti P. Minimally invasive video-assisted thyroidectomy: multiinstitutional experience. *World J Surg* 2002; 26: 972-5.
10. Inabnet III W, Jacob B, Gagner M. Minimally invasive endoscopic thyroidectomy by a cervical approach: early vessel ligation decrease the duration of surgery. *Surg Endosc* 2003; 17: 1808-11.

การผ่าตัด endoscopic transaxillary thyroid lobectomy ระหว่างการใช้กล้องแบบ flexible และ rigid laparoscope

สุเทพ อุดมแสงทรัพย์, พัฒนพงศ์ นาวิเจริญ, ชฎิล ธาระเวช, ศุภอัฐ พึ่งพาพงศ์

เหตุผลการทำวิจัย : การผ่าตัด endoscopic surgery สำหรับก้อนเดี่ยวต่อมไทรอยด์ชนิดไม่ร้าย (benign solitary thyroid nodule) ได้พัฒนาและเริ่มเห็นผลดีชัดเจนขึ้น โดยเฉพาะผลด้าน cosmetic คณะผู้วิจัยต้องการศึกษาว่าการผ่าตัดเทคนิคดังกล่าวสามารถทำได้โดยใช้กล้องชนิด rigid laparoscope ได้หรือไม่ เมื่อเทียบกับกล้องชนิด flexible เนื่องจากกล้อง rigid laparoscope มีข้ออยู่แพร่หลายและมีราคาย่อมเยากว่า รวมทั้งมีความคงทน

วัตถุประสงค์ : เพื่อเปรียบเทียบปัจจัยต่าง ๆ ระหว่างผ่าตัดได้แก่ ระยะเวลาผ่าตัด การเสียเลือด, ผลข้างเคียง เมื่อใช้กล้อง flexible เทียบกับกล้อง rigid laparoscope

สถานที่ทำการศึกษา : ภาควิชาศัลยศาสตร์ คณะแพทยศาสตร์ จุฬาลงกรณ์มหาวิทยาลัย

รูปแบบการวิจัย : การวิจัยเชิงทดลอง

วิธีการศึกษาและวัดผล : ทำการศึกษาตั้งแต่เดือน กุมภาพันธ์ 2547 ถึง มิถุนายน 2547 ผู้ป่วย 13 ราย ได้รับการผ่าตัดโดยใช้กล้อง flexible 9 ราย, กล้อง rigid 4 ราย ใช้วิธีการผ่าตัดแบบเดียวกัน โดยทีมผ่าตัดทีมเดียวกัน บันทึกระยะเวลาผ่าตัด ปริมาณเลือดที่เสียและผลหลังการผ่าตัดเพื่อเปรียบเทียบ

ผลการศึกษา : ผู้ป่วยทุกรายผ่าตัดได้สำเร็จดี ยกเว้น 1 ราย ในกลุ่ม flexible ซึ่งมีปัญหาเลือดออกจากเส้นเลือดดำและเปลี่ยนเป็นผ่าตัดแบบปกติ ซึ่งได้ผลหลังผ่าตัดเป็นที่พอใจ ระยะเวลาผ่าตัด 165.42 ± 35.06 นาที โดยกลุ่ม flexible ใช้เวลาเฉลี่ย 175.63 ± 35.70 นาที กลุ่ม rigid เฉลี่ย 145 ± 26.45 นาที ไม่มีปัญหาเสียงแหบ, ไม่มี subcutaneous emphysema ผู้ป่วยพอใจอย่างมากต่อผลการผ่าตัด

วิจารณ์และสรุป : จากผลการศึกษาในเบื้องต้น ผู้วิจัยมีความมั่นใจว่าการผ่าตัด endoscopic thyroid lobectomy สามารถทำได้โดยใช้กล้อง rigid laparoscope โดยไม่มีผลแตกต่างใด ๆ และคาดหวังว่าการผ่าตัดเทคนิคดังกล่าวจะเป็นที่ยอมรับและแพร่หลายมากขึ้น สำหรับค่าทางสถิติคงต้องรอการศึกษาอีกระยะเวลาหนึ่ง