

Cesarean Scar Pregnancy: A Case Report and Literature Review

Rodpenpear N, MD¹, Laosooksathit W, MD¹, Phasipol P, MD¹, Promsonthi P, MD¹, Raungrongmorakot K, MD¹, Rangsirattanakul L, MD²

¹ Department of Obstetrics and Gynaecology, HRH Princess Maha Chakri Sirindhorn Medical Center, Faculty of Medicine, Srinakharinwirot University, Nakhon Nayok, Thailand

² Department of Pathology, HRH Princess Maha Chakri Sirindhorn Medical Center, Faculty of Medicine, Srinakharinwirot University, Nakhon Nayok, Thailand

Cesarean scar pregnancy (CSP) is a rare disease. Because of the serious consequences of the disease, early diagnosis and treatment are very important. Furthermore, the diagnosis is difficult and the standard treatment is still unknown. We reported a rare case of 33-year-old woman, Para 2-0-0-2 with cesarean section of prior two pregnancies, presented with abnormal vaginal bleeding for 2 months. The uterus was slightly enlarged but otherwise unremarkable. Urine pregnancy test was positive. Gestational age was about 8 weeks from the last periods. Transvaginal ultrasonography revealed heteroechoic mass size 4.89x3.99x5.42 cm at anterior lower uterine segment occupied the hold thickness of the myometrium, adjacent to the uterine serosa. These findings were compatible with a cesarean scar pregnancy. After counseling regarding treatment options, the patient and her family could not accept risks for uterine preserving treatment and subsequent pregnancy complications and thus chose definitive surgery, hysterectomy. After surgery, no complication was observed. Therefore, hysterectomy is an alternative option for cesarean scar pregnancy treatment who could not take the risk of uterine preserving treatment.

Keywords: Cesarean scar pregnancy, Ectopic pregnancy, Hysterectomy

J Med Assoc Thai 2019;102(Suppl6): 105-10

Website: <http://www.jmatonline.com>

Cesarean scar pregnancy (CSP) is one type of ectopic pregnancy which implanted in the myometrium at previous cesarean section scar site. The incidence of CSP was estimated to be 1/3,000 for the general obstetric population, 1/1,800 to 1/2,500 for all cesarean deliveries and 1/531 for women who had at least one cesarean delivery⁽¹⁾. Nowadays, the incident rate tends to increase because of the increase in cesarean delivery, increasing the use of imaging studies and improvement of the ultrasound imaging quality⁽²⁾. However, the exact incidence of CSP is still unknown.

CSP is not easily diagnosed, in which misdiagnosis rate at first consultation was 76%⁽²⁾. Early diagnosis is very important because of the risk of rupture can result in severe hemorrhage and maternal death. CSP can harm a women's life and affect future fertility⁽³⁾. Transvaginal ultrasound was a tool for early diagnosis in the suspicious patient⁽⁴⁾. It was simple and was the most practical method with an accuracy of 84.6% in diagnosis⁽⁵⁾. The authors reported such a rare

case of cesarean scar pregnancy diagnosed by transvaginal ultrasonography which was treated with a surgical approach.

Case Report

A thirty-three-year-old Thai woman, Para 2-0-0-2 with cesarean section of prior two pregnancies. The last pregnancy was 4 years ago. She presented at gynecological outpatient clinic with abnormal vaginal bleeding for two months. She used one pad daily without pelvic pain or masses. Neither anorexia, nor unintentional weight loss was experienced. Her last menstruation was two months ago without absence periods before. She was currently not using any contraceptive methods.

Physical examination was unremarkable. Vital signs were within normal limit. However, vaginal examination revealed minimal bloody discharge with normal vaginal mucosa. No cervical lesion was observed. The uterus was slightly enlarged without palpable adnexal mass. Cul-de-sac was not bulging.

Investigation showed a positive urine pregnancy test. The gestational age was about 8 weeks from the last her periods. Serum β -subunit of human chorionic gonadotrophin (β -hCG) was 2,396 mIU/ml. Transvaginal ultrasonography revealed a heteroechoic mass size 4.89x3.99x5.42 centimeter at anterior lower uterine segment which occupied the hold thickness of the myometrium, adjacent to the uterine serosa and without sliding organs sign. The endometrial cavity was

Correspondence to:

Rodpenpear N.

Department of Obstetrics and Gynaecology, HRH Princess Maha Chakri Sirindhorn Medical Center, Faculty of Medicine, Srinakharinwirot University, 62 Moo 7, Rangsit-Nakhon Nayok Road, Ongkharak, Nakhon Nayok 26120, Thailand

Phone: +66-37-395085 ext 60811

E-mail: noppornr@gswu.ac.th

How to cite this article: Rodpenpear N, Laosooksathit W, Phasipol P, Promsonthi P, Raungrongmorakot K, Rangsirattanakul L. Cesarean Scar Pregnancy: A Case Report and Literature Review. J Med Assoc Thai 2019;102(Suppl6): 105-10.

empty (Figure 1). Both ovaries showed normal appearance and no adnexal mass or free fluid were identified. We found gestational sac-like structure in this mass. However, no definite characteristic findings of gestational sac were identified (Figure 2). These findings were compatible with a cesarean scar pregnancy.

The patient and her family were counseled regarding the management options. We offered the choice of treatment: medical and surgical treatment which can preserve her uterus because of her desire to have another child. The authors also counseled the risk of massive hemorrhage, uterine rupture, need to emergency hysterectomy and subsequent pregnancy complications after successful treatment such as recurrent cesarean scar pregnancy, placenta previa, placenta adherence,

uterine rupture and preterm labor. After counseling, the patient and her family could not accept all risks as above mentioned and chose for a definitive surgery; i.e., hysterectomy.

In the operation, the mass was located at anterior lower uterine segment, covered by urinary bladder dome (Figure 3). After separating urinary bladder dome from the uterus, the uterine serosa was intact. After that, hysterectomy was completed successfully without complication. The estimated blood loss was 200 ml. Uterine specimen showed blood clot mass size 4x3 centimeter located at anterior lower uterine segment. Gestational sac-like was identified without definite fetal part (Figure 4). The patient was recovered well after hysterectomy without surgical complication and was discharged on day 3 post-operatively. Final pathological report

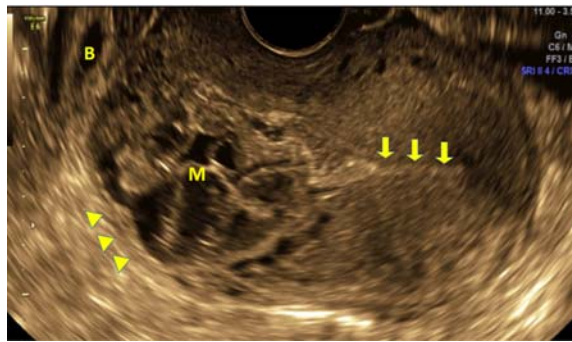

Figure 1. The transvaginal sagittal view of uterus shows heteroechoic mass at lower uterus (M) just above the edge of urinary bladder (B). The mass was very close to uterine serosa (arrow head) but smooth serosal surface still observed. The empty uterine cavity was noted (yellow arrow) without definite gestational sac.

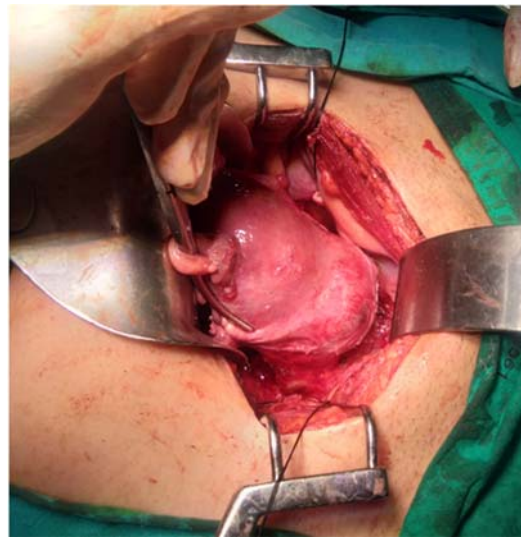


Figure 3. The mass located at lower uterine segment.

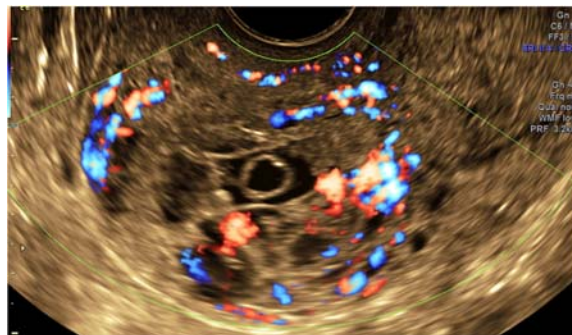


Figure 2. The transvaginal Power Doppler ultrasound revealed high vascularized mass. There was gestational sac-like structure in the middle but no characteristic rim enhancement of the gestational sac.

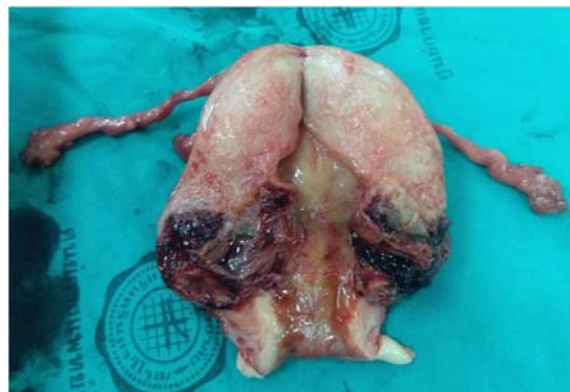

Figure 4. The mass with blood clot located at lower uterine segment with 1 mm apart from uterine serosa.

showed conceptus tissue, including decidual tissue, trophoblastic villi and blood, infiltrating in myometrium without perforation at lower uterine segment, which is compatible with cesarean scar pregnancy (Figure 5 to 7).

Discussion

CSP is defined as a gestation completely surrounded by myometrium and fibrous tissues of the cesarean section scar, separated from endometrium cavity and endocervical canal⁽⁶⁾. The first case was reported in 1978, not

as a CSP but as a post-abortion hemorrhage due to uterine scar sacculus⁽⁷⁾. After that, cases have been reported with a better understanding of the exact diagnosis.

The pathophysiology of CSP remains unclear. It was possible that the conceptus penetrates the myometrium through a microscopic dehiscence tract of the cesarean scar or impaired healing of the cesarean incision⁽⁸⁾. The predisposing factors for poor wound healing were an inadequate closure of the uterine incision, postoperative infections, impaired health condition such as diabetes or collagen disturbances and decreased blood flow to the affected tissue predisposes incomplete or delayed healing⁽⁹⁾. The short interval between the cesarean delivery and subsequent pregnancy also increased the probability of having CSP but the definition of a short interval was unclear⁽⁹⁾. However, it was still not clear whether these factors were directly related to CSP⁽¹⁰⁾. In this patient, we did not know the detail of previous cesarean section, but she did not have any other mentioned predisposing factors.

CSP was defined into two types; type I, endogenic type; type II, exogenic type⁽⁴⁾. The endogenic type would progress toward the cervico-isthmus space or uterine cavity which could result in a viable pregnancy but could develop a high risk of bleeding at the placental site. Exogenic type (our patient) refers to the implantation of the gestational sac progression toward the myometrium, uterine serosa and the bladder which could be complicated with uterine rupture and massive bleeding early in pregnancy. The thickness of the uterine myometrium between the gestational sac and the bladder wall was usually less than 4 millimeter in exogenic type. Therefore, once the exogenic type was diagnosed, immediate treatment was warranted⁽¹¹⁾.

Pathological diagnosis of cesarean scar pregnancy composed of histologic features of abnormal placental implantation and scar tissue without definite intervening decidua⁽¹²⁾ which compatible with this patient.

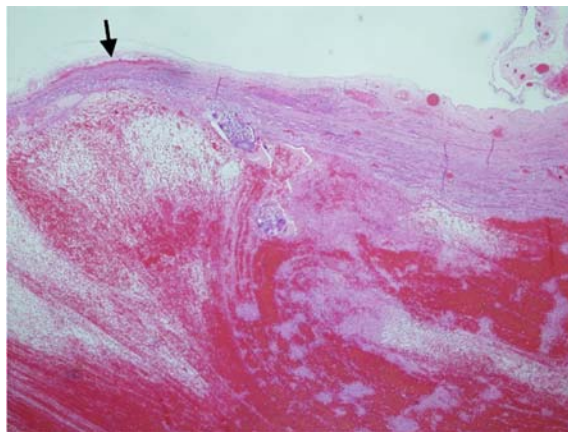


Figure 5. The gestational sac was bulging attached to the thin fibrous tissue without definite myometrium closed to the serosa of the lower uterine segment (black arrow).

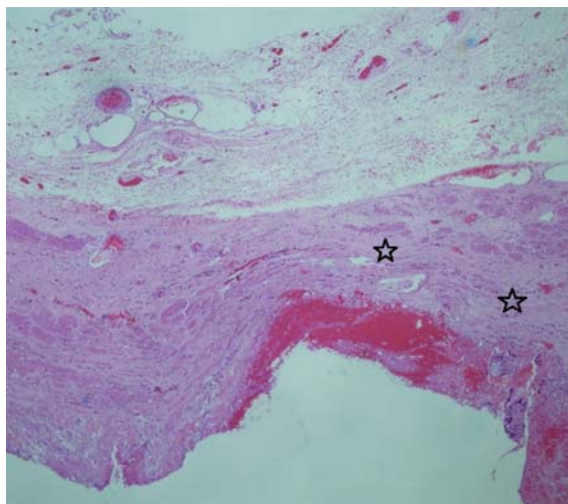


Figure 6. The evidence of scar from previous caesarean delivery (dense fibrous connective tissue; star symbol). It was tissue between gestational sac and serosa of the lower uterine segment

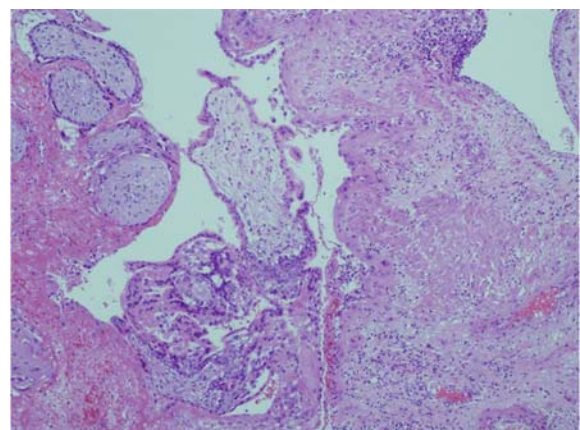


Figure 7. The sections showed chorionic villi invading myometrium without definite intervening decidua

Because of the serious consequences of CSP, early diagnosis and treatment are important. The most common clinical presentation was painless vaginal bleeding which reported 86.4%⁽¹³⁾. 24.6% of cases were reported with lower abdominal pain with or without vaginal bleeding⁽¹⁴⁾. Although, approximately 33.3% of cases were asymptomatic⁽¹⁵⁾. Ultrasonography was the first tool for diagnosing pregnancy at cesarean section scar and could soon be the gold standard tool⁽¹⁶⁾. Transvaginal ultrasound was the simplest and most practical method which reported to have sensitivity of 86.4%⁽¹⁷⁾. The diagnosis criteria were as following: 1) empty uterine cavity and empty cervical canal, 2) gestational sac in the anterior part of the uterine isthmus, 3) absence or diminished of healthy myometrium between the bladder and gestational sac, 4) clearly visible seen circular blood flow surrounding the gestational sac⁽¹⁶⁾. MRI was another diagnostic tool reported in the literature⁽¹⁸⁾. However, the MRI was recommended only in a equivocal diagnosis cases or those with complicated treatment plan⁽¹⁸⁾.

In this patient, transvaginal ultrasonography revealed heteroechoic mass at the anterior lower uterus occupied the hold thickness of the myometrium and met all above diagnosis criteria. The gentle pressure was placed during transvaginal ultrasound to identify “sliding organs sign” according to Jurkovic D report in 2003⁽¹⁹⁾, and the result was negative in this patient. This help the clinician to differentiate a caesarean scar pregnancy from a miscarriage.

From the ultrasound findings, the most likely diagnosis was cesarean scar pregnancy type II. This patient was definitely diagnosed by ultrasound so, we did not do another imaging such MRI. However, in equivocal diagnosis cases or those with complicated treatment plan, MRI may be useful, and is thus, recommended.

The principles of treatment were early diagnosis, early management and fertility preservation⁽⁵⁾. Treatment options included medical or surgical approach (uterine preserving surgery and definitive surgery), which should be tailored to an individual patient. Since most available literatures were observational studies with unclear population recruitment criteria, and meta-analysis could not be carried out owing to large proportion of different treatment⁽²⁰⁾, thus no standard treatment could be provided. To define an appropriate management decision of CSP, the following conditions must be considered; the size of pregnancy, presence or absence of uterine continuity, beta hCG level, fertility need and patient’s hemodynamic status⁽²¹⁾.

Expectant management has been reported to have successful outcome, but with high complication rate. Risk of placenta accreta, uterine rupture, massive hemorrhage and hypovolemic shock was increased, in which it usually ended up with hysterectomy⁽⁹⁾. The efficacy was low (41.5%) and the complication rate was high (53.7%)⁽²⁰⁾.

High-intensity focused ultrasound (HIFU) is a novel method. However, literatures on this issue are still too insufficient for recommendations. This procedure can be performed alone or in combination with hysteroscopic suction curettage. A retrospective study in 2014 revealed 16 patients

with CSP were treated by HIFU, with a 100% success rate and no severe complications⁽²²⁾. Another study of 53 CSP patients treated with HIFU combined with hysteroscopic suction curettage reported a 100% success rate and no severe complications⁽²³⁾. Thus, this technique seems to be a safe and effective alternative option for CSP treatment in the future. Systemic methotrexate can be used in hemodynamic stable patients without pain; especially in gestational age <8 weeks, myometrium thickness between gestational sac and bladder >2 mm, serum hCG <5,000 IU/ml, gestational sac \leq 2.5 cm and/or fetus without heart activity. A study reported success rate of 75.2% with a complication rate of 13%⁽¹⁹⁾. Multi-dose regimens had the similar outcome but had increased side effects, so; they were not suitable for this indication⁽²⁴⁾. Fibrous tissue surrounding gestational sac might play a role in reducing the absorption and the efficacy of methotrexate⁽¹⁰⁾. Despite this, local methotrexate can improve a little efficacy which success rate only of 73.9 to 88.5%⁽²⁵⁾.

Successful term pregnancy has been reported after uterine preservation treatment^(4,26). However, subsequent pregnancy complication such as recurrent cesarean scar pregnancy, uterine rupture, preterm labor and placenta accrete, were also reported⁽²⁶⁻²⁸⁾. One maternal death occurred from a uterine rupture at 38 weeks of gestation after CSP was treated by uterine curettage in previous pregnancy⁽²⁷⁾.

Hysterectomy is not the first choice of treatment. This procedure will be performed in a certain situation such as rupture uterus, unstable hemodynamic status or failure of medical treatment. In this patient, however, after counseling about treatment options, the patient could not accept the risks of massive bleeding, uterine rupture, emergency hysterectomy and especially possible complications with subsequence pregnancy. Therefore, hysterectomy is the optimal procedure in this circumstance.

Comparing medical treatment with surgical treatment, the prior had disadvantages in terms of slow resolution, persisting risk of uterine rupture and hemorrhage and need for additional treatment⁽²⁹⁾. Thus, the authors suggest surgical treatment either conservative or definitive surgery for CSP. Another important issue for CSP treatment is the follow-up planning. During treatment, it is necessary to monitor serum beta hCG level as an indicator of successful treatment. Except, definitive surgery is not necessary to monitor serum beta hCG, like in this patient.

In systematic review including 2,037 cases of CSP, Birch PK, et al reported 14 different options for CSP treatment but they recommended the best five approaches by efficacy, safety, study quality and level of evidence. These recommendations were hysteroscopic resection, transvaginal resection, uterine artery embolization combined with uterine curettage (UAE+D&C), uterine artery embolization combined with uterine curettage and hysteroscopic resection (UAE+D&C+hysteroscopy) and laparoscopic resection⁽²⁰⁾. These procedures had a success rate of 83 to 99%. Severe complications such as hysterectomy, bleeding more than 1,000 ml or blood transfusion were only found in 0 to 3.2%. Among these, hysterectomy was encountered in less than 1%.

Therefore, these procedures were safe and provided fertility preservation⁽²⁰⁾.

Standard treatment is still unknown. However, from the present evidence, we recommend surgical treatment because it provides a higher successful rate. Above all, the most important factor in choosing treatment modality should be counseling with the patient which included, treatment options, benefit and risk of each modality. In Thailand, there was only one published case report of cesarean scar pregnancy in 2011⁽³⁰⁾. The patient presented with abnormal vaginal bleeding and diagnosis was made using ultrasonography which was similar to our report. However, the operative procedure for that case was laparotomy excision of cesarean scar pregnancy. Although there was no intra- and post-operative complication, the author did not report long term outcome, i.e. subsequent pregnancy outcome, and did not mention of subsequent pregnancy risk in a pre-operative counseling⁽³⁰⁾. Therefore, hysterectomy should be considered as an alternative treatment for cesarean scar pregnancy in the patient who did not need fertility or could not accept the risk of uterine preserving treatment after extensive counseling.

Conclusion

Cesarean scar pregnancy is a rare condition but trends to increase in the future because of increasing cesarean section rate. Early diagnosis and treatment are very important because of severe consequences such as rupture, severe hemorrhage or maternal death may occur. Transvaginal ultrasound aids to early diagnosis. The principle of treatment is early diagnosis, early treatment and preserve fertility function as much as possible. Nowadays, the standard treatment of CSP is inconclusive. Treatment should be tailored to individual's decision after counseling.

What is already know on this topic?

Cesarean scar pregnancy is a rare disease and standard treatment is still unknown. The best five procedures were recommended in a systematic review which comprises of hysteroscopic resection, transvaginal resection, uterine artery embolization combined with uterine curettage (UAE+D&C), uterine artery embolization combined with uterine curettage and hysteroscopic resection (UAE+D&C+hysteroscopy) and laparoscopic resection.

What this study adds?

Hysterectomy is an alternative primary treatment for cesarean scar pregnancy in the patient who did not need future fertility or could not accept the risk of uterine preserving treatment after extensive counseling.

Acknowledgements

Thankfulness to the Department of Obstetrics and Gynecology, Department of Pathology, Faculty of Medicine, Srinakharinwirot University, Nakhon Nayok, Thailand.

Potential conflicts of interest

The authors declare no conflicts of interest.

References

1. Timor-Tritsch IE, Monteagudo A, Santos R, Tsymbal T, Pineda G, Arslan AA. The diagnosis, treatment, and follow-up of cesarean scar pregnancy. *Am J Obstet Gynecol* 2012;207:44-13.
2. Jurkovic D, Knez J, Appiah A, Farahani L, Mavrelos D, Ross JA. Surgical treatment of cesarean scar ectopic pregnancy: efficacy and safety of ultrasound-guided suction curettage. *Ultrasound Obstet Gynecol* 2016;47:511-7.
3. Al Nazer A, Omar L, Wahba M, Abbas T, Abdulkarim M. Ectopic intramural pregnancy developing at the site of a cesarean section scar: a case report. *Cases J* 2009;2:9404.
4. Vial Y, Petignat P, Hohlfield P. Pregnancy in a cesarean scar. *Ultrasound Obstet Gynecol* 2000;16:592-3.
5. Fu LP. Therapeutic approach for the cesarean scar pregnancy. *Medicine (Baltimore)* 2018;97:e0476.
6. Yan CM. A report of four cases of caesarean scar pregnancy in a period of 12 months. *Hong Kong Med J* 2007;13:141-3.
7. Larsen JV, Solomon MH. Pregnancy in a uterine scar sacculus an unusual cause of postabortal haemorrhage. A case report. *S Afr Med J* 1978;53:142-3.
8. Fadhlouai A, Khrouf M, Khemiri K, Nouira K, Chaker A, Zhioua F. Successful conservative treatment of a cesarean scar pregnancy with systemically administered methotrexate and subsequent dilatation and curettage: a case report. *Case Rep Obstet Gynecol* 2012;2012:248564.
9. Gonzalez N, Tulandi T. Cesarean scar pregnancy: a systematic review. *J Minim Invasive Gynecol* 2017;24:731-8.
10. Ash A, Smith A, Maxwell D. Cesarean scar pregnancy. *BJOG* 2007;114:253-63.
11. Sun YY, Xi XW, Yan Q, Qiao QQ, Feng YJ, Zhu YP. Management of type II unruptured cesarean scar pregnancy: Comparison of gestational mass excision and uterine artery embolization combined with methotrexate. *Taiwan J Obstet Gynecol* 2015;54:489-92.
12. Timor-Tritsch IE, Monteagudo A, Cali G, Palacios-Jaraquemada JM, Maymon R, Arslan AA, et al. Cesarean scar pregnancy and early placenta accreta share common histology. *Ultrasound Obstet Gynecol* 2014;43:383-95.
13. Ko JK, Li RH, Cheung VY. Cesarean scar pregnancy: a 10-year experience. *Aust N Z J Obstet Gynaecol* 2015; 55:64-9.
14. Ben Nagi J, Walker A, Jurkovic D, Yazbek J, Aplin JD. Effect of cesarean delivery on the endometrium. *Int J Gynaecol Obstet* 2009;106:30-4.
15. Riaz RM, Williams TR, Craig BM, Myers DT. Cesarean scar ectopic pregnancy: imaging features, current treatment options, and clinical outcomes. *Abdom Imaging* 2015;40:2589-99.
16. Roy MM, Radfar F. Management of a Viable Cesarean

- Scar Pregnancy: A Case Report. *Oman Med J* 2017;32: 161-6.
17. Rotas MA, Haberman S, Levгур M. Cesarean scar ectopic pregnancies: etiology, diagnosis, and management. *Obstet Gynecol* 2006;107:1373-81.
 18. Zosmer N, Fuller J, Shaikh H, Johns J, Ross JA. Natural history of early first-trimester pregnancies implanted in Cesarean scars. *Ultrasound Obstet Gynecol* 2015;46:367-75.
 19. Jurkovic D, Hillaby K, Woelfer B, Lawrence A, Salim R, Elson CJ. First-trimester diagnosis and management of pregnancies implanted into the lower uterine segment Cesarean section scar. *Ultrasound Obstet Gynecol* 2003; 21:220-7.
 20. Birch PK, Hoffmann E, Rifbjerg LC, Svarre NH. Cesarean scar pregnancy: a systematic review of treatment studies. *Fertil Steril* 2016;105:958-67.
 21. Pedraszewski P, WlaYlak E, Panek W, Surkont G. Cesarean scar pregnancy - a new challenge for obstetricians. *J Ultrason* 2018;18:56-62.
 22. Xiao J, Zhang S, Wang F, Wang Y, Shi Z, Zhou X, et al. Cesarean scar pregnancy: noninvasive and effective treatment with high-intensity focused ultrasound. *Am J Obstet Gynecol* 2014;211:356-7.
 23. Zhu X, Deng X, Wan Y, Xiao S, Huang J, Zhang L, et al. High-intensity focused ultrasound combined with suction curettage for the treatment of cesarean scar pregnancy. *Medicine (Baltimore)* 2015;94:e854.
 24. Barnhart KT, Gosman G, Ashby R, Sammel M. The medical management of ectopic pregnancy: a meta-analysis comparing "single dose" and "multidose" regimens. *Obstet Gynecol* 2003;101:778-84.
 25. Cheung VY. Local methotrexate injection as the first-line treatment for cesarean scar pregnancy: review of the literature. *J Minim Invasive Gynecol* 2015;22:753-8.
 26. Ben Nagi J, Helmy S, Ofili-Yebovi D, Yazbek J, Sawyer E, Jurkovic D. Reproductive outcomes of women with a previous history of caesarean scar ectopic pregnancies. *Hum Reprod* 2007;22:2012-5.
 27. Seow KM, Huang LW, Lin YH, Lin MY, Tsai YL, Hwang JL. Cesarean scar pregnancy: issues in management. *Ultrasound Obstet Gynecol* 2004;23:247-53.
 28. Seow KM, Hwang JL, Tsai YL, Huang LW, Lin YH, Hsieh BC. Subsequent pregnancy outcome after conservative treatment of a previous cesarean scar pregnancy. *Acta Obstet Gynecol Scand* 2004;83:1167-72.
 29. Polat I, Ekiz A, Acar DK, Kaya B, Ozkose B, Ozdemir C, et al. Suction curettage as first line treatment in cases with cesarean scar pregnancy: feasibility and effectiveness in early pregnancy. *J Matern Fetal Neonatal Med* 2016;29:1066-71.
 30. Phupong V, Narasethkamol A, Ultchaswadi P. Pregnancy in caesarean section scar. *J Obstet Gynaecol* 2011;31:204-6.