

## Case Report

# Late Postoperative Capsular Block Syndrome

Orasa Horatanaruang MD\*,  
Wantanee Saranyakoob MD\*

\* Department of Ophthalmology, Faculty of Medicine, Prince of Songkla University, Hat-Yai, Songkhla

*The authors report the case of a 61-year-old man with late postoperative capsular block syndrome who had undergone phacoemulsification and posterior chamber intraocular lens (IOL) implantation 3 years earlier. He presented with a decreased vision in the right eye caused by the accumulation of liquefied milky fluid in the space between the posterior surface of IOL optic and the posterior capsule. Neodymium:YAG laser posterior capsulotomy allowed a resolution of the milky fluid and the improvement of the visual acuity to 20/20.*

**Keywords:** Capsular block syndrome, Capsular bag hyperdistension, Continuous curvilinear capsulorhexis, Liquefied aftercataract, Posterior capsulotomy

**J Med Assoc Thai 2005; 88 (Suppl 9): S151-4**

**Full text. e-Journal:** <http://www.medassocthai.org/journal>

Continuous curvilinear capsulorhexis (CCC), developed by Gimbel and Neuhann<sup>(1)</sup> is an essential technique in phacoemulsification surgery. It allows firm lens implantation within the confines of the capsular bag, improves intraocular lens centration and creates a safer environment during phacoemulsification. However, disadvantages of CCC, although not many, have been reported. These include capsular bag hyperdistension, capsular block syndrome (CBS), shrinkage of the anterior capsule opening<sup>(2)</sup> and disruption of blood aqueous barrier<sup>(3)</sup>.

Capsular block syndrome (CBS) was characterized by an accumulation of liquefied substance within a closed chamber inside the capsular bag, secondary to the adherence of lens nucleus or the posterior chamber intraocular lens (IOL) to the anterior capsular edge. Depending on the time of onset, CBS can be classified as intraoperative (CBS seen at the time of lens luxation following hydrodissection), early postoperative (original CBS), and late postoperative (CBS with liquefied aftercataract or lacteocruentation)<sup>(4)</sup>.

The authors report a case of late postoperative CBS presented with the accumulation of liquefied milky fluid in the capsular bag posterior to IOL.

## Case Report

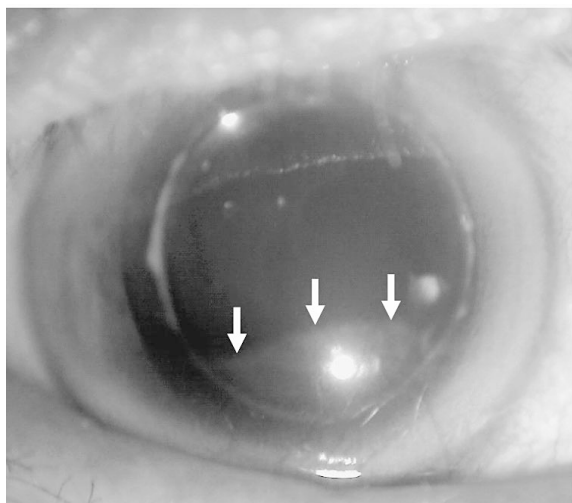
A 61-year-old Thai man with an unremarkable medical history was admitted to the authors' department in November 2000 with poor vision in his right eye. The examination revealed posterior subcapsular cataract in both eyes, the right eye more opaque than the left eye. Initial visual acuity (VA) was 20/50<sup>-2</sup> in the right eye and 20/30<sup>-2</sup> in the left. Phacoemulsification and IOL implantation was performed successfully in the right eye without immediate complications.

A clear temporal corneal incision was created with a 3 mm keratome after the anterior chamber was maintained with a viscoelastic substance (Viscoat®). Continuous curvilinear capsulorhexis, followed by phacoemulsification, was performed. The residual cortex was then removed with an irrigation/aspiration (I/A) tip. After the anterior and posterior capsule were polished, Viscoat® was injected into the capsular bag. An acrylic foldable IOL (Acrysof® MA60BM, Alcon) with a 6.0 mm optic was inserted in the capsular bag. The remaining viscoelastic was aspirated from the anterior chamber with an I/A tip. The corneal wound was then checked.

There were no intraoperative and postoperative complications. The patient's best corrected visual acuity (BCVA) at 1 week postoperatively was 20/20 and stable for more than 3 years.

In October 2002, the same procedure of phacoemulsification and IOL implantation was performed in

Correspondence to : Horatanaruang O, Department of Ophthalmology, Faculty of Medicine, Prince of Songkla University, Hat Yai, Songkhla 90110, Thailand. Fax: 0-7442-9619, E-mail: orasaho@yahoo.com



**Fig. 1** The Elschnig pearls at the inferior part of posterior capsule from 4-7 o'clock (arrows)

the left eye. The operation was uneventful. The BCVA at 1 week postoperatively was 20/30.

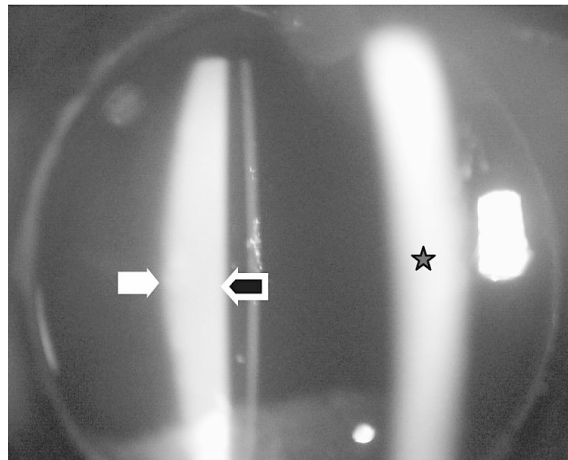
One year later, in December 2003, the patient complained of blurred vision in both eyes. The VA was 20/30 and 20/20 with 0-0.50 x 25 in the right eye, 20/80 and 20/25 with 0-1.50 x 180 in the left eye. Intraocular pressures by applanation tonometry were 14 mmHg in both eyes.

Slit lamp examination of the left eye was unremarkable, the IOL was well centered in the capsular bag. Slit lamp examination in the right eye showed an attachment of the entire edge of the margin of CCC to the peripheral IOL optic. Elschnig pearls were observed at the inferior part of posterior capsule (from 4-7 o'clock) under the IOL optic (Fig. 1). There was a pool of homogeneous milky white fluid between the IOL and the posterior capsule (Fig. 2). No cells or flares were detected in the anterior chamber. The cornea, vitreous body, and retina were unremarkable. Bifocal glasses were prescribed and the patient was followed 6 months later.

In May 2004, he complained of a decreased vision in the right eye for 1 month. The BCVA dropped to 20/25<sup>-2</sup>. The milky fluid was unchanged.

Neodymium:YAG (Nd:YAG) posterior capsulotomy was done in the right eye. After the first shot, the milky fluid gradually leaked into the anterior vitreous.

Ten days later, slit lamp examination revealed an opening of the posterior capsule with a complete disappearance of the milky fluid. Uncorrected visual acuity in the right eye was 20/20 (Fig. 3).




**Fig. 2** The slitlamp beam strikes the cornea (star), the presence of the homogeneous milky fluid between the posterior surface of the IOL (open arrow), and the posterior capsular bag. (filled arrow)

## Discussion

Postoperative accumulation of the milky fluid between the IOL and posterior capsule has previously been reported<sup>(4,6,11-15)</sup>. It is an unusual condition that obviously differs from posterior capsule opacification, which is classified as fibrous, Elschnig pearls, and Soemmering's ring<sup>(5)</sup>.

This condition should be differentiated from delayed endophthalmitis and early capsular block syndrome<sup>(6)</sup>. Delayed endophthalmitis, caused by



**Fig. 3** Photograph shows the disappearance of the milky fluid behind the IOL ten days after Nd:YAG laser capsulotomy

bacterial infection such as *Propionibacterium acne*, typically demonstrates a white plaque within the posterior capsule but usually associates with other inflammatory signs such as cells and flares in the anterior chamber, keratic precipitates and hypopyon<sup>(5,6)</sup>. In the presented case, slit lamp examination did not show any inflammatory signs that suggested this condition.

The early postoperative capsular block syndrome was first described by Davison<sup>(7)</sup>, and has a reported incidence of 1%. It originally described the condition of an accumulation of transparent fluid in the closed chamber between the IOL and posterior capsule formed by CCC margin occluded the IOL optic which mostly occur early within 1 day to 2 weeks after surgery<sup>(7,8)</sup>. This resulted in shifting of the posterior capsule, forward displacement of IOL, anterior chamber shallowing and inducing myopia<sup>(2,7,8)</sup>. The proposed mechanism was an induced osmotic gradient caused by retained cortical debris or perhaps by retained viscoelastic substance<sup>(7,8)</sup>.

This condition was different from the presented case, in which the fluid was not clear, anterior chamber was not shallow, refraction didn't show myopia and the onset was late (3 years).

Miyake et al<sup>(6)</sup>, reported a large series of the complication similar to the presented case of 41 patients who underwent uneventful phacoemulsification after CCC and posterior chamber polymethylmethacrylate IOL in all cases, so called liquefied aftercataract which the authors proposed to be a new type of aftercataract. The average onset of this condition was 3.8 years after surgery. The authors described that the adherence of the CCC edge to the anterior surface of the IOL optics was the initial event and allowed the liquid substance accumulated in the closed chamber similar to the early postoperative CBS but the fluid in the closed chamber was different in appearance, it was a liquefied milky white substance instead of transparent fluid.

In a few reports, this syndrome has occurred after IOL implantation in the sulcus<sup>(9)</sup> and after extracapsular cataract extraction with a can-opener capsulotomy<sup>(10-12)</sup> indicated that the previous theory did not explain all occurrences of the complication. The possible explanation was that the IOL adhered to the anterior capsule at the equator of the IOL, not on its anterior surface<sup>(12)</sup>.

Elfrig<sup>(13)</sup> also described the same complication in 3 patients but was called capsulorhexis-related lacteocumenasia.

There are several proposed mechanisms of the origin of the fluid. Either it was an aggregation of

collagen or extracellular matrix produced by residual lens epithelial cells or the retained lens cortex and the substance mentioned above induced an osmotic gradient across the capsule that subsequently draw water into the capsular bag<sup>(2,7,8)</sup>.

The authors observed the Elschnig pearl at the inferior periphery of the IOL optic connecting to the pocket of the fluid in the presented case, thus the authors also believed that the fluid might have originated from the residual lens epithelium we found.

Namba et al<sup>(14)</sup>, recently reported the biochemical analysis of the fluid by aspiration of the fluid via the temporal pars plana and found that the concentration of sodium hyaluronate resembled the normal aqueous humor, therefore he suggested that the viscoelastic substance was not likely to play an important role. In addition, the human serum albumin was the main protein constituent in this fluid by electrophoresis. This pattern was consistent with the pattern of the aqueous humor, thus they postulated that the plasmoid aqueous that was trapped in the capsular bag in the early postoperative period may have undergone changed and finally turned to the milky fluid.

The prognosis of patients with this complication appears favorable. In many cases the fluid resolved spontaneously without specific treatment<sup>(6,14,15)</sup>. In the presented case the milky fluid seemed unchanged during 6 months follow up and the patient complained of blurred vision so Nd:YAG laser posterior capsulotomy was performed. The treatment outcome was satisfactory. The visual acuity returned to 20/20 with complete disappearance of the fluid.

## References

1. Gimbel HV, Neuhann T. Development, advantages, and methods of the continuous circular capsulorhexis technique. J Cataract Refract Surg 1990; 16: 31-9.
2. Masket S. Postoperative complication of capsulorhexis. J Cataract Refract Surg 1993; 19: 721-4.
3. Tsuboi S, Tsujioka M, Kusebe T, Kojima S. Effect of continuous circular capsulorhexis and intraocular lens fixation on the blood aqueous barrier. Arch Ophthalmol 1992; 110: 1124-7.
4. Miyake K, Ota I, Ichihashi S, Miyake S, Tanaka Y, Terasaki H. New classification of capsular block syndrome. J Cataract Refract Surg 1998; 24: 1230-4.
5. Apple DJ, Solomon KD, Tetz MR, Assia EI, Holland EY, Legler UF, et al. Posterior capsule opacification. Survey Ophthalmol 1992; 37: 73-116.
6. Miyake K, Ota I, Miyake S, Horiguchi M. Lique-

- fied after cataract: a complication of continuous curvilinear capsulorhexis and intraocular lens implantation in the lens capsule. Am J Ophthalmol 1998; 125: 429-35.
7. Davison JA. Capsular bag distension after endophacoemulsification and posterior chamber intraocular lens implantation. J Cataract Refract Surg 1990; 16: 99-108.
  8. Holtz SJ. Postoperative capsular bag distension. J Cataract Refract Surg 1992; 18: 310-7.
  9. Nouri-Mahdavi K. Early capsular distension syndrome after sulcus implantation of intraocular lenses. J Cataract Refract Surg 2000; 26: 1833-5.
  10. Agrawal S, Agrawal J, Agrawal TP. Complete capsular bag distension syndrome. J Cataract Refract Surg 2000; 26: 1417-8.
  11. Starr MB. Liquefied after cataract: a complication of continuous curvilinear capsulorhexis and intraocular lens implantation in the lens capsule [letter]. Am J Ophthalmol 1998; 126: 612-3.
  12. Ghanam VC, Ghanem EA. Sudden decrease in vision caused by liquefied after-cataract. J Cataract Refract Surg 2003; 29: 210-2.
  13. Eifrig DE. Capsulorhexis-related lacteocumenasia. J Cataract Refract Surg 1997; 23: 450-4.
  14. Namba H, Namba R, Sugiura T, Miyauchi S. Accumulation of milky fluid: A late complication of cataract surgery. J Cataract Refract Surg 1999; 25: 1019-23.
  15. Namiki I, Miyake K, Ota I, Miyake S. Localized liquefied after-cataract. J Cataract Refract Surg 2003; 29: 207-9.

---

### **กลุ่มอาการ late postoperative capsular block: รายงานผู้ป่วย 1 ราย**

**อรสา ห่อรัตนเรือง, วันทนี ศรีณยุคปต์**

รายงานผู้ป่วยชายอายุ 61 ปี ได้รับการวินิจฉัยเป็น late postoperative capsular block หลังผ่าตัดสลายต้อกระจกด้วยคลื่นเสียงความถี่สูงและฝังเลนส์แก้วตาเทียมข้างขวา 3 ปี มาด้วยอาการตามัวลงร่วมกับตรวจพบการสะสมของสารน้ำสีขาวขุ่นอยู่ในช่องระหว่างเลนส์แก้วตาเทียมกับถุงหุ้มเลนส์ตาด้านหลัง ผู้ป่วยได้รับการรักษาด้วยการยิงเลเซอร์ Nd:YAG ไปที่ถุงหุ้มเลนส์ตาด้านหลัง หลังยิงเลเซอร์พบว่าสารน้ำสีขาวหายไปและระดับการมองเห็นของผู้ป่วยดีขึ้นเป็น 20/20