

Case Report

The Use of Nanocrystalline Silver for the Treatment of Massive Soft Tissue Defects with Exposed Bone

Kamonwan Jenwitheesuk MD*,
Palakorn Surakunprapha MD*, Bowornsilp Chowchuen MD, MBA*

* Division of Plastic Surgery, Department of Surgery, Faculty of Medicine, Khon Kaen University, Khon Kaen, Thailand

Background: In a complex wound with exposed tendon, joint or bone caused by trauma, soft tissue reconstruction is required to obtain function and aesthetic coverage. Surgical reconstruction can be performed using a variety of different techniques.

Objective: The authors report their experience using a nanocrystalline silver with or without vacuum assisted wound closure to salvage the exposed vital structures such as bone, joint or tendon in traumatic wounds.

Material and Method: The present study included 12 patients with 15 wounds that exposed vital structures especially in the lower extremities. After adequate debridement, four wounds were treated with nanocrystalline silver dressing and vacuum assisted wound closure, and ten wounds were treated in an out-patient program using nanocrystalline silver dressing.

Results: A preliminary evidence of impressive result was achieved with subsided infection and complete bony coverage by granulation tissue after treatment. Subsequently, a secondary healing or a split thickness skin graft was applied.

Conclusion: The authors present the satisfactory results of alternative techniques that may be used for the massive soft tissue defects with exposed bone.

Keywords: Exposed bone wound, Nanocrystalline silver dressing, Vacuum assisted wound closure

J Med Assoc Thai 2013; 96 (Suppl. 4): S177-S184

Full text. e-Journal: <http://jmat.mat.or.th>

In a complex wound with exposed tendon, joint or bone caused by trauma, soft tissue reconstruction is required to obtain functional and aesthetic coverage. Surgical reconstruction can be performed using a variety of different techniques, depending on the degree of injury that has exposed vital structures such as bone and tendon. Fascial or muscle flap has been the standard treatment. The advantage of muscle transfer used in the coverage of bone, especially in the case of osteomyelitis, is the ability to provide a rich vascular supply. Microsurgical free tissue transfer has become the accepted standard treatment and has great latitude in the restoration of form and function of defects of the hand, foot, head and neck but requires a specialized, microsurgery team. Moreover, in some situations, microvascular free flaps are not appropriate for reconstruction such as in patients with complex medical histories or the limitation in availability of adequate and reliable recipient vessels in the recipient area that could affect the successful transplantation⁽¹⁾.

Vacuum assisted wound closure (VAC) has been developed for wound healing by Argenta in 1997. The technique consists of an open-cell foam dressing placed into a wound. A side-hole evacuation tube is embedded in sponge-foam and connected to an adjustable vacuum source that ranges in pressure between 50 to 125 mmHg. The last step is sealing with an adhesive drape⁽²⁾. This method is effective even in an exposed bone wound⁽³⁾.

For antiseptics that may be used in the management of wound infection, silver is the choice for topical treatment of partial-thickness wounds and available in several forms including silver sulfadiazine cream and impregnated dressings. More recently, dressings have become available that release charged silver atoms (ionic silver – Ag⁺) on contact with wound fluid and require fewer frequent dressing changes. To prevent wound infection or recurrence of infection in high risk patients, the authors presented the experience of using impregnated dressings, containing nanocrystalline silver with or without vacuum assisted wound closure in the cases of complex wounds.

Material and Method

The purpose of the present study was to review our experience using a nanocrystalline silver,

Correspondence to:

Jenwitheesuk K, Division of Plastic Surgery, Department of Surgery, Faculty of Medicine, Khon Kaen University, Khon Kaen 40002, Thailand.

Phone & Fax: 043-348-393

E-mail: kamoje@kku.ac.th

Acticoat™ (Smith & Nephew, Bangkok, Thailand) with or without vacuum assisted wound closure to salvage the exposed vital structures such as bones, joints or tendons in traumatic wounds. The protocol of the present study was reviewed and approved by the Ethics Committee of Khon Kaen University, according to the standards set out in the Helsinki Declaration.

The authors performed a retrospective review of patients who presented with contaminated wound and/or combined fracture, treated in the Division of Plastic Surgery, Department of Surgery, Srinagarind Hospital, Faculty of Medicine, Khon Kaen University between 2006 and 2008. Twelve patients with 15 wounds that exposed bone, tendons, or joints with or without fractures that required bone fixation and associated soft-tissue reconstruction were reviewed. Two groups were included, a group of patients who experienced previous treatment from primary care hospitals with debridement, bone fixation and only had problems with the remaining wound defect and a group of patients who defined as a primary cases who had no previous treatment before referring to our hospital. Medical records included age, sex, comorbidity, mechanism of injury, bones involved, defect size, operation before dressing, dressing program, healing time and method of surgical reconstruction.

The initial treatment, including wound debridement of necrotic tissue and bone fixation were used before the dressing protocol was implemented. The patients were divided into two groups. In the wound that vacuum assisted wound closure could be used, the authors used nanocrystalline silver with vacuum assisted wound closure. However, in the wound that vacuum assisted wound closure could not be applied, nanocrystalline silver was applied alone. The nanocrystalline silver with vacuum assisted wound closure group, the patients needed hospitalization until complete treatment, but in nanocrystalline silver alone group, the patients could be treated as an out-patient program by visiting the outpatient clinic at the hospital or health care unit near the patient's home for dressing change every 3 days. After complete granulation, the next treatment was planned, including secondary healing or skin grafting. The treatment protocol is summarized in Fig. 1.

Results

Table 1 shows clinical data of the 12 patients with complex wounds that were treated with nanocrystalline silver dressing with or without VAC.

During the present study period, 12 patients

with 15 open wounds in various parts were included. The average age was 36.83 years with a range of 10 to 65 years, and 8 men constituted 83.33% of the patients. The most common cause of injury was traffic accidents.

Twelve wounds were located in the lower extremity. Three patients were associated with tibial and fibular fractures (Gustilo-Anderson grade 3B4 with a single artery remaining). One patient was presented with osteomyelitis and multiple medical problems, including chronic renal failure that needed dialysis. Three patients had 2 open wounds, located at medial and lateral aspects of the leg. Two patients were presented with exposed bones and joints at both sides of the great toe. One patient had a lesion at the forehead that exposed the frontal bone about 3x4 cm in size and an abrasion wound of the remaining skin of the forehead.

This patient refused reconstruction with a pedicle flap or free flap. One girl was presented with a third degree electrical burn with exposed proximal phalanx and proximal interphalangeal joints of right ring finger. Fourteen wounds were the results of trauma including, 10 from motorcycle crashes, 2 from car

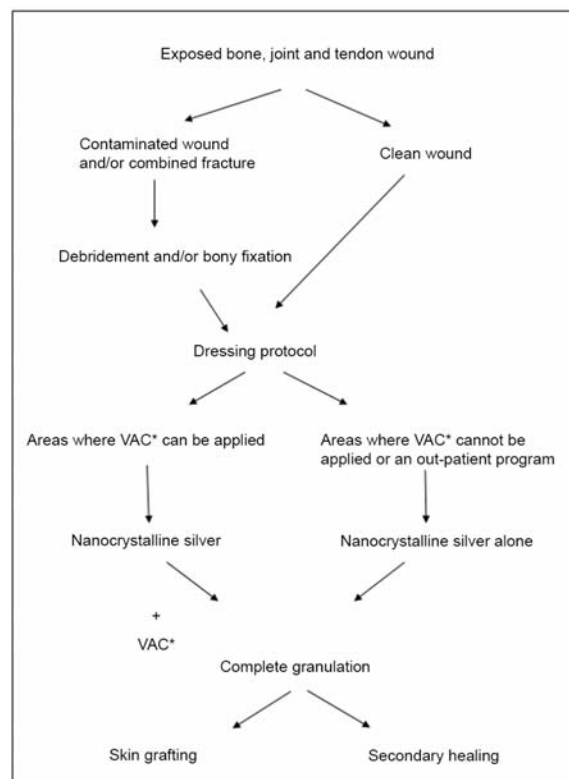


Fig. 1 Treatment protocol of nanocrystalline silver dressing with or without VAC. VAC* = vacuum assisted wound closure

Table 1. Clinical data of 12 patients with complex wounds that were treated with nanocrystalline silver dressing with or without VAC

No.	Sex	Age	Mechanism of injury	Bones involved	Co-morbidity	Operation before dressing	Dressing program	Defect size	Healing time	Surgical reconstruction
1	M	65	Car accident	Tibia and fibula	Chronic renal failure, Diabetes, Hypertension, Osteomyelitis of tibia	Wound debridement, External fixation	NS*+VAC**	3x6 cm	34 days	STSG***
2	M	21	Motorcycle accident	Tibia and fibula	Wound infection	Wound debridement, External fixation	NS*+VAC**	2x4 cm at medial of right leg 3x5 cm at lateral of right leg	32 days	STSG***
3	M	23	Machine tool injury	Tibia and fibula	Wound infection	Wound debridement, External fixation	NS*+VAC**	10x6 cm at right leg	50 days	STSG***
4	M	54	Car accident	Frontal bone	-	Wound debridement	NS*+VAC**	3x4 cm at left frontal area	33 days	FTSG****
5	F	10	Electrical burn	Proximal phalanx and PIP joint, right ring finger	Superficial burn at right thumb and middle finger	Wound debridement	NS*	1x2.5 cm	29 days	STSG***
6	F	55	Post CABG	Sternum	Osteomyelitis of sternum	Wound debridement	NS*	15x2 cm	60 days with secondary healing	-
7	M	42	Motorcycle accident	Metatarsal bone and joint, tendon	HIV infection	Wound debridement	NS*	5x7 cm at right foot	90 days with secondary healing	-
8	M	22	Motorcycle accident	Bilateral medial side of great toes and joints	-	Wound debridement	NS*	2x4 cm at right foot 2x4 cm at left foot	21 days	STSG***
9	M	23	Motorcycle accident	Bilateral medial side of great toes and joints	-	Wound debridement	NS*	2x2 cm at right foot 2x2 cm at left foot	60 days with secondary healing	-

Table 1. cont.

No.	Sex	Age	Mechanism of injury	Bones involved	Co-morbidity	Operation before dressing	Dressing program	Defect size	Healing time	Surgical reconstruction
10	M	55	Motorcycle accident	Calcaneous and achilles tendon	Heavy smoking status post reverse sural flap coverage defect and flap loss	Wound debridement	NS*	15x5 cm	49 days	STSG***
11	M	59	Motorcycle accident	Calcaneous and achilles tendon	Hypertension status post reverse sural flap coverage defect and flap loss	Wound debridement	NS*	4x4 cm	90 days with secondary healing	-
12	M	13	Motorcycle accident	Fibular exposure	Vascular injury	Wound debridement, Internal fixation	NS*	10x2 cm	90 days with secondary healing	-

accidents, 1 from machine injury and 1 from electrical burn. One patient was caused from a non-traumatic, dehiscence and infected sternal surgical wound after a cardiac bypass and suffered from osteomyelitis for 9 months. For the dressing program, four patients were treated with nanocrystalline silver dressing and vacuum assisted wound closure and 10 wounds were treated in as out-patient using nanocrystalline silver dressing after adequate debridement. Nine wounds required skin grafting: one with a full thickness skin graft and 8 with split thickness skin grafts. In forty percent of the cases, the wounds healed by secondary intension. The period of healing ranged from 29 to 90 days.

Case Report

Patient No. 3

A 23 year-old man with fractures of both bones of the right leg (Gustilo-Anderson grade 3B) was treated by debridement, external fixation and placement of nanocrystalline silver dressing with vacuum assisted wound closure for two weeks. Nearly completed granulation and secondary intension healing at one month and complete healing within 50 days was noted (Fig. 2).

Patient No. 7

A 42 year-old man with AIDS with a wound that exposed first and second metatarsal bone and

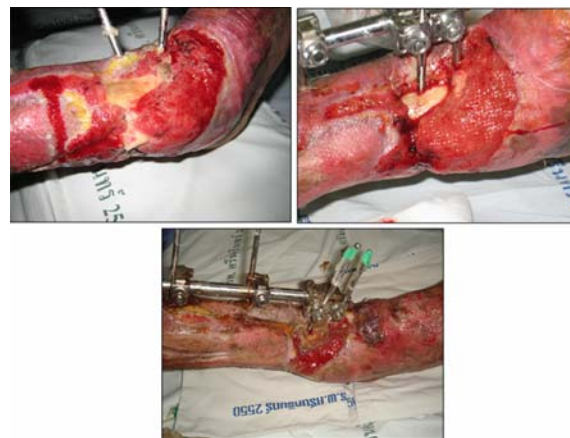


Fig. 2 Photos of a 23 year-old man with fractures of both bones of the right leg (Gustilo-Anderson grade 3B) (above left), after debridement and external fixation (above right), and after placement of nanocrystalline silver dressing with vacuum assisted wound closure for two weeks (below). Nearly completed granulation and secondary intension healing were noted at one month.

tendon was treated by debridement and placement with nanocrystalline silver dressing alone as an out-patient program for 3 months. Complete healing was achieved without skin graft (Fig. 3).

Patient No. 9

A drunken 23 year-old man with exposure of bone and joint of both great toes due to motorcycle accident was treated by debridement of his great toes and placement of nanocrystalline silver dressing alone as an out-patient program for 2 months. Complete healing without skin graft was achieved (Fig. 4).

Patient No. 12

A 13 year-old man with fractures of both bones of the right leg (Gustilo-Anderson grade 3B) was treated by debridement and internal fixation. Placement of nanocrystalline silver dressing alone in the out-patient program was performed on the wound exposed the fibula with a single remaining artery. After for 3 months, the wound was completely healed by secondary intention (Fig. 5).

Discussion

The authors present a preliminary report of the successful treatment in exposed bones, joints and tendons using nanocrystalline silver dressing and vacuum assisted wound closure and nanocrystalline silver dressing alone. The first patient described here is the initial case using the new protocol and is the case of complex medical history, chronic renal failure, osteomyelitis, fracture both bones and loss of tissue coverage after bony fixation.

The patient was not appropriate for major surgical procedures by using the microvascular free flap. For treatment of the infection, the authors used

nanocrystalline silver dressing applied to the wound first and then combined with VAC. The result of treatment was impressive, the infection subsided and granulation resulted in complete coverage of the bony part and then a split-thickness skin graft was applied. This evidence provides a choice for patients that are unable to undergo major surgery or refuse microsurgery. The literature does not seem report previous activities of nanocrystalline silver to initiate granulation in a bare bone defect. The previous reports of vacuum assisted wound closure about the initiation of healing in bare bone, joint or tendon implied that vacuum assisted wound closure was contraindicated in an infectious situation^(3,5-8). The combined technique can be advantageous even in infection. The explanation of healing by vacuum assisted wound closure may be through decreased transudate, exudate and wound edema that initiates more diffusion of oxygen to injured cells. The healing process is also improved by mechanotransductive pathways initiated by the cyclic compression and relaxation of the wound. This pathway

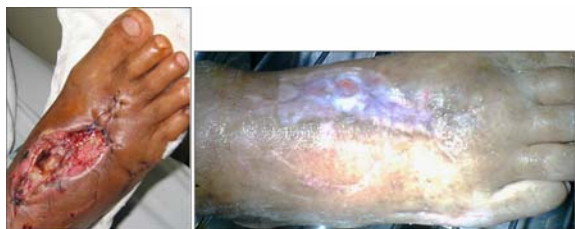

Fig. 3 A 42 year-old man with AIDS had a wound that exposed first and second metatarsal bone and tendon (above), treated by debridement and placement with nanocrystalline silver dressing alone as an out-patient program for 3 months (below). Completed healing was achieved without skin graft.

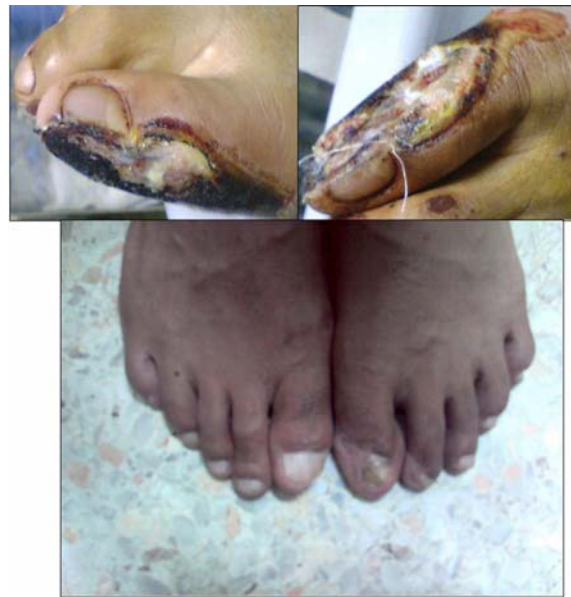

Fig. 4 A drunken 23 year-old man was presented with exposure of bone and joint of both great toes due to sitting behind the motorcycle driver, dropping both feet on the road and dragging them along it. Consequently, his great toes had been debrided (above left and right). Treatment was performed with debridement and placement of nanocrystalline silver dressing alone as an out-patient program for 2 months. Completed healing without skin graft was achieved (below).

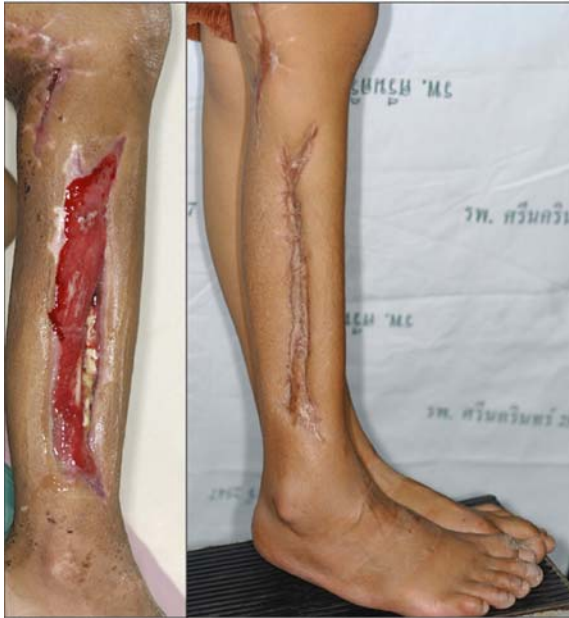

Fig. 5 A 13 year-old man was presented with fractures of both bones of the right leg (Gustilo-Anderson grade 3B) post debridement and internal fixation and the wound exposed the fibula with a single remaining artery (left). After placement of nanocrystalline silver dressing alone in the out-patient program for 3 months, the wound was completed healed by secondary intention (right).

promotes increased growth factors, matrix production and cellular proliferation⁽⁹⁾. Some parts of the body like hand, forehead, foot and toe, however, are very difficult to provide coverage with vacuum assisted wound closure because of air leaks and failure of negative pressure. In these cases, a nanocrystalline silver dressing was applied to the wound and the result was the development of granulation. This treatment also decreased cost of treatment by using the out-patient program which can typically be two to three dressing per week.

Nanocrystalline silver dressing is a broad spectrum and rapid antimicrobial protection⁽¹⁰⁻¹⁴⁾ and improves wound healing by (1) decreased exudate, purulence and wound surface bacterial loading^(15,16), (2) decreased neutrophilic inflammation⁽¹⁷⁾, (3) reduce local matrix metalloproteinases and enhanced cellular apoptosis⁽¹⁸⁻²⁰⁾, (4) promoted fibroblast proliferation⁽¹⁸⁾, (5) accelerated re-epithelialization⁽²¹⁾, and (6) provided moisture balance within the superficial wound⁽¹⁵⁾.

The combination of both methods should increase the success rate when evaluated by reduced treatment time. The next step, however, is a prospective

evaluation.

For limb salvage procedures, nanocrystalline silver dressing with or without vacuum assisted wound closure is an alternative choice for the surgeon and patient with the possibility of providing a good result. This option provides a simple method, decreased cost and time by avoiding the use of free flap or even pedicle flap, decreased morbidity of donor site, decreased hospital stay by using an out-patient treatment program and is compatible with complex medical problems. These are the advantages of this technique. There were no adverse effects and it was well accepted by patients.

Conclusion

The present study has provided preliminary evidence that nanocrystalline silver dressing with or without vacuum assisted wound closure is effective and safe for use on complex wounds. Further studies with larger numbers of patients and long-term follow-up are required to support these results and for them to remain an alternative treatment at our hospital.

Acknowledgement

The present study was supported by the Center of Cleft Lip-Cleft Palate and Craniofacial Deformities, Khon Kaen University, in Association with the Tawanchai 16 Project. The authors thank Professor James A Will for assistance with the English language presentation of the manuscript.

Potential conflicts of interest

None.

References

1. Mathes SJ, Nahai F. Flap selection, analysis of features, modifications, and applications. In: Mathes SJ, Nahai F, editors. Reconstructive surgery: principles, anatomy, technique. New York: Churchill Livingstone; 1997: 37-160.
2. Morykwas MJ, Argenta LC, Shelton-Brown EI, McGuirt W. Vacuumassisted closure: a new method for wound control and treatment: animal studies and basic foundation. *Ann Plast Surg* 1997; 38: 553-62.
3. DeFranzo AJ, Argenta LC, Marks MW, et al. The use of vacuum-assisted closure therapy for the treatment of lower-extremity wounds with exposed bone. *Plast Reconstr Surg* 2001; 108(5): 1184-91.
4. Gustillo RB, Mendoza RM, Williams DN. Problems in the management of type III (severe) open fractures: a new classification of type III open

- fractures. *J Trauma* 1984; 24: 742.
5. Robert RS, Weitzman AM, Tracey WJ, Freudigman P, et al. Simultaneous treatment of tibial bone and soft-tissue defects with the Ilizarov method. *J Orthop Trauma* 2006; 20(3): 194-202.
 6. Herscovici DJr, Sanders RW, Scaduto JM, Infante A, et al. Vacuumassisted wound closure (VAC therapy) for the management of patients with high-energy soft tissue injuries. *J Orthop Trauma* 2003; 17(10): 683-8.
 7. Dedmond BT, Kortesis B, Pungner K, Simpson J, et al. The use of negativepressure wound therapy (NPWT) in the temporary treatment of soft- tissue injuries associated with high-energy open tibial shaft fractures. *J Orthop Trauma* 2007; 21(1): 11-7.
 8. Heugel JR, Parks KS, Christie SS, Pulito JF, et al. Treatment of the exposed Achilles tendon using negative pressure wound therapy: a case report. *J Burn Care Rehab* 2002; 23(3): 167-71.
 9. Gallano RD, Mustoe TA. Wound care. In: Thorne CH, Beasley RN, Aston SJ, Bartlett SP, Gurntner GC, Spear SL, editors. *Grabb and Smith's plastic surgery*. 6th ed. Philadelphia: Lippincott Williams and Wilkins; 2007: 23-32.
 10. Percival SL, Bowler PG, Dolman J. Antimicrobial activity of silvercontaining dressings on wound microorganisms using an in vitro biofilm model. *Int Wound J* 2007; 4: 18691.
 11. Fong J, Wood F, Fowler B. A silver coated dressing reduces the incidence of early burn wound cellulitis and associated costs of inpatient treatment: comparative patient care audits. *Burns* 2005; 31: 562-7.
 12. Supp AP, Neely AN, Supp DM. Evaluation of cytotoxicity and antimicrobial activity of Acticoat burn dressing for management of microbial contamination in cultured skin substitutes grafted to athymic mice. *J Burn Care Rehab* 2005; 26: 238-46.
 13. Thomas S, McCubbin P. A comparison of the antimicrobial effects of four silver-containing dressings on three organisms. *J Wound Care* 2003; 12: 101-7.
 14. Yin HQ, Langford R, Burrell RE. Comparative evaluation of the antimicrobial activity of Acticoat antimicrobial barrier dressing. *J Burn Care Rehab* 1999; 20: 195-200.
 15. Sibbald RG, Browne AC, Coutts P, Queen D. Screening evaluation of anionized nanocrystalline silver dressing in chronic wound care. *Ostomy Wound Manage* 2001; 47: 38-43.
 16. Tredget EE, Shankowsky HA, Groeneveld A, Burrell R. A matchedpair, randomized study evaluating the efficacy and safety of Acticoat silver-coated dressing for the treatment of burn wounds. *J Burn Care Rehab* 1998; 19: 531-7.
 17. Sibbald RG, Contreras-Ruiz J, Coutts P, Fierheller M. Bacteriology, inflammation, and healing: a study of nanocrystallinesilver dressings in chronic venous leg ulcers. *Adv Skin Wound Care* 2007; 20: 549-58.
 18. Wright JB, Lam K, Buret AG, Olson ME. Early healing events in a porcine model of contaminated wounds: effects of nanocrystalline silver on matrix metalloproteinases, cell apoptosis, and healing. *Wound Repair and Regeneration* 2002; 10: 141-51.
 19. Bhol KC, Schechter PJ. Topical nanocrystalline silver cream suppresses inflammatory cytokines and induces apoptosis of inflammatory cells in a murine model of allergic contact dermatitis. *Br J Dermatol* 2005; 152: 1235-42.
 20. Bhol KC, Schechter PJ. Effects of nanocrystalline silver (NPI 32101) in a rat model of ulcerative colitis. *Dig Dis Sci* 2007; 52: 2732-42.
 21. Olson ME, Wright JB, Lam K. Healing of porcine donor sites covered with silver-coated dressings. *Eur J Surg* 2000; 166: 486-9

ผลของการรักษาด้วยวัสดุปิดแผลชนิดแผ่นโลหะเงินอนุภาคนาโน ในบาดแผลชนิดที่มีการสูญเสีย เนื้อเยื่อและมีกระดูกโผล่

กมลวรรณ เจนวิสิทธิ์, พลากร สุรกุลประภา, บวรศิลป์ เชาวนจีน

ภูมิหลัง: บาดแผลชนิดรุนแรงที่มีการโผล่ของเส้นเอ็น, ข้อต่อและกระดูกที่เกิดจากอุบัติเหตุต่างๆ จำเป็นต้องรักษาเพื่อให้สามารถใช้งานได้และมีความสวยงาม เพื่อเสริมสร้างซึ่งสามารถกระทำได้ด้วยวิธีการต่างๆ ที่หลากหลาย

วัตถุประสงค์: เพื่อนำเสนอประสบการณ์การรักษาด้วยการใช้วัสดุปิดแผลชนิดแผ่นโลหะเงินอนุภาคนาโน เพียงอย่างเดียวหรือใช้รวมกับการปิดแผลด้วยวิธีศัลยกรรมในบาดแผลที่มีการสูญเสียเนื้อเยื่อรุนแรงจนมีกระดูกข้อต่อหรือเส้นเอ็นโผล่

วัสดุและวิธีการ: เป็นการศึกษาผลของการรักษาในผู้ป่วยจำนวน 12 ราย 15 บาดแผล บริเวณขา โดยเป็นบาดแผลที่มีการโผล่ของอวัยวะต่างๆ ที่สำคัญดังได้กล่าวมาแล้ว หลังจากการกำจัดเนื้อตายและสิ่งสกปรกออก จะปิดแผลโดยใช้วัสดุปิดแผลชนิดแผ่นโลหะเงินอนุภาคนาโนเพียงอย่างเดียวหรือใช้รวมกับการปิดแผลด้วยวิธี ศัลยกรรม โดยผู้ป่วยจำนวน 10 ราย สามารถรักษาแบบผู้ป่วยนอกได้

ผลการศึกษา: ผลการรักษาในกลุ่มผู้ป่วยนําร่องเป็นที่น่าพอใจในเรื่องการลดการติดเชื้อของบาดแผลและการสร้าง เนื้อเยื่อขึ้นมาคลุมอวัยวะสำคัญต่างๆ ได้สำเร็จ โดยผู้ป่วยบางส่วนจำเป็นต้องได้รับการปลูกถ่ายผิวหนังเพิ่มเติม

สรุป: ผู้นิพนธ์ได้รายงานผลการรักษาที่เป็นที่น่าพอใจในบาดแผลชนิดรุนแรงที่มีการโผล่ของกระดูกด้วยทางเลือกใหม่
