

Robotic Assisted Laparoscopic Donor Nephrectomy: Early Experience in Ramathibodi Hospital

Supanut Lumbiganon MD***, Preamsant Sangkum MD*,
Suthep Patcharatrakul MD*, Sophon Jirasiritham MD***, Wisoot Khongcharoensombat MD*

* Division of Urology, Department of Surgery, Faculty of Medicine Ramathibodi Hospital, Mahidol University, Bangkok, Thailand

** Department of Surgery, Faculty of Medicine, Khon Kaen University, Khon Kaen, Thailand

*** Division of vascular and transplantation, Department of Surgery, Faculty of Medicine Ramathibodi Hospital, Mahidol University, Bangkok, Thailand

Background: Kidney transplantation is a standard treatment for end-stage renal disease. Living-donor kidney transplantation has gained popularity in the last few decades because of the lack of cadaveric donors available. Laparoscopic donor nephrectomy has become a standard method of kidney procurement in our institute, but there are some limitations on this approach, including its impracticality with right-sided kidneys and kidneys with multiple or complex vascular anatomies.

Objective: To report our experiences of robotic-assisted laparoscopic donor nephrectomy (RALDN), including the details of operation and the operative outcomes of RALDN, which may become a standard approach in the future.

Material and Method: Our institute has performed RALDN on two cases since 2015. Data including the donors' characteristics, the surgical techniques used, and operative outcomes were described.

Results: Two donors underwent RALDN. Both donated left kidneys had a single renal artery, renal vein, and ureter. The operative time were 4 hours, 55 minutes for the first case and 3 hours, 50 minutes for the second case. Operative blood losses for the first and second donor were 150 and 300 ml respectively, and neither donor received a blood transfusion. Warm ischemic time were 12 minutes for the first case and 4 minutes for the second case. There were no perioperative complications. The patients' hospital stays were 4 days for the first case and 5 days for the second case. There was no delayed graft function in either recipient.

Conclusion: RALDN is feasible and provides better visualization and more precise dissection than the pure laparoscopic approach. In the future, this approach may overtake standard laparoscopic technique for difficult donor nephrectomy cases.

Keywords: Kidney transplantation, Renal transplantation, Robotic-assisted laparoscopic donor nephrectomy, Robotic nephrectomy, donor nephrectomy

J Med Assoc Thai 2017; 100 (Suppl. 9): S184-S188

Full text. e-Journal: <http://www.jmatonline.com>

Kidney transplantation has long become a standard treatment for end-stage renal disease. In Thailand, approximately 4,700 patients were on the kidney transplant waiting list at the end of 2015, while during 2015, only 367 cadaveric transplantations and 234 living related kidney transplantations (LRKTs) were performed across the country⁽¹⁾. LRKTs have gained popularity because of their overall better graft function outcomes and the lack of cadaveric donors⁽²⁾.

Graft harvesting techniques change overtime.

Various methods of graft procurement have been described along with their outcomes, including the open, laparoscopic, hand-assisted laparoscopic, and single-port techniques^(3,4). At present, our institute performs laparoscopic donor nephrectomy as a standard procurement technique for left-side kidneys, whereas right-side kidneys and some kidneys with multiple or complex vascular anatomies are usually harvested by the open technique.

The emerging of robotic surgery has made a lot of changes in the field of surgery. The da Vinci Surgical System (Intuitive Surgical, Inc., Sunnyvale, CA) allowed surgeons to do more precise dissection and visualization, which can reduce the possibility of complications in any surgery. Robotic-assisted laparoscopic donor nephrectomy (RALDN) can be used

Correspondence to:

Khongcharoensombat W, Division of Urology, Department of Surgery, Ramathibodi Hospital, 270 Rama VI Road, Phayathai, Ratchathewi, Bangkok 10400, Thailand.

Phone: +66-2-2011315, Fax: +66-2-2011316

E-mail: Wisoot2002@hotmail.com

for more delicate donor nephrectomies, including those of the right kidney, which typically has a shorter renal vein that is difficult to manage with the pure laparoscopic approach. Cases with difficult or complex vascular anatomies may also benefit from the robot's precise dissection and visualization⁽⁵⁾.

Material and Method

In 2015, two kidney donors at our institute underwent RALDN. Both of them were given routine preoperative evaluations by the transplantation team, which also included nephrologists, vascular surgeons, and urologists. Both donors also underwent computed tomography arteriograms (CTA) of the renal artery as a standard evaluation. Donors' demographic data, the surgical techniques used, and the operative outcomes were described.

Results

The donors' demographic data are described in Table 1. Both donors underwent robotic-assisted left donor nephrectomy. Both kidneys had single renal arteries, veins, and collecting systems. The renal arteries and their branches were evaluated with CTA, as shown in Fig. 1.

The operative room, donor position, robot, surgeons' console, and assistant position were set up as in Fig. 2. The procedure was as follows for each operation:

After general anesthesia had been administered, the donor was placed on a 16 Fr Foley catheter. The pneumatic compression device was placed, and the donor was then turned to the right lateral decubitus position. The right hip was slightly flexed, while the right knee was also flexed. The left leg was straightened, with a pillow between both legs and

left ankle support. An axillary roll was placed beneath the right axillar, and both arms and forearms were placed on arm rest in front of the donor. The operating table was flexed at the level of the donor's umbilicus to facilitate exposure between the costal margin and the iliac crest. The abdomen was prepped and draped in a sterile fashion.

The first incision was made just at the right side lateral to the umbilicus. The open technique was used to enter the abdominal cavity. Pneumoperitoneum was created with 15 mmHg of CO₂ insufflation, and another three 8-mm robotic arm trocars were placed under direct vision as in Fig. 3. One assistant port was made just above the umbilicus. The left lower quadrant trocar was placed in the Gibson incision line to use for kidney extraction. The robot was docked, and its arms were equipped with monopolar scissors, Maryland bipolar forceps, and ProGrasp forceps (Intuitive Surgical, Sunnyvale, CA).

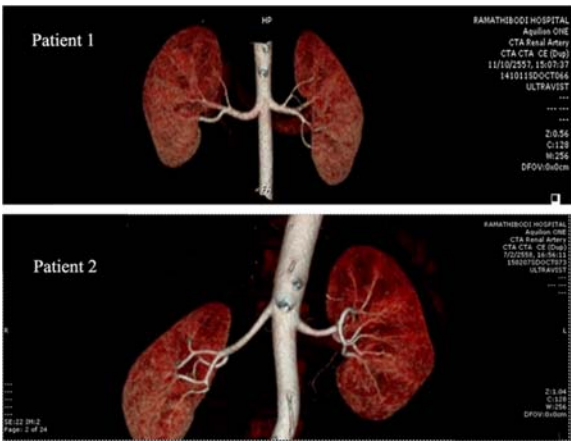

Fig. 1 Computed tomography arteriograms of both donors.

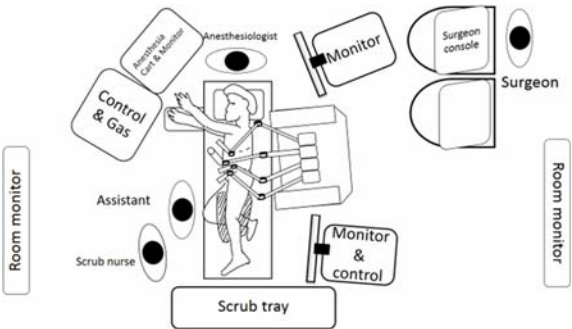


Fig. 2 Operating room set up in robotic assisted left donor nephrectomy.

Table 1. Demographic data of 2 donors

	Donor 1	Donor 2
Age (year)	21	44
Sex	Male	Female
Body weight (kg)	79.5	56.4
Height (cm)	170.7	154.6
Underlying disease	No	No
Medication	No	No
Relation with recipient	Son	Sister
Number of renal artery	1	1
Number of renal vein	1	1
Number of ureter	1	1

The dissection began with the mobilization of the descending colon from the peritoneal attachment. The ureter was then identified and freed from the surrounding tissue, with some periureteric tissue left intact. The ureter was considered long enough when the dissection passed over the iliac vessels. The dissection continued to the perirenal tissue. At this point, some of the posterior attachment was spared to prevent the kidney from flipping medially. Two techniques were used to identify the hilar vessels. In some cases, if the descending colon is mobilized medial enough, the renal vein outline may be visible or the hilar vessels may be approached by following the gonadal vein superiorly up to where it drains to the left renal vein. Renal vein tributaries, including the gonadal, adrenal, and lumbar veins, are identified and clipped with Hem-o-lok (Weck Closure Systems, Research Triangle Park, NC) and cut.

After the renal artery and vein had been clearly identified, the kidney was dissected free from all surrounding tissue, and the ureter was clipped with Hem-o-lok and cut. A left Gibson incision was then

made through the left lower quadrant port site, and the internal oblique muscle and peritoneum were spared to maintain pneumoperitoneum. After the incision was prepared and the kidney was freed from the surrounding tissue, two Hem-o-lok clips each were applied to the proximal renal artery and vein. Both vessels were then cut, and the kidney was put in a plastic bag. The robotic trocar at the Gibson incision was removed, and the incision was extended for the removal of the kidney, which was then transferred to the vascular surgeons for perfusion and further dissection. The Gibson incision was closed, and attention was returned to the intraperitoneal cavity for a final check for bleeding and a Jackson-Pratt drain placement. The robot was undocked, and all port sites were closed.

The operative time were 4 hours, 55 minutes for the first case and 3 hours, 50 minutes for the second case. Warm ischemic time were 12 minutes for the first case and 4 minutes for the second case. More operative details and outcomes are shown in Table 2.

After the operation, both donors recovered well and resumed liquid diets on the following day. No perioperative complication occurred. Both recipients did not had delayed graft function or perioperative complications.

Discussion

Our first two cases of robotic-assisted left donor nephrectomy demonstrated excellent outcomes in both donors and excellent graft function in the recipients.

Living-donor kidney transplantation has been associated with better graft survival than that seen with cadaveric transplants⁽⁶⁾. These data promoted the use of living kidney donation. The use of the laparoscopic approach has gained popularity among

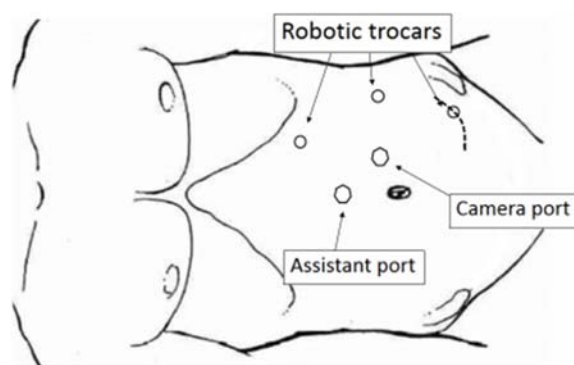


Fig. 3 Ports placement of robotic assisted left donor nephrectomy.

Table 2. Operative data of robotic assisted laparoscopic donor nephrectomy

	Donor 1	Donor 2
Operative time	4 hours 55 minutes	3 hours 50 minutes
Blood loss (ml)	150	300
Blood transfusion	No	No
Warm ischemic time (min)	12	4
Hospital stay (days)	4	5
Perioperative complication	No	No
Recipient delayed graft function	No	No
Preoperative GFR (Cr)	126.0 ml/hr (0.84 mg %)	88.3 ml/hr (0.81 mg %)
Postoperative GFR (Cr) at 6 months	88.7 ml/hr (1.07 mg %)	56.0 ml/hr (1.17 mg %)

potential donors and surgeons because of its improved recovery time, decreased number of wound complications, and reduction in analgesic use⁽⁷⁾.

The laparoscopic approach to donor nephrectomy still has some limitations. The renal vein of a right-sided kidney is usually short, and the stump at the inferior vena cava side is difficult to manage. In the case of kidneys with multiple hilar vessels, although some data show no differences in complications or graft function⁽⁸⁾, some surgeons feel more comfortable using the open approach rather than the laparoscopic one⁽⁹⁾.

The use of the da Vinci Surgical System may overcome those limitations. The system has a freedom grip that allows shaft rotation, in-and-out motion, and up-down and left-right movement at the tip (EndoWrist, Intuitive Surgical). It replaces large-scale hand movements with tiny instrument movements and provides reduced vibration and a three-dimensional view at the surgeons' console. These sophisticated features help surgeons perform more precise operations. Thus, donor nephrectomy, which requires meticulous dissection and careful tissue handling for the best possible graft function and transplant outcome, should benefit from this approach.

With more experience, the warm ischemic time can be reduced; this was seen in our second case, in which the time was comparable to those of other methods of procurement⁽³⁾ and other robotic-assisted procedures in the literature⁽⁵⁾. Although Xiaolong et al reported a small number of RALDNs with no significant benefit compared to the pure laparoscopic approach⁽¹⁰⁾, the robotic approach still has many advantages in cases of complex anatomy, and significant benefit may be seen as more cases are performed. We currently approach right-sided donor nephrectomy using the open method, but in selected cases in the near future, the robotic-assisted method could be an alternative one.

Conclusion

Our early experience in robotic donor nephrectomy demonstrates that the operation is safe and feasible and that it could assist in the performance of difficult donor nephrectomies. More cases are required to evaluate its outcomes, but this approach could become standard in the future.

What is already known on this topic?

These is our experience in the first 2 cases of robotic assisted donor nephrectomy. The outcomes are comparable to other studies in the literature.

What this study adds?

This study showed that RALDN is feasible and safe for kidney donation procedure. With the advantage of robotic surgery this could encourage the use of RALDN in more difficult cases especially right-side kidney donation which we did not routinely use minimally invasive technique before. As we are one of the biggest transplant center in Thailand, we try to use technology and improve our skill to make greater benefits for the patients.

Potential conflicts of interest

None.

References

1. Thai Transplantation Society. Annual report. Bangkok: Thai Transplantation Society; 2015.
2. Cecka JM. Living donor transplants. Clin Transpl 1995; 363-77.
3. Ungbhakorn P, Kongchareonsombat W, Leenanupan C, Kijvikai K, Wisetsingh W, Patcharatrakul S, et al. Comparative outcomes of open nephrectomy, hand-assisted laparoscopic nephrectomy, and full laparoscopic nephrectomy for living donors. Transplant Proc 2012; 44: 22-5.
4. Attawattayanon W, Prasit S, Sangkum P, Patcharatrakul S, Jirasiritham S, Khongcharoensombat W. Single port laparoscopic donor nephrectomy: first case report in Ramathibodi Hospital. J Med Assoc Thai 2014; 97: 250-4.
5. Horgan S, Benedetti E, Moser F. Robotically assisted donor nephrectomy for kidney transplantation. Am J Surg 2004; 188: 45S-51S.
6. USRDS 1994 Annual data report. Bethesda, MD: National Institutes of Health, National Institute of Diabetes and Digestive and Kidney Diseases; 1994.
7. Merlin TL, Scott DF, Rao MM, Wall DR, Francis DM, Bridgewater FH, et al. The safety and efficacy of laparoscopic live donor nephrectomy: a systematic review. Transplantation 2000; 70: 1659-66.
8. Swartz DE, Cho E, Flowers JL, Dunkin BJ, Ramey JR, Bartlett ST, et al. Laparoscopic right donor nephrectomy: technique and comparison with left nephrectomy. Surg Endosc 2001; 15: 1390-4.
9. Kuo PC, Cho ES, Flowers JL, Jacobs S, Bartlett ST, Johnson LB. Laparoscopic living donor nephrectomy and multiple renal arteries. Am J Surg 1998; 176: 559-63.

10. Liu XS, Narins HW, Maley WR, Frank AM, Lallas CD. Robotic-assistance does not enhance

standard laparoscopic technique for right-sided donor nephrectomy. JSLS 2012; 16: 202-7.

การผ่าตัดบริจาดไตโดยวิธีการผ่าตัดส่องกล้องโดยใช้หุ่นยนต์ช่วย: รายงานการผ่าตัด 2 รายแรกในโรงพยาบาลรามธิบดี

ศุภณัฐ ลุมพิกานนท์, เปรมสันต์ สังข์คุ้ม, สุเทพ พัทธตระกูล, โสภณ จิรศิริธรรม, วิสูตร คงเจริญสมบัติ

ภูมิหลัง: การปลูกถ่ายไตถือเป็นการรักษาโรคไตวายเรื้อรังที่เป็นมาตรฐานในปัจจุบัน การปลูกถ่ายไตโดยใช้ไตจากผู้บริจาคที่มีชีวิตได้รับความนิยมมากขึ้นเนื่องจากให้ผลการรักษาดีและไตจากผู้บริจาคที่เสียชีวิตแล้วมีจำนวนไม่เพียงพอต่อผู้รอรับบริจาค มีวิธีการผ่าตัดบริจาดไตหลายแบบในปัจจุบันที่โรงพยาบาลรามธิบดีใช้การผ่าตัดส่องกล้องสำหรับการผ่าตัดบริจาดไตซ้าย และการผ่าตัดแบบเปิดสำหรับการผ่าตัดบริจาดไตขวาเป็นมาตรฐาน จากวิวัฒนาการการใช้หุ่นยนต์ช่วยผ่าตัดที่ช่วยให้การผ่าตัดทำงานได้ละเอียดแม่นยำขึ้น จึงน่าจะมีประโยชน์ในการผ่าตัดที่ต้องการความละเอียดซับซ้อน เช่นการผ่าตัดบริจาดไต

วัตถุประสงค์: ผู้นิพนธ์มีความประสงค์จะรายงานการผ่าตัดบริจาดไตโดยใช้หุ่นยนต์ช่วย 2 รายแรกในโรงพยาบาลรามธิบดี

วัสดุและวิธีการ: โรงพยาบาลรามธิบดีได้ทำการผ่าตัดบริจาดไตโดยใช้หุ่นยนต์ช่วยจำนวนทั้งหมด 2 รายตั้งแต่ปี พ.ศ. 2558 มีการเก็บรวบรวมข้อมูลพื้นฐานของผู้บริจาคไต วิธีการและผลลัพธ์ของการผ่าตัด

ผลการศึกษา: ผู้บริจาคทั้ง 2 ราย บริจาดไตข้างซ้ายซึ่งมีเส้นเลือดแดงเส้นเลือดดำและหลอดเลือดอย่างละ 1 เส้น การผ่าตัดใช้เวลา 3 ชั่วโมง 50 นาที และ 4 ชั่วโมง 55 นาทีตามลำดับ มีการเสียเลือด 150 และ 300 ซีซี ในผู้บริจาครายที่ 1 และ 2 ตามลำดับ ระยะเวลาที่ไตขาดเลือดเท่ากับ 12 นาทีและ 2 นาทีในผู้ป่วยรายที่ 1 และ 2 ตามลำดับและไม่มีภาวะแทรกซ้อนจากการผ่าตัดบริจาดไตและไม่มีภาวะการกลับมาทำงานของไตในผู้รับ

สรุป: การผ่าตัดบริจาดไตผ่านกล้องโดยใช้หุ่นยนต์ช่วยผ่าตัดเป็นวิธีที่ปลอดภัยและให้ผลการผ่าตัดที่ดี น่าจะสามารถประยุกต์ใช้ในการผ่าตัดบริจาดไตที่ยากขึ้น เช่น การบริจาดไตข้างขวาและการบริจาดไตที่มีกายวิภาคของเส้นเลือดไปเลี้ยงไตมากกว่า 1 เส้นในอนาคต
