

# Posterior to Anterior Urethral Caliber Ratio of Pediatric Patients with or without Posterior Urethral Valve

Wit Viseshsindh MD\*, Chinnarat Hongyok MD\*\*,  
Ratanaporn Pornkul MD\*\*, Suphaneewan Jaovisidha MD\*\*, Umaporn Udomsubpayakul MD\*\*\*

\* Department of Surgery, Faculty of Medicine Ramathibodi Hospital, Bangkok, Thailand  
\*\* Department of Radiology, Faculty of Medicine Ramathibodi Hospital, Bangkok, Thailand,  
\*\*\* Department of Epidemiology, Faculty of Medicine Ramathibodi Hospital, Bangkok, Thailand

**Background:** Posterior urethral valve (PUV) is one of the serious causes of congenital bladder outlet obstruction in males. The pathological effects can present in varieties of occurrence and magnitude. Because of this variability, the urethral obstruction can cause diagnostic and management dilemmas. Diagnostic study of choice of posterior urethral valve is voiding cystourethrography (VCUG).

**Objective:** To demonstrate the posterior/anterior urethral caliber ratio that appears in voiding cystourethrography (VCUG) among the male pediatric patients with or without posterior urethral valve (PUV) for supporting diagnostic decision by imaging.

**Material and Method:** The study population consisted of male pediatric patients ( $\leq 15$  years of age) who underwent VCUG from January 1<sup>st</sup> 2007 to June 30<sup>th</sup> 2014. Exclusion criteria were patients who had inadequate study, unavailable films, incomplete data in medical or radiological record, and/or were unable to undergo cystoscopy due to certain circumstances. Measuring of the posterior (P)/anterior (A) urethral caliber ratio was done. The urethral caliber ratio was calculated by dividing the maximal posterior urethral diameter by the maximal anterior urethral diameter. For each P/A ratio, sensitivity and specificity were plotted as a function of cutoff criterion, receiver operating characteristic (ROC) curves were constructed, and the areas under the curve (AUC) were calculated.

**Results:** A total of 432 patients were retrospectively reviewed. The median age was 2.6 years (range 1 day to 14 years). Median in ratio of 18 patients with positive VCUG and cystoscopy findings for PUV was 3.2 (1.72 to 7.41). A total of 413 patients with no symptom suggestion for PUV and negative VCUG findings for PUV demonstrate median in ratio 1.07 (0.48 to 5.56). The AUC that calculated by ROC curve was 0.991. At cut-off ratio 2.0, the sensitivity, specificity and accuracy were 94.7%, 96.9% and 96.8% respectively. At cut-off ratio 2.5, the sensitivity, specificity and accuracy were 73.7%, 99.3% and 98.2% respectively. At cut-off ratio 3.0, the sensitivity, specificity and accuracy were 57.9%, 99.8% and 97.9% respectively.

**Conclusion:** The calculation of posterior/anterior urethral caliber ratio provides us with objective measurement for benefit in diagnostic decision by VCUG. Best cut-off for optimum sensitivity and specificity is probably a P/A ratio of 2.0. Best cut-off for high specificity is probably 2.5 or 3.0.

**Keywords:** Posterior urethral valve, Urethral caliber ratio, Congenital bladder outlet obstruction

*J Med Assoc Thai 2017; 100 (Suppl. 9): S189-S193*

*Full text. e-Journal: <http://www.jmatonline.com>*

Posterior urethral valve (PUV) is one of the serious causes of congenital bladder outlet obstruction in males<sup>(1)</sup>. This condition can appear in utero, in the neonate, later in childhood, or adults. The pathological

effects can present in varieties of occurrence and magnitude. Because of this variability, the urethral obstruction can cause diagnostic and management dilemmas<sup>(2)</sup>.

Diagnostic study of choice of posterior urethral valve is voiding cystourethrography (VCUG)<sup>(3)</sup>. VCUG was initiated from several decades ago and is generally practiced in children by general and pediatric radiologists<sup>(4)</sup>. Acquaintance with the pathologies and imaging techniques that improve visualization of disease results in the detection of most common

## Correspondence to:

Viseshsindh W, Division of Urology, Department of Surgery, Faculty of Medicine, Ramathibodi Hospital, Mahidol University 270 Rama VI Road, Phayathai, Ratchathewi, Bangkok 10400, Thailand.

Phone: +66-2-2011315, Fax: +66-2-2794704

E-mail: [earth@yahoo.com](mailto:earth@yahoo.com)

pathologies with very low radiation exposure<sup>(5-7)</sup>.

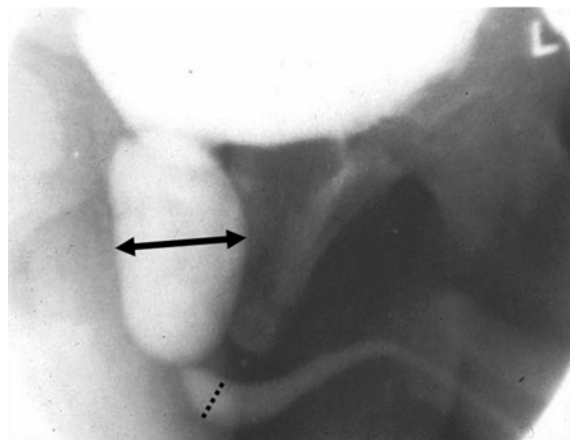
In patients with PUV, the posterior urethra shows fusiform dilatation which terminates abruptly at the level of the valve. In some cases, it occasionally shows filling defects in the stream of contrast medium, representing the evidence of valve cusps<sup>(2)</sup>.

There are few published reports of the urethral ratio of patients with and without PUV. There are studies of using the urethral ratio to follow the result after treatment<sup>(3,8,9)</sup>. However, the studies did not focus on diagnostic decision. Moreover, difference of experience among the image interpreters in general practice can cause variant and equivocation of the diagnosis in some cases.

The purpose of our study is to record the posterior/anterior urethral caliber ratio that appears in VCUG of male pediatric patients with and without PUV that will be beneficial for diagnostic decision of posterior urethral valve in VCUG.

#### Material and Method

The study population consisted of male pediatric patients ( $\leq 15$  years of age) who underwent VCUG from January 1<sup>st</sup> 2007 to June 30<sup>th</sup> 2014 at Ramathibodi Hospital, Mahidol University. We excluded the patients who had inadequate study, unavailable films, incomplete data in medical or radiological record, and/or were unable to undergo cystoscopy due to certain circumstances. The data were collected from medical records, VCUG findings, cystoscopy findings, and radiological reports. Data collection included demographic information (age, gender, study date and time), urethral ratio in VCUG, and cystoscopy results. The patients who were diagnosed of posterior urethral valve in VCUG would later undergo cystoscopy to confirm diagnosis and treatment. The measurement of the posterior/anterior urethral caliber ratio was done by single radiologist using the maximal anterior urethral diameter and the maximal posterior urethral diameter in oblique position of voiding phase images (Fig. 1). The radiologist used the measurement calibration in DICOM conformance (Synapse version 3.2.0, FUJIFILM Medical systems USA's Synapse® PACS System, USA). After the completion of the first round of measurement, another round had been done once again in the next month to calculate for the average value of both rounds. For each P/A ratio, sensitivity and specificity were plotted as a function of cutoff criterion, receiver operating characteristic (ROC) curves were constructed, and the areas under the curve (AUC) were calculated.



**Fig. 1** Measurement of the greatest maximal diameter of posterior (arrow) and anterior (dot) urethra in VCUG (picture from Ref 12).

The study has been approved by a research ethics committee.

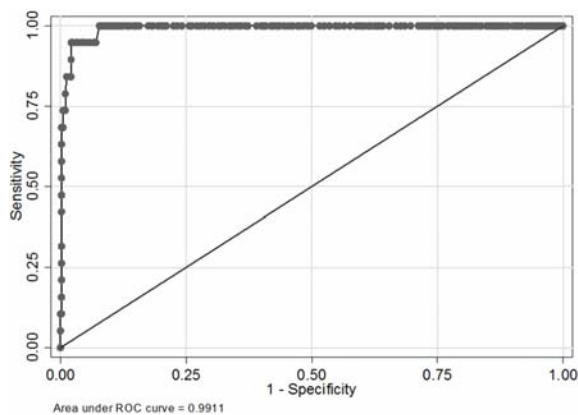
#### Results

From January 1<sup>st</sup> 2007 to June 30<sup>th</sup> 2014, 432 male pediatric patients underwent VCUG studies at Ramathibodi Hospital. The two rounds of urethral ratio measurement were interpreted by Bland-Altman method for intraobserver agreements, resulting good correlation with high Pearson's correlation coefficient (0.981) and average difference  $\pm$  SD at  $0.029 \pm 0.197$ . The 95% limit of agreement were between -0.358 and 0.415, which are acceptable for clinical situation. The median age was 2.6 years (range 1 day to 14 years). Median in ratio of 18 patients with positive VCUG and cystoscopy findings for PUV was 3.2 (1.72 to 7.41). A total of 413 patients with no symptom suggestion for PUV and negative VCUG findings for PUV demonstrate median in ratio 1.07 (0.48 to 5.56) (Table 1). The AUC that calculated by ROC curve was 0.991 (Fig. 2). At cut-off ratio 2.0, the sensitivity, specificity and accuracy were 94.7%, 96.9% and 96.8% respectively. At cut-off ratio 2.5, the sensitivity, specificity and accuracy were 73.7%, 99.3% and 98.2% respectively. At cut-off ratio 3.0, the sensitivity, specificity and accuracy were 57.9%, 99.8% and 97.9% respectively (Table 2). There is one patient who has positive VCUG that suggested PUV, posterior/anterior urethral caliber ratio was 6.67 but negative cystoscopy findings. This patient was diagnosed with Hinman syndrome or nonneurogenic neurogenic bladder, which is a functional bladder outlet obstruction produced by voluntary contraction of the external sphincter during voiding, causing distension

of the posterior urethra<sup>(10)</sup>.

## Discussion

Voiding cystourethrography (VCUG) is considered the diagnostic study of choice for the evaluation of posterior urethral valves. On voiding phase, the posterior urethra is dilated, and valve leaflets may be seen as lucencies. The anterior urethra is typically underfilled, and voiding is incomplete. VCUG



**Fig. 2** The receiver operating characteristic (ROC) curve. Area under the curve (AUC) is 0.991, standard error (SE) is 0.005 (non-parametric method, De Long et al, 1988), and the exact binomial 95% CI is 0.976 to 0.997.

is considered the diagnostic criterion standard imaging modality for posterior urethral valves, but normal mucosal folds (plicae colliculi) may appear as lucencies on VCUG and suggest the presence of valve leaflets. Intermittent voiding was observed in infants, which was characterized by interrupted voiding, and always associated with one or more abrupt increases in pelvic floor activity. There are alternating phases of contraction of the external urethral sphincter causing an interrupted urinary stream and slightly dilate posterior urethra show in video urodynamic study. Children with dysfunctional voiding often show abnormalities on VCUG. Dilatation of the prostatic urethra may be observed in boys<sup>(11)</sup>, and maybe confuse with posterior urethral valve. However, in a boy with the clinical presentation of a posterior valve in whom definitive visualization of the valve is absent, cystourethroscopy may be indicated to rule out urethral pathology.

Rahul K. Gupta et al<sup>(3)</sup> published study of using the urethral ratio to follow the result after treatment. The median urethral ratio in pre-fulguration group of the studies was 4.7. These ratios quite corresponded with our suggestion that is higher than 2.94. However, the mean and median urethral ratios in their control group were 1.73 ( $\pm 0.577$ ) and 1.5, which are slightly more than our studies. This difference might be due to different nationality in our research population. From the study published by Bani Hani O

**Table 1.** Age and A-P ratio for PUV and No PUV groups

Characteristics	No PUV (n = 413)	PUV (n = 19)	p-value*
Age (years):			
Mean (SD)	2.00 (2.93)	3.18 (3.13)	
Median (range)	0.67 (0.03 to 14)	1.58 (0.1 to 10)	0.045
A-P ratio:			
Mean (SD)	1.16 (0.41)	3.58 (1.47)	
Median (range)	1.07 (0.48 to 5.56)	3.2 (1.72 to 7.41)	<0.001

\* The p-value by Wilcoxon rank-sum test

**Table 2.** Cut-off points and sensitivity, specificity, and accuracy

Cut-off	Sensitivity (95% CI)	Specificity (95% CI)	Accuracy (95% CI)
1.5	100% (82.4% to 100%)	86.4% (82.8% to 89.6%)	87.0% (83.5% to 90.1%)
2.0	94.7% (74.0% to 99.9%)	96.9% (94.7% to 98.3%)	96.8% (94.6% to 98.2%)
2.5	73.7% (48.8% to 90.9%)	99.3% (97.9% to 99.8%)	98.2% (96.4% to 99.2%)
3.0	57.9% (33.5% to 79.7%)	99.8% (98.7% to 99.9%)	97.9% (96.1% to 99.0%)

et al<sup>(8)</sup>, the median urethral ratio of the preoperative group and control group were 8.6 and 2.6, respectively. These data still corresponded with our suggestion of ratio higher than 2.94.

The present study has several limitations. First, there were few cases that had adequate study and complete information, resulting in little data to process and analyze. Moreover, we could not retrospectively measure the urethral caliber in the absolute centimeters of many cases due to technical limitation of the fluoroscopic machine, especially in the early years.

### Conclusion

Posterior urethral valve is a serious cause of congenital bladder outlet obstruction in males and can present in varieties of occurrence and magnitude. Thus, good diagnostic decision is important. The calculation of posterior/anterior urethral caliber ratio provides us with objective measurement for benefit in diagnostic decision by VCUG. Best cut-off for optimum sensitivity and specificity is probably a P/A Ratio of 2.0. Best cut-off for high specificity is probably 2.5 or 3.0.

### What is already known on this topic?

Voiding cystourethrography (VCUG) is considered the diagnostic study of choice for the evaluation of posterior urethral valves. On voiding phase, the posterior urethra is dilated, and valve leaflets may be seen as lucencies on VCUG. The anterior urethra is typically underfilled, and voiding is incomplete. VCUG is considered the diagnostic criterion standard imaging modality for posterior urethral valves.

### What this study adds?

Children with dysfunctional voiding and no posterior urethral valve often show abnormalities on VCUG. Dilatation of the prostatic urethra may be observed in boys, and maybe confuse with posterior urethral valve. The present study show the calculation of posterior/anterior urethral caliber ratio provides us with objective measurement for benefit in diagnostic decision by VCUG.

### Acknowledgements

I heartily thank Panuwat Lertsithichai who encouraged and guided me for statistics. I offer my regards to all who supported me in any aspects during the completion of the project.

### Potential conflicts of interest

None.

### References

1. Glassberg KI, Hendren WH, Tanagho EA. Persistent ureteral dilatation following valve resection. *Dialog Pediatr Urol* 1982; 5: 1-8.
2. Macpherson RI, Leithiser RE, Gordon L, Turner WR. Posterior urethral valves: an update and review. *Radiographics* 1986; 6: 753-91.
3. Gupta RK, Shah HS, Jadhav V, Gupta A, Prakash A, Sanghvi B, et al. Urethral ratio on voiding cystourethrogram: a comparative method to assess success of posterior urethral valve ablation. *J Pediatr Urol* 2010; 6: 32-6.
4. Fernbach SK, Feinstein KA, Schmidt MB. Pediatric voiding cystourethrography: a pictorial guide. *Radiographics* 2000; 20: 155-68.
5. Lebowitz RL. The detection and characterization of vesicoureteral reflux in the child. *J Urol* 1992; 148: 1640-2.
6. Kleinman PK, Diamond DA, Karellas A, Spevak MR, Nimkin K, Belanger P. Tailored low-dose fluoroscopic voiding cystourethrography for the reevaluation of vesicoureteral reflux in girls. *AJR Am J Roentgenol* 1994; 162: 1151-4.
7. Lebovic S, Lebowitz R. Reducing patient dose in voiding cystourethrography. *Urol Radiol* 1980; 2: 103-7.
8. Bani HO, Prelog K, Smith GH. A method to assess posterior urethral valve ablation. *J Urol* 2006; 176: 303-5.
9. Menon P, Rao KL, Vijaymahantesh S, Kanojia RP, Samujh R, Batra YK, et al. Posterior urethral valves: Morphological normalization of posterior urethra after fulguration is a significant factor in prognosis. *J Indian Assoc Pediatr Surg* 2010; 15: 80-6.
10. Johnson JF 3rd, Hedden RJ, Piccolello ML, Wacksman J. Distention of the posterior urethra: association with nonneurogenic neurogenic bladder (Hinman syndrome). *Radiology* 1992; 185: 113-7.
11. Kibar Y, Demir E, Irkilata C, Ors O, Gok F, Dayanc M. Effect of biofeedback treatment on spinning top urethra in children with voiding dysfunction. *Urology* 2007; 70: 781-4.
12. Wiener JS, Gaca AM. Posterior urethral valve imaging [Internet]. c1994 [Updated 2015 Dec 8; cited 2017 Dec 26]. Available from: <https://emedicine.medscape.com/article/412226-overview>.

---

## การศึกษาสัดส่วนระหว่างขนาดของท่อปัสสาวะส่วนหลังและส่วนหน้าในผู้ป่วยที่มีและไม่มีภาวะล้นก้นบริเวณท่อปัสสาวะส่วนหลัง

วิทย์ วิเศษสินธุ์, ชินรัตน์ หงษ์หยก, รัตน์พร พรกุล, สุกนีนีวรรณ เขาวีวิชญ์, อุมพร อุดมทรัพย์กุล

**ภูมิหลัง:** ภาวะล้นก้นท่อปัสสาวะส่วนหลัง (posterior urethral valve) เป็นภาวะผิดปกติตั้งแต่กำเนิด ซึ่งมีการอุดตันของทางเดินปัสสาวะที่พบในเด็กชายเป็นภาวะที่สามารถมีความรุนแรงที่แตกต่างกันในผู้ป่วยแต่ละราย ทำให้บางครั้งเกิดปัญหาในการวินิจฉัยและการรักษา แพทย์สามารถทำการวินิจฉัยภาวะดังกล่าวโดยการใส่การฉีดสารทึบแสงเข้าไปในกระเพาะปัสสาวะแล้วให้ผู้ป่วยปัสสาวะออกมาเพื่อดูลักษณะของกระเพาะปัสสาวะท่อปัสสาวะ และดูว่าการไหลย้อนของสารทึบรังสีขึ้นไปหรือไม่ voiding cystourethrography (VCUG) ในการศึกษานี้จะเปรียบเทียบสัดส่วนระหว่างขนาดของท่อปัสสาวะส่วนหลังและส่วนหน้า ในผู้ป่วยที่มีและไม่มีภาวะล้นก้นบริเวณท่อปัสสาวะ

**วัตถุประสงค์:** การศึกษาเพื่อเปรียบเทียบสัดส่วนระหว่างขนาดของท่อปัสสาวะส่วนหลังและส่วนหน้าในผู้ป่วยที่มีและไม่มีภาวะล้นก้นบริเวณท่อปัสสาวะ เพื่อช่วยในการตัดสินใจการวินิจฉัยโรค

**วัสดุและวิธีการ:** ศึกษาในกลุ่มผู้ป่วยชายที่มีอายุน้อยกว่าหรือเท่ากับ 15 ปี ซึ่งได้รับการตรวจ VCUG โดยรวบรวมข้อมูลตั้งแต่ วันที่ 1 มกราคม พ.ศ. 2550 ถึง วันที่ 30 มิถุนายน พ.ศ. 2557 โดยจะวัดขนาดของท่อปัสสาวะส่วนหลังและส่วนหน้า และมาเปรียบเทียบสัดส่วน ระหว่างขนาดของท่อปัสสาวะส่วนหลังต่อส่วนหน้า การคำนวณหาสัดส่วนจะใช้ขนาดของท่อปัสสาวะส่วนหลังที่กว้างที่สุดหารด้วยขนาดของท่อปัสสาวะ ส่วนหน้าที่กว้างที่สุด หลังจากนั้นจะนำเอาผลที่ได้มาสร้าง receiver operating characteristic (ROC) และคำนวณหา area under the curve (AUC), sensitivity และ specificity

**ผลการศึกษา:** ทำการศึกษาในผู้ป่วยทั้งหมด 432 คน อายุเฉลี่ย 2.6 ปี ค่ามัธยฐาน (median) สัดส่วนระหว่างขนาดของท่อปัสสาวะส่วนหลัง ต่อส่วนหน้าของผู้ป่วย 18 คน ที่มีภาวะล้นก้นบริเวณท่อปัสสาวะส่วนหลัง ซึ่งยืนยันจากการส่องกล้องทางเดินปัสสาวะ (cystoscopy) เท่ากับ 3.2 (1.72 ถึง 7.41) ส่วนในผู้ป่วยที่ไม่มีภาวะล้นก้นบริเวณท่อปัสสาวะส่วนหลังที่ค่าเท่ากับ 1.07 (0.48 ถึง 5.56) โดยที่สัดส่วน 2.0 จะมีค่า sensitivity, specificity และ accuracy อยู่ที่ 94.7%, 96.9% และ 96.8% ตามลำดับ ที่สัดส่วน 2.5 จะมีค่า sensitivity, specificity และ accuracy อยู่ที่ 73.7%, 99.3% และ 98.2% ตามลำดับ และที่สัดส่วน 3.0 จะมีค่า sensitivity, specificity และ accuracy อยู่ที่ 57.9%, 99.8% และ 97.9% ตามลำดับ

**สรุป:** ภาวะล้นก้นท่อปัสสาวะส่วนหลัง เป็นความผิดปกติที่พบได้ตั้งแต่กำเนิดและความรุนแรงค่อนข้างมาก การให้การวินิจฉัยที่ถูกต้องแม่นยำจะนำไปสู่การรักษาที่เหมาะสม การใช้สัดส่วน ระหว่างขนาดของท่อปัสสาวะส่วนหลัง ต่อส่วนหน้า สามารถเพิ่มความแม่นยำในการตรวจ VCUG ได้ดีขึ้น โดยสัดส่วนที่ 2.0 จะให้ค่า sensitivity และ specificity ที่เหมาะสม ส่วนสัดส่วน 2.5 และ 3.0 จะให้ค่า specificity สูงขึ้น

---