

Evaluating Upper Lip and Nose Changes after Alveolar Bone Grafting in Unilateral Cleft Lip and Palate Patients Using 3D Stereophotogrammetry

Atchariyaporn Ranchan DDS*,
Poonsak Pisek DDS, MS, FRCDT*, Supaporn Kongsomboon DDS, FRCST**

* Department of Orthodontics, Faculty of Dentistry, Khon Kaen University, Khon Kaen, Thailand

** Department of Oral and Maxillofacial Surgery, Faculty of Dentistry, Khon Kaen University, Khon Kaen, Thailand

Objective: To evaluate any three-dimensional (3D) changes to upper lip and nose morphology after bone grafting in unilateral complete cleft lip and palate patients.

Material and Method: 3D facial images of 10 male and 11 female subjects were taken before and 3 months after alveolar bone grafting. Locations of 13 upper lip and nose landmarks were set on the 3D images, and their positions were measured as X, Y, and Z, coordinating by Morpheus 3D Facemaker® software. Changes in coordinate measurements were checked following grafting. Statistical analysis was performed with paired t-test ($p < 0.05$).

Results: There were no changes between before and after grafting in position of landmarks for X-coordinate. There were statistically significant, although not large changes, of labiale superius, vertically (Y-coordinate 0.78 ± 2.57 mm) and anteriorly (Z-coordinate 0.31 ± 0.67 mm); and subalar anteriorly on the operative side (Z-coordinate 1.31 ± 1.63 mm).

Conclusion: Morphology of the upper lip and nose appeared to be minimally improved by bone grafting. There were possible confounding factors of variabilities of the subjects. Thus, conclusions about possible absence of substantial esthetic benefits of grafting on upper lip and nose morphology remain uncertain.

Keywords: Alveolar bone graft, Unilateral cleft lip and palate, Upper lip and nose morphology, 3D facial image

J Med Assoc Thai 2017; 100 (Suppl. 6): S30-S37

Full text. e-Journal: <http://www.jmatonline.com>

Bone grafting is an essential surgical procedure for management of residual alveolar cleft in cleft lip and palate patients after their primary surgery. The objectives of alveolar bone grafting include, providing continuity to the maxillary alveolar arch, providing bone matrix for erupting teeth in the line of the cleft site, closure of any oro-nasal fistula, promoting periodontal health with keratinized gingiva of adjacent teeth, improving speech, restoring facial symmetry and providing alar base and lip support^(1,2).

Previous studies^(2,3) have reported that alveolar bone grafting can reduce nasal asymmetry, raise and support a collapsed alar base and nostril, and produce better esthetic and functional outcomes with respect to lip and nose. Kim et al⁽⁴⁾ investigated change in upper lip height and nostril sill after alveolar bone grafting using standard photography. They found the

height of the upper lip was elongated after alveolar bone grafting in unilateral cleft lip and alveolus. Devin et al⁽⁵⁾ found bone grafting in patients with unilateral cleft lip and palate (UCLP) had improvement in nasal symmetry. Krimmel et al⁽⁶⁾ studied upper lip and nose changes after cleft alveolar bone grafting using 3D photogrammetry and found that no changes were detected for the position of the labial landmarks. There have been several studies reporting 3D stereophotogrammetry as an excellent tool to detect and quantify changes in facial morphology⁽⁶⁻⁹⁾, so the present study aimed to examine changes that might be expected to upper lip and nose morphology after alveolar bone grafting using 3D stereophotogrammetry.

Material and Method

Study population

The study population of this prospective clinical study consisted of 21 unilateral complete cleft lip and palate patients attending the Tawanchai Cleft Center of the Faculty of Medicine, Khon Kaen University who were ready for, and then completed,

Correspondence to:

Pisek P, Department of Orthodontics, Faculty of Dentistry, Khon Kaen University, Khon Kaen 40002, Thailand.

Phone & Fax: +66-43-202863

E-mail: poonsakpisek@yahoo.com

alveolar bone grafting, followed by a post-operative evaluation by an orthodontist and oral and maxillofacial surgeon during July 2016 to December 2016. The mean age at the time of alveolar bone grafting was 13.43 years (ranged 8 to 25 years). Patients with a systemic disease which interferes with bone resorption, craniofacial malformations or other syndromes were excluded from the study. Patients who had received corrective rhinoplasties or lip-nose revision were also omitted. All cases in this present study received pre-surgical orthodontic treatment. The average width of the cleft site before the surgery was 6.43 ± 3.39 mm. The bone volume average was 3.62 ± 1.48 ml. There was no complication among the 21 participating patients following the bone grafting. The participant demographics were summarized in Table 1.

Table 1. Participant demographics

Demographic data	Unilateral complete cleft lip and palate patients (n = 21)
Age range (Mean \pm SD)	8-25 (13.43 \pm 4.15)
Gender, n (%)	
- Males	10 (47.6)
- Females	11 (52.4)
Site of defect, n (%)	
- Right	8 (38.1)
- Left	13 (61.9)

Data collection

All participating patients had pre- and post-operative three dimensional surface images taken by the Morpheus 3D scanner 2 to 3 hours before and 3 months after alveolar bone grafting.

Measurement tools

Imaging methods

The tools used to create 3D facial photographs of the patients were a 3D optical scanning system (Morpheus 3D; Morpheus Co, Gyeonggi, Korea) combined with Facemaker® computer software (Facemaker, Morpheus). This system used a 3D digital facial scanner. For each patient, three photographs were taken, from the front, and 45 degrees to the left and right with lips relaxed and head in a natural head position and relaxed facial muscles. Then the set of three images corresponding to these views were reconstructed into one 3D image using a registration process.

Landmark identification as 3D coordinate values

The positions of 13 landmarks were manually set on the pre- and post-operative 3D facial soft tissue images (Table 2, Fig. 1). The Morpheus 3D Facemaker® software calculated and stored coordinate measurements, “x”, “y”, and “z”, for the observer-established landmark locations. This process was repeated on a second 3D facial image produced at a

Table 2. Definition of examined landmarks of upper lip and nose according to Farkas^(10,11)

Point	Landmarks	Definition
	Interpupillary line	An imaginary horizontal line drawn between the centers of the pupils of the eyes
Pn	Pronasale	Most protruded point of apex nasi
Sn	Subnasale	Midpoint of angle at columella point base
AlR	Right alare	The most lateral point on right alar contour
AlL	Left alare	The most lateral point on left alar contour
SbalR	Right subalar	Labial insertion point of right alar base
SbalL	Left subalar	Labial insertion point of left alar base
A'	Soft tissue A	Most concave point on the curve between the upper lip and subnasale
Ls	Labiale superius	Midpoint of upper vermillion line
ULP	Upper lip point	Midpoint of the upper lip
ChR	Right cheilion	The point located at right labial commissure
ChL	Left cheilion	The point located at left labial commissure
CphR	Right crista philtri	The point on right elevated margin of the philtrum just above the vermillion line.
CphL	Left crista philtri	The point on left elevated margin of the philtrum just above the vermillion line.

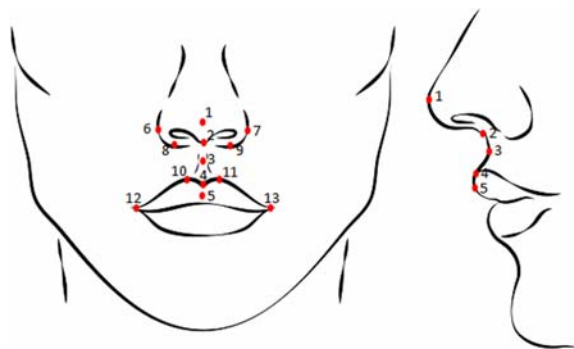


Fig. 1 Location of examined upper lip and nose landmarks. (1 = Pn, pronasale; 2 = Sn, subnasale; 3 = A', soft tissue A; 4 = Ls, labiale superius; 5 = ULP, upper lip point; 6 = ALR, right alare; 7 = ALL, left alare; 8 = SbalR, right subalar; 9 = SbalL, left subalar; 10 = CphR, right crista philtri; 11 = CphL, left crista philtri; 12 = ChR, right cheilion; 13 = ChL, left cheilion).

planned later time to test for the amount and direction of any changes in coordinate measurements of landmarks locations, recorded as follows:

“x” (left positive [+] and right negative [-]);
 “y” (superiorly positive [+] and inferiorly negative [-]); and
 “z” (anteriorly positive [+] and posteriorly negative [-]).

Outcomes and measurements

Both pre and post-operative three-dimensional (3D) surface images were defined with total 13 landmarks located for analysis by one orthodontist. Each landmark location was measured and recorded in 3D coordinate values (x, y, and z coordinates) by Morpheus 3D.

Facemaker® software. The three-dimensional changes of each landmark locations of the upper lip and nose were compared between pre- and post-operative images.

The reproducibility of intra-examiner landmark identification was assessed. All landmark locations of 6 randomly selected subjects were assessed by the same examiner repeated after 1 month. The errors were presented as the differences between first and repeat measurements for each landmark location as determined by the Morpheus software⁽¹²⁾.

Statistical analyses

The changes of soft tissue landmarks of upper lip and nose between pre- and post-operative three dimensional surface images were compared by paired

t-test. Statistical analysis was performed with the Statistical Package for the SPSS version 20.0 for Windows (IBM Corp. Chicaco, IL, USA). Differences were considered with *p*-value, mean and 95% confidence limit (CL). The Bland–Altman Limits of Agreement method^(13,14) was used to evaluate the reproducibility of intra-examiner landmark identification. The differences between first and repeat measurements for each landmark location were interpreted according to Toma et al⁽¹²⁾.

This research project received approval from the Ethics Committee on Human Research, Khon Kaen University (HE592131).

Results

The reproducibility of landmark locations

The Morpheus Facemaker® software was used to test the accuracy of positioning of 26 (counting right and left) upper lip and nose landmarks on both pre- and post-operative three-dimensional surface images with the same results. The reproducibility of intra-examiner landmark positioning was assessed using the Bland-Altman Limits of Agreement (LoA) method^(13,14) on 6 randomly selected subjects following the LoA assessment method of Toma et al⁽¹²⁾; the strength of reproducibility levels ranged from high to poor. In the present study, the majority⁽¹⁷⁾ of landmarks (17 landmarks, 65%) were of moderate reproducibility (0.5 to 1.0 mm error). The right cheilion pre-operative landmark was a highly reproducible landmark (<0.5 mm error) while the poorly reproducible landmarks (>1.0 to <2.0 mm error) was consisted of 8 landmarks (31%).

Change of upper lip and nose soft tissue landmark locations between pre- and post-operative three dimensional surface images

The three-dimensional changes of landmark locations of the upper lip and nose comparing before and after alveolar bone grafting are shown in Table 3.

To determine the changes of bilateral landmarks (alare, crista philtri, cheilion, and subalar), the comparisons between the operative and non-operative sides are displayed in Table 4.

Discussion

This present study used 3D stereophotogrammetry for capturing 3D surface images and quantify changes in facial morphology. It has been shown that the accuracy of linear measurements obtained by 3D stereophotogrammetry higher than those obtained using direct anthropometric

Table 3. Measured changes of 3D coordinate location for each mid-sagittal landmark of the 21 participating subjects before and after alveolar bone grafting

Coordinate		Landmarks				
		Pn	Sn	A'	ULP	Ls
X	Mean±SD (mm) ^a	0.16±1.30	-0.14±1.43	-0.01±1.47	0.33±1.65	-1.6±10.82
	95 % CL	-0.27, 0.59	-0.79, 0.51	-0.67, 0.67	-0.42, 1.08	-5.22, 2.00
	p-value	0.413	0.660	0.995	0.255	0.718
Y	Mean±SD (mm) ^a	-0.07±1.17	0.06±1.35	0.12±1.42	0.24±1.78	0.78±2.57
	95 % CL	-0.46, 0.32	-0.55, 0.67	-0.53, 0.77	-0.57, 1.05	-0.07, 1.64
	p-value	0.704	0.842	0.063	0.823	0.026*
Z	Mean±SD (mm) ^a	-0.18±1.17	-0.55±1.91	-0.21±1.34	0.31±1.53	0.31±0.67
	95 % CL	-0.57, 0.21	-1.42, 0.32	-0.82, 0.40	-0.39, 1.00	-0.75, 0.79
	p-value	0.415	0.203	0.391	0.664	0.050*

^a Paired t-test was performed. X-coordinate indicates left-right axis (+ = left, - = right); Y-coordinate, vertical axis (+ = superior, - = inferior); Z-coordinate, anteroposterior axis (+ = anterior, - = posterior); SD, standard deviation; CL, confidence limits.

*Significance: $p < 0.05$

Table 4. Measured changes of 3D coordinate location for each bilateral landmark (operative vs non-operative sides) of 21 participating subjects before and after alveolar bone grafting

Coordinate			Landmarks			
			Al	Cph	Ch	Sbal
X	Operativeside	Mean±SD (mm) ^a	0.04±1.60	0.24±1.62	-0.16±1.36	1.39±6.28
		95 % CL	-0.76, 0.69	-0.98, 0.50	-0.46, 0.78	-0.64, 0.53
		p-value	0.921	0.503	0.601	0.323
	Non- Operativeside	Mean±SD (mm) ^a	-0.15±0.61	0.23±1.61	-0.09±1.41	0.02±1.31
		95 % CL	0.12, 1.14	-0.96, 0.50	-0.57, 0.74	-0.61, 0.56
		p-value	0.259	0.512	0.760	0.614
Y	Operativeside	Mean±SD (mm) ^a	-0.19±1.57	0.27±1.23	0.12±.86	1.39±6.28
		95 % CL	-0.52, 0.91	-0.83, 0.29	-0.51, 0.27	-0.16, 1.07
		p-value	0.573	0.329	0.411	0.339
	Non- Operativeside	Mean±SD (mm) ^a	-0.78±2.14	0.33±1.32	0.17±1.08	-0.58±2.00
		95 % CL	-0.20, 1.76	-0.93, 0.27	-0.60, 0.39	-0.37, 0.80
		p-value	0.297	0.269	0.837	0.455
Z	Operativeside	Mean±SD (mm) ^a	-0.50±2.69	0.31±1.06	-0.73±29.60	1.31±1.63
		95 % CL	-0.73, 1.73	-0.79, 0.17	-0.37, 0.70	0.57, 2.05
		p-value	0.073	195	0.911	0.001*
	Non- Operativeside	Mean±SD (mm) ^a	-0.08±2.22	0.68±1.37	0.28±1.65	-0.50±1.38
		95 % CL	-0.93, 1.10	-1.30, -0.06	-1.03, 0.47	-0.12, 1.13
		p-value	0.865	0.085	0.476	0.175

^aPaired t-test was performed. X-coordinate indicates left-right axis (+ = left, - = right); Y-coordinate, vertical axis (+ = superior, - = inferior); Z-coordinate, anteroposterior axis (+ = anterior, - = posterior); SD, standard deviation; CL, Confidence limits

*Significance: $p < 0.05$

measurements and 2D photography from previous study. Kim et al⁽⁴⁾ defined accuracy and precision of a series of standard linear facial measurements comparing measurement values between direct anthropometry and

the Morpheus 3D system. The results indicate that the linear measurements obtained using the Morpheus 3D scanner had high levels of precision and a fairly good accordance with traditional anthropometry.

Under the conditions of this present study, the comparisons of 3D pre- and post-operative images demonstrated that the upper lip and nose were minimally affected by the bone-grafting. For mid-sagittal landmarks, no significant difference between before and after grafting was found in the position of any landmark on the X-coordinate. There were significant, although, small changes of landmarks, labiale superius, on both vertical and anteroposterior planes (Ls, 0.78 ± 2.57 mm on Y-coordinate; Ls, 0.31 ± 0.67 mm on Z-coordinate). These changes are similar to those reported by Kim et al⁽⁴⁾ who found elongated upper lip after alveolar bone grafting in contrast to the findings of Krimmel et al⁽⁶⁾ who found no change of the landmarks on upper lip. These different findings could be attributed to different morphological characteristics of the respective ethnic populations from which the patients with clefts were drawn, and differences in methods of primary surgical closure of the lip and also differences in surgical techniques for alveolar bone-grafting.

Comparing the changes of bilateral landmarks on operative and non-operative sides, there was a significant change of the landmark Z-coordinate measurements of the subalar base (Sbal) on the operative side which was more anteriorly projected (1.31 ± 1.63 mm). This agreed with the findings of Wu et al⁽¹⁵⁾ and Krimmel et al⁽⁶⁾. Kau et al⁽¹⁶⁾ found the ala and alar base on the affected side were slightly more protruded in anteroposterior following secondary bone-grafting. However, Li et al⁽¹⁷⁾ reported that the effect of alveolar bone-grafting was localized to the alar base, noting that the soft tissue defect was camouflaged by subsequent rhinoplasty so they suggested that the alveolar bone graft would be performed for functional benefits rather than esthetic benefits. On the other hand, Sander et al⁽¹⁸⁾ found no long-term effect of alveolar bone-grafting on nasal morphology, symmetry, and shape. It is likely that the condition of the already repaired lip will have a restricting effect on the volume of the healing graft is limited to varied degree of the changes in lip form.

Many factors appear to have direct impact on the changes of upper lip and nose after alveolar bone-grafting^(4,6). The residual swelling after grafting may create the illusion of an improvement of upper lip and nose soft tissue, especially when the time between pre-

and post-operative assessment is short. Krimmel et al⁽⁶⁾ found that increase in anterior projection of non-operative sides was caused by persistent swelling for 6 weeks after alveolar bone-grafting. The timing of restarting of orthodontic treatment will be influenced by the amount of soft tissue swelling and pain following the graft, despite the fact that tooth movement is possible within 1 to 2 weeks of grafting⁽¹⁹⁾. However, to eliminate the effect of persistent swelling after the surgery and to reduce the effect of orthodontic tooth movement on changes to the upper lip and nose, this observation period was extended to 12 weeks.

Continuing growth potential of young patients is another factor that affects upper lip and nose changes. The naso-maxillary and lip growth among UCLP patients are highly variable, but often deficient and also dependent on the type of, and whether or not there was any, treatment provided before primary surgery⁽²⁰⁾.

In the present study, using the 3D images taken by the Morpheus system for manually setting landmark locations on upper lip and nose was difficult. Most of the poor reproducible landmarks were associated with the nose. The left and right alare and pronasale were placed on gently curving slopes that may affect consistent positional setting of certain landmarks. This corresponds to previous studies^(12,21) that reported poor reproducibility of alare which might be a consequence of the broad contours of the nose at these landmark locations. Left crista philtri was another landmark showing poor reproducibility because this landmark is placed on the ill-defined border of scar tissue repair of the cleft lip. Landmarks placed on well-defined borders or edges have been found to have good reproducibility^(12,21,22). In the present study, there was moderate reproducibility of landmarks that were near the mouth (subalar, labiale superius, soft tissue A, cheilion and upper lip point) as also reported by Baysala et al⁽²³⁾. These landmarks were easy to determine visually. However, Toma et al⁽¹²⁾ concluded that the moderate reproducibility between 0.5 and 1.0 mm was clinically acceptable.

As already noted, there was difficulty in achieving high consistency in setting landmark positions on pre- and post-grafting 3D facial images. This would have had some adverse effects on accuracy of recording any change in nose and lip morphology as a result of bone-grafting. This limitation suggests transfer from coordinate measurements used in this present study to equally satisfactory measurement accuracy and better visualization of any change is now possible with dedicated software computing for

superimposition of digital 3D facial images made before- and after-grafting.

Conclusion

The present study found that morphology of the upper lip and nose appeared to be minimally improved by alveolar bone-grafting. There was moderate difficulty in consistent setting landmark positions on pre- and post-grafting 3D facial images in this present study that is likely to have affected accuracy in comparisons of the measurements. In addition, this group of UCLP subjects lacked uniformity, with possible confounding variables of growth status, gender, dento-skeletal relationships, and existing states of previous surgical repair of the UCLP. Thus, conclusions about possible absence of substantial esthetic benefits of grafting on upper lip and nose morphology remain uncertain. Nevertheless, there was agreement with studies by other observers. More definitive answers to questions of the extent of any esthetic benefits of bone-grafting may be possible if variability among subjects can be minimized.

What is already known on this topic?

Previous studies have reported that alveolar bone-grafting can reduce nasal asymmetry, raise and support a collapsed alar base and nostril, and produce better aesthetic and functional outcomes with respect to lip and nose.

What this study adds?

On 3D stereophotogrammetry coordinate measurements, the morphology of the upper lip and nose appeared to be minimally improved by alveolar bone-grafting. However, the 3D image superimposition process includes provision of color-coded measurements of morphological changes may provide sufficient accuracy and better visualization of any change^(24,25).

Acknowledgements

The authors would like to express our sincere gratitude to Associate Professor Keith Godfrey for his support and guidance. Also thanks to the Faculty of Dentistry and the Center of Cleft Lip-Cleft Palate and Craniofacial Deformities, Khon Kaen University under the Tawanchai Royal Grant Project for their valuable support in the present study.

Potential conflicts of interest

None.

References

1. Bajaj AK, Wongworawat AA, Punjabi A. Management of alveolar clefts. *J Craniofac Surg* 2003; 14: 840-6.
2. Bergland O, Semb G, Abyholm FE. Elimination of the residual alveolar cleft by secondary bone grafting and subsequent orthodontic treatment. *Cleft Palate J* 1986; 23: 175-205.
3. Craven C, Cole P, Hollier LJr, Stal S. Ensuring success in alveolar bone grafting: a three-dimensional approach. *J Craniofac Surg* 2007; 18: 855-9.
4. Kim SW, Park SO, Choi TH, Hai do T. Change in upper lip height and nostril sill after alveolar bone grafting in unilateral cleft lip alveolus patients. *J Plast Reconstr Aesthet Surg* 2012; 65: 558-63.
5. Devlin MF, Ray A, Raine P, Bowman A, Ayoub AF. Facial symmetry in unilateral cleft lip and palate following alar base augmentation with bone graft: a three-dimensional assessment. *Cleft Palate Craniofac J* 2007; 44: 391-5.
6. Krimmel M, Schuck N, Bacher M, Reinert S. Facial surface changes after cleft alveolar bone grafting. *J Oral Maxillofac Surg* 2011; 69: 80-3.
7. Ras F, Habets LL, van Ginkel FC, Prahl-Andersen B. Quantification of facial morphology using stereophotogrammetry-demonstration of a new concept. *J Dent* 1996; 24: 369-74.
8. Weinberg SM, Naidoo S, Govier DP, Martin RA, Kane AA, Marazita ML. Anthropometric precision and accuracy of digital three-dimensional photogrammetry: comparing the Genex and 3dMD imaging systems with one another and with direct anthropometry. *J Craniofac Surg* 2006; 17: 477-83.
9. Weinberg SM, Scott NM, Neiswanger K, Brandon CA, Marazita ML. Digital three-dimensional photogrammetry: evaluation of anthropometric precision and accuracy using a Genex 3D camera system. *Cleft Palate Craniofac J* 2004; 41: 507-18.
10. Farkas LG, Hajnis K, Posnick JC. Anthropometric and anthroposcopic findings of the nasal and facial region in cleft patients before and after primary lip and palate repair. *Cleft Palate Craniofac J* 1993; 30: 1-12.
11. Farkas LG, Lindsay WK. Morphology of adult face after repair of isolated cleft palate in childhood. *Cleft Palate J* 1972; 9: 132-42.
12. Toma AM, Zhurov A, Playle R, Ong E, Richmond S. Reproducibility of facial soft tissue landmarks on 3D laser-scanned facial images. *Orthod Craniofac Res* 2009; 12: 33-42.

13. Bland JM, Altman DG. Statistical methods for assessing agreement between two methods of clinical measurement. *Lancet* 1986; 1: 307-10.
14. Bland JM, Altman DG. Applying the right statistics: analyses of measurement studies. *Ultrasound Obstet Gynecol* 2003; 22: 85-93.
15. Wu Y, Wang G, Yang Y, Zhang Y. Influence of alveolar-bone grafting on the nasal profile: unilateral cleft lips, alveoli, and palates. *J Craniofac Surg* 2010; 21: 1904-7.
16. Kau CH, Medina L, English JD, Xia J, Gateno J, Teichgraber J. A comparison between landmark and surface shape measurements in a sample of cleft lip and palate patients after secondary alveolar bone grafting. *Orthodontics (Chic)* 2011; 12: 188-95.
17. Li J, Shi B, Liu K, Zheng Q, Wang Y, Li S. A photogrammetric study of the effects of alveolar bone graft on nose symmetry among unilateral cleft patients. *J Plast Reconstr Aesthet Surg* 2011; 64: 1436-43.
18. Sander M, Daskalogiannakis J, Tompson B, Forrest C. Effect of alveolar bone grafting on nasal morphology, symmetry, and nostril shape of patients with unilateral cleft lip and palate. *Cleft Palate Craniofac J* 2011; 48: 20-7.
19. Liou EJ, Chen PK, Huang CS, Chen YR. Interdental distraction osteogenesis and rapid orthodontic tooth movement: a novel approach to approximate a wide alveolar cleft or bony defect. *Plast Reconstr Surg* 2000; 105: 1262-72.
20. Kornbluth M. An inter-center comparison of dental arch relationships, craniofacial form, and nasolabial esthetics in patients with complete unilateral cleft lip and palate treated with different pre-surgical infant protocols [thesis]. Toronto, ON: University of Toronto; 2016.
21. Gwilliam JR, Cunningham SJ, Hutton T. Reproducibility of soft tissue landmarks on three-dimensional facial scans. *Eur J Orthod* 2006; 28: 408-15.
22. Hajeer MY, Ayoub AF, Millett DT, Bock M, Siebert JP. Three-dimensional imaging in orthognathic surgery: the clinical application of a new method. *Int J Adult Orthodon Orthognath Surg* 2002; 17: 318-30.
23. Baysal A, Sahan AO, OzturkMA, Uysal T. Reproducibility and reliability of three-dimensional soft tissue landmark identification using three-dimensional stereophotogrammetry. *Angle Orthod* 2016; 86: 1004-9.
24. Leipziger LS, Schnapp DS, Haworth RD, Hoffman LA, La Trenta GS. Facial skeletal growth after timed soft-tissue undermining. *Plast Reconstr Surg* 1992; 89: 809-14.
25. Marchetti C, Bianchi A, Muyldermans L, Di Martino M, Lancellotti L, Sarti A. Validation of new soft tissue software in orthognathic surgery planning. *Int J Oral Maxillofac Surg* 2011; 40: 26-32.

การประเมินการเปลี่ยนแปลงของริมฝีปากบนและจมูก ภายหลังการปลูกถ่ายกระดูกเข้าฟันในผู้ป่วยปากแหว่งเพดานโหว่ข้างเดียวด้วยวิธีสแตอริโอโฟโตแกรมเมตรีแบบสามมิติ

อัญริยพร รานจันทร์, พูนศักดิ์ ภิเศก, สุภาพร คงสมบูรณ์

วัตถุประสงค์: เพื่อประเมินการเปลี่ยนแปลงรูปร่างของริมฝีปากบนและจมูกแบบสามมิติภายหลังการปลูกถ่ายกระดูกเข้าฟันในผู้ป่วยปากแหว่งเพดานโหว่ข้างเดียวแบบสมบูรณ์

วัสดุและวิธีการ: ผู้ป่วยปากแหว่งเพดานโหว่ข้างเดียวแบบสมบูรณ์แบ่งเป็นเพศชาย 10 คน และเพศหญิง 11 คน ได้รับการถ่ายภาพใบหน้าสามมิติ ก่อนและหลังการปลูกถ่ายกระดูกเข้าฟัน 3 เดือน แต่ละภาพจะถูกกำหนดจุดอ้างอิงของริมฝีปากและจมูกทั้งสิ้น 13 จุด โดยแต่ละจุดจะถูกวาดออกมาเป็นค่าในพิกัดแกน X, Y, และ Z โดยซอฟต์แวร์ Morpheus 3D จากนั้นจึงมีการเปรียบเทียบค่าการเปลี่ยนแปลงในแต่ละพิกัดของแต่ละจุดอ้างอิง

ผลการศึกษา: จากการเปรียบเทียบการเปลี่ยนแปลงของแต่ละจุดอ้างอิงภายหลังการปลูกถ่ายกระดูกเข้าฟัน พบว่าในพิกัดแกน X ทุกจุดอ้างอิงไม่มีการเปลี่ยนแปลงที่มีความสำคัญทางสถิติ ($p < 0.05$) แต่พบการเปลี่ยนแปลงเล็กน้อยของจุดอ้างอิงเลเบียเล ซูพีเรียส (labiale superius) ในแนวคิง (พิกัดแกน Y 0.78 ± 2.57 มิลลิเมตร) และแนวหน้าหลัง (พิกัดแกน Z 0.31 ± 0.67 มิลลิเมตร) และมีการเคลื่อนที่ไปทางด้านหน้าของจุดอ้างอิงซับอะลาร์ (Subalar) ในด้านที่ได้รับการปลูกถ่ายกระดูก (พิกัดแกน Z 1.31 ± 1.63 มิลลิเมตร)

สรุป: รูปร่างของริมฝีปากบนและจมูกมีการเปลี่ยนแปลงเพียงเล็กน้อยภายหลังการปลูกถ่ายกระดูกเข้าฟันเนื่องจากมีหลายปัจจัยที่อาจส่งผลต่อผลการศึกษา ดังนั้นประโยชน์ของการปลูกถ่ายกระดูกเข้าฟันที่มีผลต่อความสวยงามของริมฝีปากและจมูกจึงยังไม่สามารถสรุปได้อย่างชัดเจน
