

## Nose-Lip Morphology Changes after using Khon Kaen University Pre-Surgical Nasoalveolar Molding Device in Complete Unilateral Cleft Lip and Palate Patients by Measuring the Photographs

Thammapiwan A, DDS<sup>1</sup>, Pisek P, DDS, MSc, FRCDT, MOrthRCSEd, PhD<sup>1</sup>, Manosudprasit A, DDS DScD, CAGs<sup>1</sup>, Chowchuen B, MD, MBA<sup>2</sup>, Manosudprasit M, DDS, MDS, FRCDT<sup>1</sup>, Manosudprasit A, DDS, MSD, CAGs<sup>1</sup>

<sup>1</sup> Division of Orthodontic, Department of Preventive Dentistry, Faculty of Dentistry, Khon Kaen University, Khon Kaen, Thailand

<sup>2</sup> Division of Plastic Surgery, Department of Surgery, Faculty of Medicine, Khon Kaen University, Khon Kaen, Thailand

**Background:** Pre-surgical nasoalveolar molding (PNAM) device assists to approximate the normal anatomy of the nose and lip in cleft lip and palate patients prior to cheiloplasty. In 2012, the Khon Kaen University pre-surgical nasoalveolar molding (KKU PNAM) device was designed by dividing it into three parts: extraoral lip strapping, nasal molding device and intraoral active plate.

**Objective:** To evaluate changes to nose and lip morphology in the first two weeks, and post-application of the KKU PNAM device in infants with complete unilateral cleft lip and palate (UCLP).

**Materials and Methods:** Fifteen UCLP infants were treated with the KKU PNAM device. Measurements from two-dimensional photographs of the nose and upper lip on the cleft side were recorded at pre-treatment (T1), two weeks after the first visit (T2) and before cheiloplasty (T3). The means and standard deviations (SD) were used as a descriptive statistic to explain the ratios and angles values. Repeated one-way measures ANOVA was used to evaluate the statistical differences between the three groups.

**Results:** No significant difference to the ratio of the alar base width was reported. The ratio of nostril width at T1-T3 and T2-T3 decreased significantly. There were no changes to the ratio of nasal tip protrusion from the subnasale at T2-T3. A statistically significant decreased ratio of the alar base deviation, upper lip protrusion from the subnasale, vermillion gap and soft tissue gap was found in T1-T2, T2-T3 and T1-T3. Moreover, the ratio of nostril height, the ratio of columella length, columella angle and nostril axis inclination were increased significantly amid all points in time.

**Conclusion:** The application of the KKU PNAM device is a valuable procedure to improve nose and lip morphology in UCLP patients, thereby enhancing the overall quality of surgical repair.

**Keywords:** Unilateral cleft lip and palate, Khon Kean University pre-surgical nasoalveolar molding device, KKU PNAM

J Med Assoc Thai 2019;102(Suppl5): 34-9

Website: <http://www.jmatonline.com>

Unilateral cleft lip and palate (UCLP) occurs during the 4<sup>th</sup> to 8<sup>th</sup> week of development when the maxillary process and the medial nasal process fail to normally fuse; this occurs in conjunction with the failure of subsequent fusion of the palatal shelves. These are typical clinical features presented with asymmetry of the lip-nose structure as well as skeletal discrepancy. Furthermore, the perioral muscles are disrupted and oblique toward the cleft side. The wide alar area on the affected side lies more inferiorly than the non-cleft side. The

nose is deviated and presents a flabby dome; also columella length is dramatically shortened and located away from the facial midline<sup>(1,2)</sup>. Such defects affect the patient's physiological, functional, psychosocial, and especially, aesthetic conditions<sup>(3)</sup>. Therefore, these conditions challenge the surgeon team to achieve surgical lip and palate repair aimed at improving the stability of both function, and facial aesthetic.

Dogliotti and Bennun in 1991<sup>(4)</sup> first described the pre-surgical neonatal nasal molding procedure with a modified intraoral plate. The next step, popularised in the United States to improve nasal symmetry in cleft lip patients, was developed by Grayson et al in 1993<sup>(5)</sup>. Consequently, they designed PNAM to pre-surgically mould the lip, nose and alveolus in cleft lip and palate infants simultaneously.

Nevertheless, one weak point of the conventional pre-surgical nasoalveolar molding device is that the nasal

### Correspondence to:

Manosudprasit A.

Division of Orthodontic, Department of Preventive Dentistry, Khon Kaen University, Khon Kaen 40002, Thailand.

Phone & Fax: +66-43-222859

E-mail: [amonman@kku.ac.th](mailto:amonman@kku.ac.th)

**How to cite this article:** Thammapiwan A, Pisek P, Manosudprasit A, Chowchuen B, Manosudprasit M, Manosudprasit A. Nose-Lip Morphology Changes after using Khon Kaen University Pre-Surgical Nasoalveolar Molding Device in Complete Unilateral Cleft Lip and Palate Patients by Measuring the Photographs. J Med Assoc Thai 2019;102;Suppl5: 34-9.

stent and molding plate are fixed together, thus indicating that it was too large and awkward when inserted into the mouth. Also, it made it difficult to feed the infant via breastfeeding.

In 2012, the KKU PNAM device was designed and modified from Grayson's PNAM device by dividing it into three parts: extraoral lip strapping, nasal molding device and intraoral active plate. Recently, there have been studies which have documented the effectiveness of applying the KKU PNAM device in cleft patients. So, the purpose of the present study was to assess alterations to nose and lip morphology having applied the KKU PNAM device in UCLP infants.

## Materials and Methods

### Study design

Clinical study incorporating prospective data collection.

### Participants

Fifteen UCLP infants in care of the Tawanchai Cleft Center at the Faculty of Medicine, Khon Kaen University, Thailand. Inclusion criteria were: infants aged 0 to 3 months who had not previously received cheiloplasty; presented good co-operation, and willing to participate. Exclusion criteria were: infants with a systemic disease, disability, craniofacial issues or other syndromes.

### Procedures

All subjects received treatment utilising the KKU PNAM following the KKU protocol<sup>(6)</sup>.

#### Pre-treatment (T1)

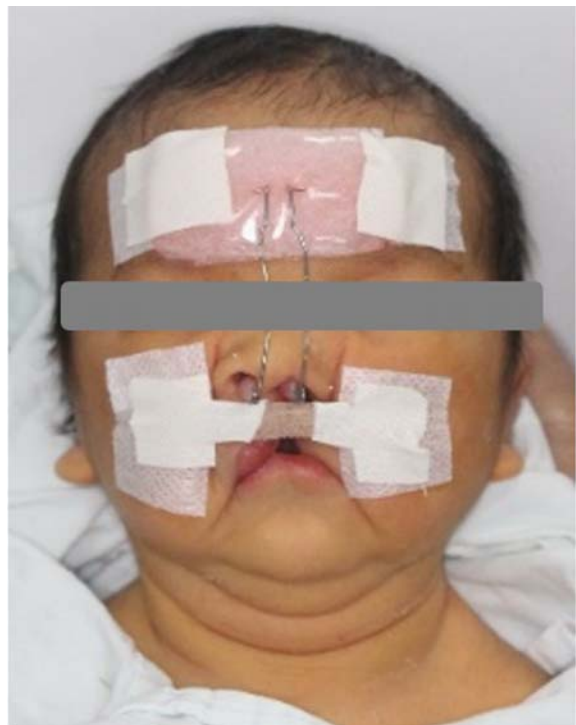- 1) History taking, extraoral and intraoral examination with diagnosis and treatment plan recorded.
- 2) Advising of treatment process to parents and signing of consent form.
- 3) Taking of photographs in 3 poses, i.e. frontal, lateral and submentovertex views. Impression-taking for study model.
- 4) Applying extraoral lip strapping and nasal molding device (Figure 1).
- 5) Providing lip strapping kit to parents, along with advice-giving on oral hygiene care, as well as how to use and take care of the related devices.

#### Two weeks post-initial visit (T2)

- 1) Taking of photographs in 3 poses.
- 2) Taking of impression for working model in order to fabricate intraoral active plate.
- 3) Inserting of intraoral active plate and advising parents to activate the retraction screw at a rate of twice a day.
- 4) Applying lip strapping and nasal molding device.

#### Prior to cheiloplasty (T3)

- 1) Approximately 2 to 3 months post-treatment,



**Figure 1.** Infant with lip strapping and nasal molding device.

treatment outcomes are assessed.

- 2) Taking photographs in addition to impression-taking for study model prior to referring patients for cheiloplasty.

### Data collection and measurements

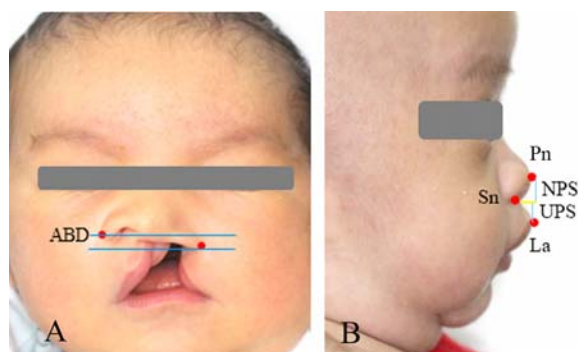
Two-dimensional photograph measurements were taken in T1, T2 and T3, with re-measurements performed at least 60 minutes apart by the same examiner. Nine measurements of the nose and lip on the cleft side were evaluated for ratio including: alar base width (ABW), alar base deviation (ABD), nostril width on cleft side (NWC), nostril height on cleft side (NHC), columella length (CL), nasal protrusion from the subnasale (NPS), upper lip protrusion from the subnasale (UPS), soft tissue gap (SG), and vermillion gap (VG). Two angle measurements were evaluated i.e.; columella angle (CA) and nostril axis inclination (NAI) (Table 1, Figure 2, 3).

### Statistical analysis

Means and standard deviations (SD) were employed as a descriptive statistic to explain the ratios and angles values. Repeated one-way measures ANOVA was applied to evaluate the statistical difference between the three groups. Comparison of the differences in the groups was performed using Bonferroni post-hoc tests ( $p$ -value  $< 0.05$ ). The intra-class correlation coefficient (ICC) was calculated

**Table 1.** Definitions of examined measurement lines and angles of the nose and upper lip

| Measurements | Definitions   |
|--------------|---|
| ABD          | The difference in distance between the vertical levels of the right and left alars.   |
| NPS          | The measurement from the pronasale (Pn) perpendicular to the horizontal line that passes through the subnasale (Pn-Sn).   |
| UPS          | The measurement from the labrale anterius (La) perpendicular to the horizontal line that passes through the subnasale (La-Sn).                                      |
| ABW          | The measurement between the most infero-lateral points of the alars.  |
| NWC          | The distance from the most medial nostril margin to the most infero-lateral nostril margin on the cleft side.   |
| NHC          | The distance from the highest point of the inner rim of the nostril perpendicular to the nostril width on the cleft side.   |
| CL           | The distance from the central junction of the columella base (subnasale) to the horizontal line that passes through the nostril height on the cleft side (Sn-NHC).  |
| SG           | The distance from the point most medial of the upper lip from the major segment to the point most medial of the upper lip from the minor segment of the cleft area. |
| VG           | The measurement of the widest point on the cleft gap at the vermilion border.   |
| CA           | The angular measurement between the line drawn from the columella (Cm) to the pronasale (Pn) and the alar base width (Cm-Pn-ABW).                                   |
| NAI          | The angular measurement between the alar base width and the nostril width on the cleft side. (ABW-NWC)  |



**Figure 2.** Location of measurement lines in frontal view (A) and lateral view (B).

to evaluate the intra-examiner reliability by the same examiner.

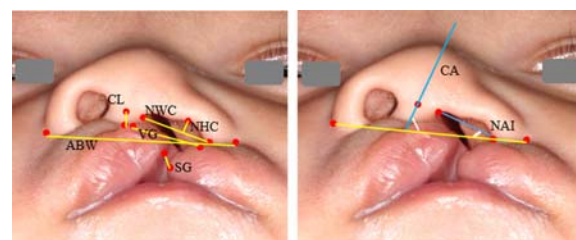
This research study was approved by the Ethics Committee on Human Research, Khon Kaen University (HE602316).

## Results

Each measurement was made incorporating 2D facial photographs at the initial visit (T1), 2 weeks after the first visit (T2) and before cheiloplasty (T3). The substantial reproducibility of ICC was found in a range of 0.85 to 0.99. The demographic data are reported in Table 2. Additionally, comparisons of treatment outcomes in changes of the nose and lip morphology are presented in Table 3, Figure 4.

## Discussion

The pre-surgical nasoalveolar molding procedure has been adopted by multidisciplinary cleft teams around the world. It benefits the primary surgery by improving the cleft lip and deviated nose<sup>(7,8)</sup>. The major treatment objective



**Figure 3.** Location of measurement lines in subment-oververtex view.

of PNAM is to approximate the normal anatomy of the nose and lip in cleft lip and palate patients<sup>(9)</sup>. Moreover, this procedure benefits surgeons responsible for patients demonstrating minimal severity of cleft deformity. The KKKU PNAM protocol<sup>(6)</sup>, begins with extraoral strapping combined with a nasal molding device as early as possible amid the initial two weeks of treatment. The strapping is applied tightly at the upper lip close to the base of the nose through the cheek on both sides to retract the perioral muscle in order to rapidly assist reduction of the cleft side and some alveolar cleft. Then, the nasal molding device is inserted into the nostril to lift the nasal dome so as to achieve symmetry of the nose as near to normal anatomy as possible prior to surgical repair. This follows Matsuo et al<sup>(10,11)</sup> who suggested to put the device into effect as soon as possible due to the high hyaluronic acid level and proteoglycan component of the intercellular matrix during this period. The nasal cartilages are easily moldable and still developing at this juncture.

Assessment by measuring the two-dimensional photographs in the present study was employed due to the fact that this method exhibits a myriad of benefits including, being convenient, it is economical, and is non-invasive. Thus, this is an alternative method to recording the progressive

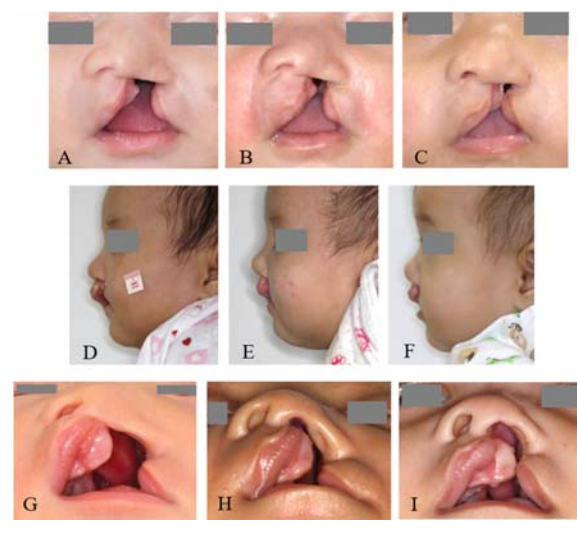changes to soft and hard tissue. However, this method may display certain disadvantages such as errors rendered from photographic magnification and distortion. Hence, the majority of measurements were evaluated as ratios so as to minimize inherent photographic errors.

The present study included 15 UCLP subjects. Patients' ages at KGU PNAM therapy outset ranged from 5 to 54 days. Evaluation of the nose and lip photographs took place at the initial visit (T1), two weeks after the initial visit (T2), and prior to cheiloplasty (T3). No significant changes to the alar base width amid all treatment periods were demonstrated. One possibility was that the nasal molding device controlled the increasing of the alar base width resultant of natural growth. This correlated with a previous study which revealed that there was no significant difference in alar base width when employing three-dimensional facial images to evaluate changes in nasal morphology in 10 infants with unilateral cleft lip and palate treated with PNAM prior to surgical repair<sup>(12)</sup>.

Significant reduction of the alar base deviation was observed amid T1 to T3. The alar base on both sides exhibited greater symmetry from the initial two weeks of treatment

until subsequent to applying the KGU PNAM. Likewise, a previous study<sup>(13)</sup> also presented the same result.

Nostril widths on the cleft side had decreased significantly at T2 to T3, and T1 to T3. Nevertheless, they were maintained during the first 14 days of therapy. The possible reason could have been a result of insufficient force amid extraoral strapping in the transverse direction, thus resulting in less of an effect rendered on nostril width. These results were in accordance with numerous publications that evaluated nose and lip changes amid different types of PNAM utilisation<sup>(8,12,14,15)</sup>. On the other hand, there were no significant changes in nostril width on the cleft side after 100 days of



**Figure 4.** Example of a patient undergoing the KGU PNAM therapy (A, D, G) pre-treatment (B, E, H), two weeks after initial visit (C, F, I) and prior to cheiloplasty.

**Table 2.** Demographic data

| Category  | UCLP patients<br>(n = 15) | Range     |
|---|---------------------------|-----------|
| Number of patients                              | 15 (100%)                 |           |
| Male  | 7 (46.7%)                 |           |
| Female  | 8 (53.3%)                 |           |
| Age at start of treatment (days)<br>(mean ± SD) | 18.3±15.0                 | 5 to 54   |
| Treatment time (days)<br>(mean ± SD)            | 88.8±17.7                 | 52 to 111 |
| Age at end of treatment (days)<br>(mean ± SD)   | 107±17.0                  | 77 to 130 |

**Table 3.** Measurement comparison between pre-treatment (T1), two weeks post initial visit (T2) and prior to cheiloplasty (T3) for the 15 subjects

| Measurements | Mean ± SD |           |           | T1-T2<br>p-value | T2-T3<br>p-value | T1-T3<br>p-value | Changes   |
|--------------|-----------|-----------|-----------|------------------|------------------|------------------|-----------|
|              | T1        | T2        | T3        |                  |                  |                  |           |
| ABD (ratio)  | 0.8±0.2   | 0.5±0.1   | 0.3±0.1   | 0.002*           | 0.000*           | 0.000*           | Decreased |
| ABW (ratio)  | 4.6±0.3   | 4.5±0.4   | 4.4±0.3   | 1.000            | 1.000            | 1.000            | Decreased |
| NWC (ratio)  | 2.3±0.3   | 2.0±0.3   | 1.7±0.2   | 0.060            | 0.000*           | 0.000*           | Decreased |
| NHC (ratio)  | 0.6±0.3   | 1.0±0.4   | 1.7±0.5   | 0.000*           | 0.004*           | 0.000*           | Increased |
| CL (ratio)   | 0.6±0.3   | 1.1±0.4   | 1.7±0.6   | 0.000*           | 0.013*           | 0.000*           | Increased |
| NPS (ratio)  | 1.1±0.3   | 1.4±0.4   | 1.5±0.3   | 0.000*           | 0.446            | 0.004*           | Increased |
| UPS (ratio)  | 1.0±0.4   | 0.7±0.2   | 0.6±0.1   | 0.036*           | 0.007*           | 0.002*           | Decreased |
| SG (ratio)   | 1.6±0.5   | 1.2±0.4   | 0.9±0.3   | 0.004*           | 0.020*           | 0.000*           | Decreased |
| VG (ratio)   | 2.5±0.5   | 2.1±0.5   | 1.8±0.4   | 0.003*           | 0.043*           | 0.000*           | Decreased |
| CA (°)       | 46.4±9.9  | 59.3±12.0 | 66.2±10.5 | 0.002*           | 0.038*           | 0.000*           | Increased |
| NAI (°)      | 6.9±3.9   | 12.5±4.8  | 16.6±4.9  | 0.000*           | 0.004*           | 0.000*           | Increased |

\* Indicates a statistically significant difference ( $p < 0.05$ )



applying the PNAM<sup>(13)</sup>.

These findings reveal an improvement to nostril height and columella length amid T1 through T3. This result concurs with Ezzat et al<sup>(16)</sup> who discovered a significant increase in columella height and columella length on the cleft side. Furthermore, studies by Pai and Gomez<sup>(13,17)</sup> reported similar findings.

The columella angle increased amid each visit toward the end of treatment as per the results of the present study. Furthermore, there was an augmentation in columella angle of around 20° when comparing T1 and T3. Monasterio in 2013<sup>(18)</sup> utilised a nasal elevator and elastic band strapping without an intraoral plate, whereby discovering that this technique improved columella angle post treatment. Moreover, Meltzer in 2013<sup>(19)</sup> mentioned that improvement of the columella angle provided improved nasal morphology as a result of PNAM.

There was a significant improvement to the nostril axis inclination on the cleft side in terms of T1 vs. T2, T2 vs. T3 and T1 vs. T3. Consequently, these devices provided more symmetry to the nostril shape on the defected side. Similar to a study by Gomez<sup>(13)</sup>, two-dimensional photographs were analysed in order to evaluate nasal changes pre and post PNAM therapy. Hence, it was concluded that an increase to the nostril axis inclination on the cleft side after applying the PNAM was observed.

Nasal tip protrusion of the subnasale caused a significant increase between T1 to T2 and T1 to T3, although no different alterations amid T2 to T3 were recorded. The reason might be because the nasal tip grew in a forward and downward direction. An extraoral strapping worked both transversely to reduce the cleft gap as well as in the antero-posterior direction to improve nose projection. So, dramatic changes to the projection of the nose mostly occurred in T1 to T2. Moreover, during T2 to T3 the force of the extraoral strapping focused on the transverse direction, thus, changes amid nasal tip protrusion occurred less throughout this period. Interestingly, using only an extraoral strapping can reduce upper lip gap and lip protrusion during the initial 14 days of treatment as demonstrated in the results which revealed a significant decrease to the soft tissue gap, the vermillion gap and the upper lip protrusion from the subnasale on the cleft side at T1 to T2. These similar outcomes were also seen in previous studies using lip tape in 8 UCLP participants: the vermillion width had decreased after six weeks of treatment despite non-inclusion of an intraoral plate in any part of treatment<sup>(20)</sup>. The advantages of lip strapping are to narrow lip defects which assist feeding, create perioral muscle function, encourage muscle development and facilitate cheiloplasty with less scarring and less complications. Furthermore, this supports psychosocial welfare among parents resultant of reducing the severity of the infants' deformities amid the first step of treatment.

In order to achieve a favourable outcome, patients' parents' co-operation is the most critical factor leading to the success of treatment. For this reason, it is necessary to emphasize to parents the objectives and steps of treatment.

Over correction to compensate relapse and differential normal growth after primary cheiloplasty is recommended amid KKU PNAM treatment. The asymmetry of the nose significantly relapsed in the first year and then was stable in the second and third years postoperatively<sup>(8)</sup>. Therefore, overcorrection by compressing the upper lip and alveolar cleft as much as possible amid PNAM therapy is desirable.

## Conclusion

Nose and lip morphology in 15 UCLP patients was significantly improved in the first two weeks of KKU PNAM treatment prior to cheiloplasty. Accordingly, this led to a reduction in deformity severity, and a decrease in the complexity of surgical procedures. Also, this provided enhanced aesthetic outcomes with less scar contraction. Nevertheless, further studies are needed to assess outcomes in relation to nose and lip morphology post PNAM application. Finally, along-term study ought to be performed to further evaluate the effectiveness of the KKU PNAM.

## What is already known on this topic?

Previous studies have reported the effect on the nose and upper lip changes rendered by the KKU PNAM appliance in UCLP infants between pre-treatment and post-treatment by using direct and 3D measurements. To date, an evaluation of the effectiveness of the KKU PNAM appliance in terms of the nasal molding device and extraoral strapping at the two week juncture post-treatment has not been done.

## What this study adds?

The present study aimed to assess the changes in nose and upper lip morphology among UCLP infants in the initial two weeks post application of the KKU PNAM device, with the purpose of evaluating the effectiveness of the entire device in terms of reducing cleft deformities, providing greater nasal symmetry and improving lip morphology as much as possible prior to cheiloplasty.

## Acknowledgements

The authors would like to express their sincere thanks to all participants as well as their parents, the Faculty of Dentistry, Khon Kaen University and the Center of Cleft Lip-Cleft Palate and Craniofacial Deformities, Khon Kaen University under the Tawanchai Royal Grant Project for their valuable support.

## Potential conflicts of interest

The authors declare no conflicts of interest.

## References

1. Broadbent TR, Woolf RM. Cleft lip nasal deformity. *Ann Plast Surg* 1984;12:216-34.
2. Millard DR Jr. Embryonic rationale for the primary correction of classical congenital clefts of the lip and palate. *Ann R Coll Surg Engl* 1994;76:150-60.
3. Alansari R, Bedos C, Allison P. Living with cleft lip and palate: the treatment journey. *Cleft Palate Craniofac J*

- 2014;51:222-9.
4. Dogliotti P, Bennun R, Losoviz EA, Ganiewich E. Tratamiento no quirurgico de la deformidad nasal en el paciente fisurado. *Rev Ateneo Argent Odontol* 1991;27:31-5.
5. Grayson BH, Cutting C, Wood R. Preoperative columella lengthening in bilateral cleft lip and palate. *Plast Reconstr Surg* 1993;92:1422-3.
6. Manosudprasit M, Chongcharueyskul P, Wangsrimonkol T, Pisek P. Presurgical nasoalveolar molding techniques for a complete unilateral cleft lip and palate infant: A case report. *J Med Assoc Thai* 2015;98 Suppl 7:S234-42.
7. Bennun RD, Perandones C, Sepiarsky VA, Chantiri SN, Aguirre MI, Dogliotti PL. Nonsurgical correction of nasal deformity in unilateral complete cleft lip: a 6-year follow-up. *Plast Reconstr Surg* 1999;104:616-30.
8. Liou EJ, Subramanian M, Chen PK, Huang CS. The progressive changes of nasal symmetry and growth after nasoalveolar molding: a three-year follow-up study. *Plast Reconstr Surg* 2004;114:858-64.
9. Grayson BH, Santiago PE, Brecht LE, Cutting CB. Presurgical nasoalveolar molding in infants with cleft lip and palate. *Cleft Palate Craniofac J* 1999;36:486-98.
10. Matsuo K, Hirose T, Tomono T, Iwasawa M, Katohda S, Takahashi N, et al. Nonsurgical correction of congenital auricular deformities in the early neonate: a preliminary report. *Plast Reconstr Surg* 1984;73:38-51.
11. Matsuo K, Hirose T, Otagiri T, Norose N. Repair of cleft lip with nonsurgical correction of nasal deformity in the early neonatal period. *Plast Reconstr Surg* 1989;83:25-31.
12. Singh GD, Levy-Bercowski D, Santiago PE. Three-dimensional nasal changes following nasoalveolar molding in patients with unilateral cleft lip and palate: geometric morphometrics. *Cleft Palate Craniofac J* 2005;42:403-9.
13. Gomez DF, Donohue ST, Figueroa AA, Polley JW. Nasal changes after presurgical nasoalveolar molding (PNAM) in the unilateral cleft lip nose. *Cleft Palate Craniofac J* 2012;49:689-700.
14. Kecik D, Enacar A. Effects of nasoalveolar molding therapy on nasal and alveolar morphology in unilateral cleft lip and palate. *J Craniofac Surg* 2009;20:2075-80.
15. Singh GD, Levy-Bercowski D, Yanez MA, Santiago PE. Three-dimensional facial morphology following surgical repair of unilateral cleft lip and palate in patients after nasoalveolar molding. *Orthod Craniofac Res* 2007;10:161-6.
16. Ezzat CF, Chavarria C, Teichgraber JF, Chen JW, Stratmann RG, Gateno J, et al. Presurgical nasoalveolar molding therapy for the treatment of unilateral cleft lip and palate: a preliminary study. *Cleft Palate Craniofac J* 2007;44:8-12.
17. Pai BC, Ko EW, Huang CS, Liou EJ. Symmetry of the nose after presurgical nasoalveolar molding in infants with unilateral cleft lip and palate: a preliminary study. *Cleft Palate Craniofac J* 2005;42:658-63.
18. Monasterio L, Ford A, Gutierrez C, Tastets ME, García J. Comparative study of nasoalveolar molding methods: nasal elevator plus DynaCleft® versus NAM-Grayson in patients with complete unilateral cleft lip and palate. *Cleft Palate Craniofac J* 2013;50:548-54.
19. Meltzer NE, Vaidya D, Capone RB. The cleft-columellar angle: a useful variable to describe the unilateral cleft lip-associated nasal deformity. *Cleft Palate Craniofac J* 2013;50:82-7.
20. Dawjee SM, Julyan JC, Krynauw JC. Lip tape therapy in patients with a cleft lip—a report on eight cases. *SADJ* 2014;69:62, 64-8, 70.