

The Accuracy of Soft Tissue Prediction using Morpheus 3D Simulation Software for Planning Orthognathic Surgery

Kiratiya Traisrisin DDS*,
Tasaneewangrimongkol DDS, MS, PhD*, Poonsak Pisek DDS*,
Pattaramon Rattanaphan DDS**, Subin Puasiri DDS***

* Department of Orthodontics, Faculty of Dentistry, Khon Kaen University, Khon Kaen, Thailand

** Department of Oral and Maxillofacial Surgery, Faculty of Dentistry, Khon Kaen University, Khon Kaen, Thailand

*** Department of Community Dentistry, Faculty of Dentistry, Khon Kaen University, Khon Kaen, Thailand

Objective: To assess the accuracy of Morpheus 3D simulation software by comparing the positional differences of 17 soft tissue landmarks between the simulated 3D image and actual post-operative 3D image.

Material and Method: 3D facial images of 20 subjects (mean age, 24 ± 5.13 years) were taken 1 month before and 3 months after the surgery. The virtual 3D fused images from pre-surgical digital cephalogram and 3D facial scanning were prepared. Surgical simulation was performed with Morpheus Facemaker® software. The simulated and actual 3D image after the surgical treatment acquired from each subject were prepared, and 17 soft tissue landmarks around the nose and lips were plotted and analyzed. Statistical analysis was performed using paired t-tests ($p < 0.05$). Intra-examiner assessments of repeatability of soft tissue landmark locations were done by Bland-Altman Limits of Agreement.

Results: No statistically significant differences were found in all the mean differences of 3D coordinate values (x, y and z) of 17 landmarks between predicted outcomes using Morpheus 3D simulator and actual postsurgical outcomes, except that the central portion of the upper lip (Ls and Stms) showed statistically significant changes in an anterior direction on the z-axis (means 0.98 mm and 1.30 mm, respectively).

Conclusion: The soft tissue prediction algorithm provided by the Morpheus 3D Facemaker® software was found to be sufficiently accurate in predicting soft tissue changes after orthognathic surgery. This encourages more acceptance and confidence in the use of the simulation capabilities among clinicians, and its routine use in patient consultations.

Keywords: Morpheus 3D simulation software, Virtual 3D fused images, Simulated 3D image, Actual 3D image

J Med Assoc Thai 2017; 100 (Suppl. 6): S38-S49

Full text. e-Journal: <http://www.jmatonline.com>

Facial aesthetic problems associated with severe skeletal discrepancies, especially skeletal Class III, has more prevalence in Asian populations⁽¹⁾. They usually seek treatment for aesthetic reasons because these often affect the psychosocial status^(2,3). During the last decade, orthognathic surgery has become a significant method in correcting these abnormalities. Therefore, accurate prediction of the postoperative situation is essential for its success.

In the past, 2-dimensional imaging techniques were routinely used to predict desired changes postoperatively⁽⁴⁻⁶⁾. However, the validity and reliability of these systems are limited by their two-dimensional nature when dealing with a three-dimensional object⁽⁷⁾.

To solve the problems of 2D analysis methods, there was an interest in a new program of 3D virtual planning of orthognathic surgery in combination with 3D soft tissue simulation. Therefore, 3D imaging has been developed and can provide a complete assessment of the patients and detailed information: aiding the diagnosis of craniofacial structural problems, enhancing the clinician's recognition of them and helping a more effective treatment planning, especially in orthognathic surgery⁽⁸⁻¹⁰⁾.

Alves et al⁽¹¹⁾ found that surgeons and orthodontists shifted their attention regarding predictability of soft tissue simulation from occlusion-based planning to soft tissue-based planning. The development of soft tissue predictions generated by computer-aided surgical simulation (CASS) software represents a paradigm shift in surgical planning and these currently exist in the market⁽¹²⁾. Although, the CASS has further increased the importance, the ability

Correspondence to:

Wangrimongkol T, Department of Orthodontics, Faculty of Dentistry, Khon Kaen University, Khon Kaen 4002, Thailand.
Phone & Fax: +66-43-202863
E-mail: tasaneewang@yahoo.com

of current software is still unclear. Therefore, the accuracy of the soft tissue predictions generated by this software should be assessed. One of the CASS that is available at our center is the Morpheus 3D dental solution Facemaker® software (Seoul, Korea). The accurate simulation of this software should be evaluated before implementation in routine clinical practice.

The objective of this present study aimed to evaluate the accuracy of the Morpheus 3D simulation software by comparing the positional differences of 17 soft tissue landmarks between the simulated and actual post-operative 3D images.

Material and Method

Study population

Twenty Thai patients (4 males and 16 females) with skeletal Class III problems, including non-cleft and non-syndromic cleft lip/palate patients were recruited. The seven patients underwent mandibular setback using a bilateral sagittal split osteotomy (BSSO) and the 13 patients underwent Le Fort maxillary advancement according to the Department of Oral and Maxillofacial Surgery, Khon Kaen University (OMS KKU) protocol, during June 2015 to December 2016. This present study was conducted under approval by the Khon Kaen University ethics committee (KKUEC-HE592128). All participating patients aged older than 18 years, with a mean age of 24 ± 5.13 years at the time of surgery.

Inclusion criteria were the patients who had completed preparatory orthodontic treatment were ready for the orthognathic surgery, and willing to participate in this study.

The exclusion criteria were the patients who had associated craniofacial malformations with syndromes, relapsation from previous orthognathic surgery, acquired facial skeletal problems due to accidents and other orthognathic procedures, including segmental osteotomy procedure.

Withdrawal criteria were the patients who had complications after the surgery such as infections and delayed wound healing.

Data acquisition

After completion of any planned pre-surgical orthodontics, the following steps were adopted for each patient (Fig. 1). Within one month before surgery, the pre-operative 3D facial scan images (3D FSIs) were acquired using Face maker camera from Morpheus 3D scanner (Seoul, Korea). Patients sat wearing a hair band

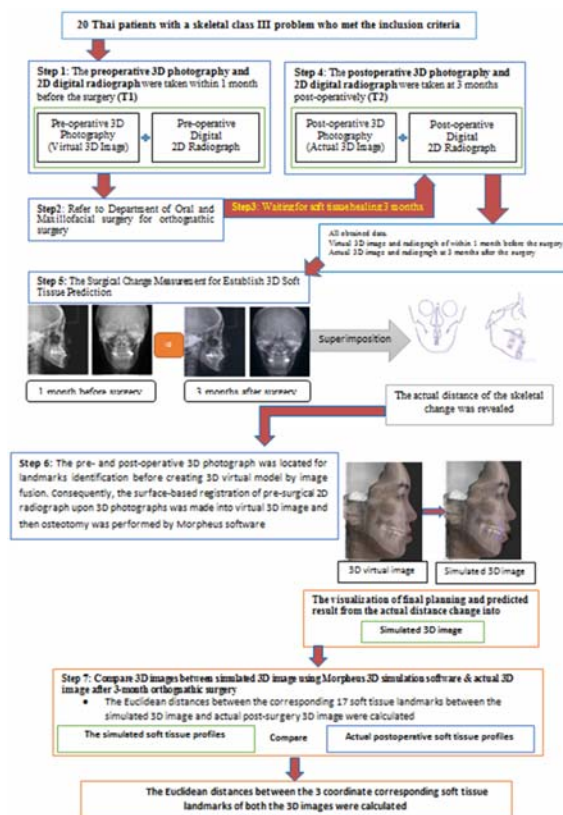


Fig. 1 Flow chart of the study.

to keep hair away from the face and then the entire face of the patients was scanned with the head in a natural position from three different horizontal angles (frontal, the right and left sides at an angle of 45°). The virtual 3D images were obtained by fusing 2D images of the 3 parts of facial soft tissue surface using Morpheus 3D simulation software. At the same time, both digital Lateral Cephalometric (LC) and Posteroanterior Cephalometric (PAC) radiographs (T1) were taken using SIDEXIS XG system, Sirona Dental Systems GmbH at the Department of Radiology of Faculty of Dentistry, Khon Kaen University by an experienced radiographic technician. Furthermore, for all patients, a postoperative 3D facial scan images and digital LC and PAC radiographs (T2) were acquired at 3 months after the surgical correction. The virtual 3D image, T1 and T2 were prepared to obtain the simulated 3D image later on.

Registration

The pre-surgical 3D image and the digital images of LC and PAC radiographs of each patient were imported into the Morpheus 3D software

(MDS3.0). The soft tissue landmarks were also plotted on the pre-surgical 3D image and fixed by the software. These 17 significant reference landmarks were Pronasale (Pn), Subnasale (Sn), Alare (AIR, L), Soft tissue A point (A'), Labiale superius (Ls), Stomion superius (Stms), Stomion inferius (Stmi), Labiale inferius (Li), Upper lip point (ULP), Lower lip point (LLP), Crista philtri (CphR, L), Cheilion (ChR, L), soft tissue B point (B'), and soft tissue pogonion (Pog') (Fig. 2 and Table 1). The hard tissue landmarks were also traced and analyzed by the software.

The surface-based registration of pre-surgical 2D radiograph upon 3D photographs was made into virtual 3D image. The Morpheus 3D simulation software automatically registers the extracted skin surface of the pre-surgical cephalograms (LC&PAC) digital image and the surface of the 3D facial scan to obtain optimal registration parameters based on the rigid transformation, including the x-axis, y-axis, and z-axis translations and rotations. Therefore, skin surface registration corrects any translational, rotational and magnification mismatches.

The surgical change measurements for established 3D soft tissue prediction

In order to eliminate discrepancies between the predicted skeletal movements and the actual displacement of the surgery, superimposition of pre-(T1) on post-(T2) surgical radiographs was used to compute the different distance of skeletal change from the surgery, which followed the study of Schendel et al⁽⁹⁾. This is to ensure whether the actual jaw displacements were ready to create 3D simulated model.

Surgical simulation

After the software program generated skin surface registration for 3D image overlay on LC and PAC before the simulated surgery. The translation and rotation of the moved bone segments on the three

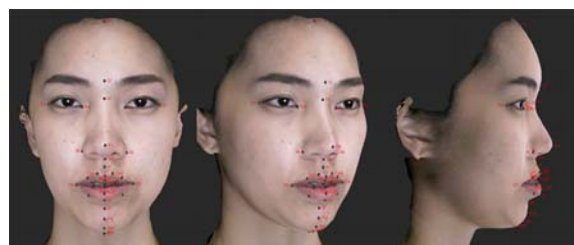

Fig. 2 Seven-teen selected points of soft tissue landmarks form Morpheus 3D simulation software that were used in this present study.

dimensional 3D virtual models and corresponding relationship between bone and soft tissue were performed.

Quantification of differences between simulated and actual post-surgery models

According to Morpheus 3D simulation software, after setting up the reference frame and identifying all landmarks on the 3D photograph, the 3D images of both soft tissue change prediction from this simulator (simulated 3D image) and the actual 3D image of post-operative soft tissue change in the orthognathic surgery patients were compared. This procedure was used to set the two images at the same spatial position in order to show the changes. The simulated 3D image was automatically moved to a close proximity with the actual 3D image of post-operative soft tissue change, and automatic registration was performed. Then, the software computed the surface distances between simulated and actual post-surgical 3D images at 17 soft tissue landmarks.

Statistical analyses

The SPSS software program version 20 (SPSS Institute, IBM) was used to perform the following calculations. All tests are at significance level of 0.05. General characteristics of subjects were presented as means and standard deviations (SD) for continuous variables and percentage for categorical variables. Shapiro-Wilk test was used to verify the normality of the variables. The Euclidean distances between the corresponding 17 soft tissue landmarks on the simulated and actual postoperative 3D image were calculated as a parameter for the accuracy of simulation. If Shapiro-Wilk test showed distance differences between simulated and actual 3D image after surgery normally distributed, the paired *t*-test was used to determine. Wilcoxon signed-rank test was used when data was skewed. Intra-examiner reliability of soft tissue landmark locations was assessed by Bland-Altman Limits of Agreement.

Results

This present study was performed on a total of 20 subjects, including 10 non-cleft patients (50%) and 10 cleft patents (50%). The samples comprised 4 men (20%) and 16 women (80%). The average age of the subjects was 24±5.13 years. All of the patients had a skeletal class III condition and were currently having orthodontic treatment preparatory to orthognathic surgery. The surgery was divided into two groups;

one jaw surgery done by BSSO mandibular setback (7 subjects, 35%) and two jaws surgery done by Le Fort maxillary advancement and BSSO mandibular setback (13 subjects, 65%). Table 2 shows means and standard deviations of age, amount and percentages of genders, operations and characteristics of the patients.

Reliability of landmarks identification

In the present study, Bland-Altman Limits of Agreement (LoA)^(13,14) test was used for intra-examiner assessments of reliability of 17 soft tissue landmark locations on both predicted and post-surgical (actual) 3D images for 10 subjects: 5 non-cleft subjects and 5

subjects with clefts. Differences between Euclidean distances of the first and repeated soft tissue landmark locations were provided by Morpheus software calculations for each landmark.

Following the method of Toma et al⁽¹⁵⁾, the LoA reliability test for the 17 soft tissue landmark locations on both predicted and actual 3D images defined three levels; high reproducibility (<0.5 mm), moderate reproducibility (0.5 to ≤1.0 mm) and poor reproducibility (>1 mm) (Table 3).

The accuracy of the software prediction

Table 4 displays the different distance

Table 1. Definitions of the 17 selected points of soft tissue landmarks that were used in this present study

Landmarks	Abbr	Details of definition
Alare	Al(R,L)	The widest part of lateral surface of the external nose
Pronasale	Pn	The most prominent or anterior point of the nose tip and a half distance between right and left alare (Widest part of ala of nose on each side)
Subnasale	Sn	The midpoint where the columella base and the upper lip meet and a half distance between right and left alare (Widest part of ala of nose on each side)
tissue A point	A'	The deepest point on the outline of the upper lip established by a tangent parallel to the PM line and a half distance between right and left Crista philtri (the most superior of cupid bow)
Crista philtri	Cph(R,L)	The most superior of cupid bow (the peaks of the bow coincide with the philtral columns giving a prominent bow appearance to the lip)
Cheilion	Ch(R,L)	The lateral most point located at the right and left labial commissure
Labialesuperius	Ls	The midpoint of the upper border of the upper vermillion line
Stomionsuperius	Stms	The midpoint of the lowermost point of the upper lip
Stomioninferius	Stmi	The midpoint of the uppermost point of the lower lip
Labialeinferius	Li	The midpoint of the lower border of the lower vermillion line
Upper lip point	ULP	The middle point of upper lip and a half distance between right and left Cheilion (Lateral commissures)
Lower lip point	LLP	The middle point of lower lip and a half distance between right and left Cheilion (Lateral commissures)
Soft tissue B point	B'	The deepest point on the outline of the lower lip or most concave point on supramentale
Soft tissue pogonion	Pog'	The most anterior midpoint of the chin

Table 2. The participant demographics

Demographic data		Total, n (%)	Mean±SD
Age	18-25 years	15 (75)	24±5.13
	≥26 years	5 (25)	
Gender	Males	4 (20)	-
	Females	16 (80)	
Operation	1 jaw	7 (35)	-
	2 jaws	13 (65)	
Characteristics	Cleft	10 (50)	-
	Non-cleft	10 (50)	

Table 3. Reproducibility levels of 17 soft tissue landmarks identification on predicted 3D images and actual 3D images (total and detail sample)

Method of assessments	Intra-examiner using Bland-Altman plots											
	Virtual 3D images						Actual 3D images					
	Non-cleft Patients			Cleft Patients			Non-cleft Patients			Cleft Patients		
Reproducibility level (mm)	<0.5	0.5-≤1.0	>1.0	<0.5	0.5-≤1.0	>1.0	<0.5	0.5-≤1.0	>1.0	<0.5	0.5-≤1.0	>1.0
Number of landmarks	14	3	0	12	5	0	14	3	0	12	5	0
Percentages	82.4	17.6	0	70.5	29.5	0	82.4	17.6	0	70.5	29.5	0
Landmarks	PnSnA'	Al(R)	-	PnSnA'	Al(R)	-	PnSnA'	Al(R)	-	PnSnA'	Al(R)	-
	Cph(R)	Al(L)		Cph(L)	Al(L)		Cph(R)	Al(L)		Cph(R)	Al(L)	
	Cph(L)	B'		Ch(R)	B'		Cph(L)	B'		Ch(R)	B'	
	Ch(R)			Ch(L)	Cph(R)		Ch(R)			Ch(L)	Cph(L)	
	Ch(L)			ULPL	Ls		Ch(L)			ULPL	Ls	
	LsUL			LPLi			LsUL			LPLi		
	PLLP			Stms			PLLP			Stms		
	LiX			Stmi			LiX			Stmi		
	Stms			Pog'			Stms			Pog'		
	Stmi						Stmi					
Pog'			-				Pog'		-			

Total number of landmarks = 17

Table 4. Mean differences in 3D coordinate measurements of changes in landmark locations comparing simulated 3D images and actual 3D images after the surgical treatment for all participating patients

Landmarks	X (n = 20)				Y(n=20)				Z (n=20)			
	Mean diff (mm)	SD (mm)	95% CI	p-value ^a	Mean diff (mm)	SD (mm)	95% CI	p-value ^a	Mean diff (mm)	SD (mm)	95% CI	p-value ^a
Pn	0.03	0.35	0.16	0.70	-0.09	0.45	0.26	0.36	-0.20	0.77	0.36	0.27
Sn	0.04	0.40	0.19	0.63	-0.04	0.60	0.28	0.76	-0.05	1.08	0.50	0.83
Al(R)	0.25	0.53	0.25	0.05	0.11	0.69	0.32	0.49	-0.22	.88	0.41	0.29
Al(L)	0.01	0.57	0.27	0.93	0.03	0.75	0.35	0.85	-0.19	1.17	0.55	0.49
A'	0.08	0.30	0.14	0.24	-0.09	0.41	0.19	0.32	-0.12	.61	0.28	0.40
Cph(R)	0.04	0.27	0.15	0.56	0.16	0.75	0.19	0.34	0.55	1.23	0.58	0.06
Cph(L)	0.08	0.35	0.15	0.33	-0.06	0.56	0.18	0.63	0.27	0.79	0.60	0.15
Ch(R)	0.06	0.27	0.47	0.31	-0.09	0.65	0.17	0.53	0.26	0.93	0.58	0.22
Ch(L)	0.08	0.31	0.27	0.24	-0.15	0.51	0.25	0.22	0.02	0.95	0.70	0.92
Ls	-0.05	0.23	0.11	0.35	-0.04	0.28	0.13	0.55	0.98	1.68	0.32	0.018*
Stms	0.05	0.34	0.16	0.49	-0.01	0.66	0.31	0.93	1.30	2.13	0.91	0.013*
Stmi	-0.03	0.41	0.19	0.78	0.22	0.87	0.41	0.26	0.28	1.51	0.71	0.41
Li	.001	0.34	0.16	0.86	-0.04	0.54	0.22	0.78	0.01	1.19	0.56	0.97
ULP	-0.37	1.01	0.35	0.12	0.17	0.35	0.35	0.26	0.35	0.79	0.37	0.06
LLP	0.11	0.58	0.26	0.40	0.22	0.54	0.26	0.09	0.65	1.50	0.37	0.07
B'	0.02	0.32	0.30	0.77	0.01	0.41	0.30	0.93	0.55	1.23	0.43	0.06
Pog'	-0.04	0.31	0.24	0.63	0.09	0.39	0.24	0.32	0.42	1.28	0.45	0.16

^a Paired *t*-test was performed. X-coordinate indicates left-right axis (+ = left, - = right); Y-coordinate, vertical axis (+ = superior, - = inferior); Z-coordinate, anteroposterior axis (+ = anterior, - = posterior); SD = standard deviation.

* Significance: *p*<0.05

changes in x, y and z coordinate measurements comparing landmark locations on predicted and actual (post-surgical) 3D facial soft tissue images, for all 20 subjects. No statistically significant differences were found in all the mean differences in 3D coordinate values (x, y and z) of 17 landmarks between the predicted outcomes using Morpheus 3D simulator and actual surgical outcomes after surgical treatments, except that the central portion of the upper lip (Ls and Stms) showed statistically significant changes in an anterior direction on the z-axis (Table 4: means 0.98 mm and 1.30 mm, respectively).

Discussion

With increasing patient demands for an esthetic facial appearance, especially in patients with skeletal discrepancies, there has been a desire to provide images of expected changes in facial soft tissues when planning orthognathic surgery. In the past, 2D imaging techniques have been used to evaluate changes in the soft tissue facial profile despite its limitations in assessing the parasagittal area and

representation of a 3D subject⁽¹⁶⁾. These shortcomings have caused an increase in the use of 3D imaging techniques. The advent of 3D stereophotogrammetry⁽¹⁷⁻¹⁹⁾ has enabled improvements in both planning and evaluation of surgical outcomes.

3D CBCT images, widely used in dentistry, provide information about both superficial and deep structures. However, the disadvantages of CBCT include low resolution caused by the distance between slices, absence of color value and surface texture of skin, and undesirable level of radiation exposure^(20,21). The Morpheus 3D stereophotogrammetric imaging system combines with digital lateral and postero-anterior cephalometric radiographs and Morpheus Facemaker software are used to enable 3D imaging and measurements for maxillofacial surgery simulations with less radiation exposure of a patient compared with CBCT.

Reliability of landmarks identification on 3D facial soft tissue images

The accuracy of the Morpheus 3D prediction

of surgical outcomes was tested by comparisons of manually-set landmark locations on predicted and actual post-surgical facial soft tissue images. This accuracy test depended on the reliability of the manual setting of the landmarks. Tests of reliability involved repeated settings (2 weeks apart) of 17 landmarks on the predicted and actual 3D images for 10 subjects (5 cleft and 5 non-cleft patients). The tests found measurement discrepancies between the first and repeat of landmarks locations for all subjects on both predicted and actual images which were less than 0.5 mm for 14 of the 17 landmark locations and the remaining 3 landmarks only differed by 0.5 to 1.0 mm. (Table 3). This was acceptable, agreeing with Kim et al⁽²²⁾ who also used the Morpheus 3D® scanner. Authors using other 3D imaging systems have also accepted the same level of accuracy⁽²³⁻²⁶⁾. Weinberg et al⁽²⁷⁾ and Wong et al⁽²⁸⁾ reported validity of claims of digital 3D photogrammetry accuracy which depended on calibration procedures compared with a direct anthropometric measurement. However, it is suggested that further studies on intra- and inter-examiner reproducibility be undertaken.

When conducting landmark exercises on non-sedated human subjects without fiducial markers or physical markings on the patient, many have noted that different facial landmarks have wide variation in their degree of reproducibility, ranging from 2 mm to less than 0.5 mm⁽²⁹⁾. Landmarks with well-defined borders or edges show higher degrees of reproducibility than those placed on gently curving slopes. Landmarks such as soft tissue nasion, alar crest, gonion, and menton, those are less well-defined, were found to have poor reproducibility⁽³⁰⁾.

Our findings illustrated both right and left Cheilion (ChR&ChL), right and left Crista philtri (CphR&CphL) and Labiale superius (Ls) in non-cleft patients were the most reproducible landmarks agreeing with previous studies^(15,30-32). This finding can be attributed to the well-defined contours around the mouth making it relatively easy to identify the exact position of these points on the face. Soft tissue B point (B'), the deepest point on the outline of the lower lip or most concave point on supramentale, was the least reproducible landmark on the face because of the difficulty in identifying the deepest point on the outline of the lower lip (Table 3). Additionally, it becomes more difficult to locate valid landmarks with surfaces having minimal curvature identification such as right and left alare.

It is not surprising that there was slightly less reliability of landmark locations among the cleft patients

for Labiale superius (Ls) and both right and left Crista philtri (CphR&CphL) because these patients have scar formation affecting these landmarks (Table 3).

Measure of “accuracy” of the software prediction

This present study aimed to assess the accuracy of the Morpheus 3D simulation software by comparing the soft tissue landmark locations between the simulated 3D image and actual 3D image. The planned skeletal movement before surgery did not necessarily reflect the actual surgical procedures and their outcomes due to difficulties in ensuring that the exact same distance change of the skeletal movement is carried out as in operating room. Consequently, in order to eliminate discrepancies between the predicted skeletal movement and the actual displacement, postsurgical models are the best measure of what movements were actually produced as a guide for positioning of the virtual surgical models in this present study that correspond with others studies^(9,33-35).

Our study found no statistically significance in all the mean differences in 3D coordinate values (x, y and z) of 17 landmarks between predicted and actual surgical outcomes after the surgical treatment, except that the central portion of the upper lip (Ls and Stms) showed statistically significant changes in an anterior direction on the z-axis (Table 4: means 0.98 mm and 1.30 mm, respectively). The majority of the subjects had the differences within 1.0 to 1.50 mm. Xia et al⁽³⁶⁾ and several studies^(27,37,38) stated that the error magnitude scores of less than 2 mm showed no clinical significance. The present study demonstrated the differences accordant with those studies. Therefore, our present study showed that most of the subjects had no statistically or clinically significant differences of facial landmarks in all 3D coordinated planes.

Although all subjects were instructed to maintain a neutral facial expression with the lips at rest, it is possible that changes in facial expression contributed to some degree of differences in before-and after-surgery image acquisition with Morpheus 3D simulator. Nadjmi et al⁽³⁹⁾ noted problems with capture and use of facial images that enable accurate simulations of changes to the lips images resulting from orthognathic surgery. They suggested the main reasons why the lip posture is less accurately simulated. The connection between lower and upper lips is the most important reason. These authors acknowledged limitation of their software as “the soft tissue model could not clearly separate the lips from each other during simulation if the lips are in contact and not in a relaxed

position during pre-operative 3D scan". Moreover, the lack of optimal definitions of boundary conditions due to sliding contact behavior between teeth and lips, and the upward and inward rotational movement of the lower lip, is not accurately simulated. In addition, the lack of proper simulation of the changes in orientation of the circum-oral musculature that supports the lips after the harmonization of occlusion may negatively influence the results. The prediction software cannot be expected to provide an accurate facial image to match these personalized adjustments, probably similar to 3D Morpheus software. This confirmed the earlier study's findings by Mollemans et al⁽⁴⁰⁾. The study found that the largest deviations were in the perioral region, which included the most dynamic parts of the face. It was suggested that separating the lips from each other during the simulation, adding sliding contacts between the teeth and the lips, and preventing mental straining during imaging would largely improve the simulation. Other factors influencing the accuracy of the prediction are soft tissue remodeling, tissue relocation and hard tissue relapse⁽⁴¹⁾. Moreover, postoperative changes due to restart of orthodontics tooth movement within one month after the surgery aiming to take advantages of the post-surgical regional acceleratory phenomenon (RAP) effects to assist and accelerate tooth movement might affect to the lip changes^(42,43).

In the current study, all landmarks had more distances changed between the predicted and actual postoperative results of the z- (anterior-posterior) than of the x- (right-left) or y-coordinate (superior-inferior) (Table 5). This may due to the patient's maxilla and/or mandible being moved mainly in antero-posterior directions in order to correct skeletal class II and III discrepancies, this result is accordant with Nam and Hong⁽⁴⁴⁾.

Hsu et al⁽⁴⁵⁾ noted that "The development of computer-assisted surgical simulation (CASS) represents a paradigm shift in surgical planning for patients with cranio-maxillofacial deformities". In cranio-maxillofacial surgery the realistic prediction of a patient's postoperative appearance would give the surgeon a unique feedback during the planning stage. However, even such a sophisticated approach has its limitations. Although the computer-aided surgical simulation (CASS) system has provided an effective process for treatment planning for patients undergoing orthognathic surgery, the biomechanical behavior of different tissue types is highly complex. Consequently, modeling of the non-linear visco-elastic behavior of soft tissue is a key element in accurately predicting the

surgical outcomes.

As all CASS programs are based on algorithms that relate soft tissue responses to the underlying skeletal changes, it is important to realize that computerized prediction of soft tissue profile changes can only be as accurate as the database used. It is, therefore, reasonable to assume that in some cases, an inaccuracy of prediction would be inevitable if the software doesn't incorporate such algorithms. Therefore, the predicted image may be misinterpreted as an implied guarantee of the surgical outcomes with its associated medico-legal implications. The use of informed consent is warranted in today's practice to safeguard the interest of the declaration⁽⁴⁶⁾. Further studies should focus on validating the non-linear soft tissue algorithm for planning orthognathic surgery.

Limitations of the study

Limitations of samples

The present study had a limitation because of a small sample size. Inadequacy of sample size becomes more pertinent in attempting to evaluate the predictive capabilities of the Facemaker® software in separate assessments of the cleft and non-cleft groups, each with only 10 subjects. Therefore, the present study should be repeated by increasing the sample size.

The 20 subjects with class III skeletal problems underwent various surgical procedures: one jaw BSSO mandibular setback (7 subjects, 35%) and two jaw surgery by Le Fort maxillary advancement and BSSO mandibular setback (13 subjects, 65%). Several authors reported bi-maxillary surgery have been shown to be more difficult to predict than single jaw surgery^(37,47,48). It can be suggested that the induced errors in soft tissue simulation would be higher as both the number of jaw segments and the complexity of jaw movements. These errors are increased in 2 jaws surgery.

In addition, the cleft lip and palate (CLCP) subjects can be expected to be more difficult to predict than non-cleft patients, the most having retrognathic maxilla with varying degrees of limitation of upper lip displacement.

Image fusion errors; registration of a 3D photograph upon a 2D digital cephalographs

In a typical 2D cephalogram, hard and soft-tissue images are represented in one image. Therefore, there is no margin of error in the correlation between them. Image fusion involves combining images from different radiographic and photographic imaging modalities to create a virtual 3D record of an individual

and thus a greater challenge in preparing 3D simulations. Maal et al⁽⁴⁹⁾ revealed that 90% of the errors of registration of a 3D photograph upon a CBCT was within ± 1.5 mm based on surface-based registration technique.

In the present study, the accuracy of registering or matching 3D facial photographs upon 2D digital lateral and postero-anterior cephalograms (LC and PAC) was difficult to achieve. The amounts of any error of registration of the radiographs with the 3D facial images will be transferred to errors in producing the surgical simulation⁽⁵⁰⁾. Smoothing the untextured surface or simultaneous acquisition of the 2D digital cephalogram and 3D photograph may partially solve this technical problem.

Conclusion

The Morpheus 3D Facemaker® software was found to be sufficient accuracy in predicting soft tissue changes. This encourages in use of the simulation capabilities among clinicians, and its routine use in patient consultations. However, despite satisfaction in the use of this software to predict the post-operative facial appearance, patients need to be informed that the actual outcome predictions using Morpheus 3D simulation software might not be as accurate as the actual results due to some uncontrollable factors affecting the prediction. Therefore, clinicians must be guarded in making any move towards reliance on surgical simulations such as for managing borderline decisions between one-jaw or two-jaw surgery and the more difficult patients with repaired cleft lip and palate.

What is already known on this topic?

In this present study we cannot say that we were able to predict the surgical outcomes due to the technique used in this study by evaluating the accuracy of the computer software itself but not the quality of the prediction. Further studies might predict surgical outcomes prior to surgery and assess whether surgical outcomes and actual movements are better controlled as predicted surgical outcomes prior to surgery and this study should be repeated by increasing the sample size.

In additional, satisfaction after orthodontic treatments combined with orthognathic surgery comparing with pre-surgical planning consultation should be evaluated because the pre-treatment motivation and perceived social benefits of the treatment outcomes were correlated with post-treatment psychological status and satisfaction.

This is one of the significant motivations to accept the orthodontic-surgical treatment plan.

What this study adds?

This study demonstrated that the soft tissue prediction algorithm provided by the Morpheus 3D Facemaker® software combined with digital cephalometric imaging was found to be sufficiently accurate in predicting soft tissue changes after orthognathic surgery. This encourages more acceptance and confidence in use of the simulation capabilities among clinicians, and its routine use in patient consultations.

Ethical considerations

The study was approved by the Khon Kaen University Ethics Committee for Human Research (KKUEC-HE592128).

Acknowledgements

The Center of Cleft Lip-Cleft Palate and Craniofacial Deformities, Khon Kaen University under Tawanchai Royal Grant Project.

Potential conflicts of interest

None.

References

1. Katiyar R, Singh GK, Mehrotra D, Singh A. Surgical-orthodontic treatment of a skeletal class III malocclusion. *Natl J Maxillofac Surg* 2010; 1: 143-9.
2. Oland J, Jensen J, Elklit A, Melsen B. Motives for surgical-orthodontic treatment and effect of treatment on psychosocial well-being and satisfaction: a prospective study of 118 patients. *J Oral Maxillofac Surg* 2011; 69: 104-13.
3. Takatsuji H, Kobayashi T, Kojima T, Hasebe D, Izumi N, Saito I, et al. Effects of orthognathic surgery on psychological status of patients with jaw deformities. *Int J Oral Maxillofac Surg* 2015; 44: 1125-30.
4. Jones RM, Khambay BS, McHugh S, Ayoub AF. The validity of a computer-assisted simulation system for orthognathic surgery (CASSOS) for planning the surgical correction of class III skeletal deformities: single-jaw versus bimaxillary surgery. *Int J Oral Maxillofac Surg* 2007; 36: 900-8.
5. Smith JD, Thomas PM, Proffit WR. A comparison of current prediction imaging programs. *Am J Orthod Dentofacial Orthop* 2004; 125: 527-36.

6. Kolokitha OE, Topouzelis N. Cephalometric methods of prediction in orthognathic surgery. *J Maxillofac Oral Surg* 2011; 10: 236-45.
7. Chen CM, Lai S, Lee HE, Chen KK, Hsu KJ. Soft-tissue profile changes after orthognathic surgery of mandibular prognathism. *Kaohsiung J Med Sci* 2012; 28: 216-9.
8. Papadopoulos MA, Christou PK, Christou PK, Athanasiou AE, Boettcher P, Zeilhofer HF, et al. Three-dimensional craniofacial reconstruction imaging. *Oral Surg Oral Med Oral Pathol Oral Radiol Endod* 2002; 93: 382-93.
9. Schendel SA, Jacobson R, Khalessi S. 3-dimensional facial simulation in orthognathic surgery: is it accurate? *J Oral Maxillofac Surg* 2013; 71: 1406-14.
10. Swennen GR, Mollemans W, Schutyser F. Three-dimensional treatment planning of orthognathic surgery in the era of virtual imaging. *J Oral Maxillofac Surg* 2009; 67: 2080-92.
11. Alves PV, Mazucheli J, Vogel CJ, Bolognese AM. How the lower face soft tissue changes after mandibular advancement or setback. *J Craniofac Surg* 2008; 19: 593-8.
12. Xia J, Samman N, Yeung RW, Wang D, Shen SG, Ip HH, et al. Computer-assisted three-dimensional surgical planing and simulation. 3D soft tissue planning and prediction. *Int J Oral Maxillofac Surg* 2000; 29: 250-8.
13. Altman DG, Bland JM. Measurement in medicine: the analysis of method comparison studies. *Statistician* 1983; 32: 307-17.
14. Bland JM, Altman DG. Applying the right statistics: analyses of measurement studies. *Ultrasound Obstet Gynecol* 2003; 22: 85-93.
15. Toma AM, Zhurov A, Playle R, Ong E, Richmond S. Reproducibility of facial soft tissue landmarks on 3D laser-scanned facial images. *Orthod Craniofac Res* 2009; 12: 33-42.
16. Ayoub AF, Wray D, Moos KF, Siebert P, Jin J, Niblett TB, et al. Three-dimensional modeling for modern diagnosis and planning in maxillofacial surgery. *Int J Adult Orthodon Orthognath Surg* 1996; 11: 225-33.
17. Heike CL, Upson K, Stuhag E, Weinberg SM. 3D digital stereophotogrammetry: a practical guide to facial image acquisition. *Head Face Med* 2010; 6: 18.
18. Kim YK, Moon SW, Yun PY, Lee YS, Larson BE, Lee NK. Evaluation of soft tissue changes around the lips after mandibular setback surgery with minimal orthodontics using three-dimensional stereophotogrammetry. *J Oral Maxillofac Surg* 2016; 74: 1044-54.
19. Kim YK, Lee NK, Moon SW, Jang MJ, Kim HS, Yun PY. Evaluation of soft tissue changes around the lips after bracket debonding using three-dimensional stereophotogrammetry. *Angle Orthod* 2015; 85: 833-40.
20. Ludlow JB, Timothy R, Walker C, Hunter R, Benavides E, Samuelson DB, et al. Effective dose of dental CBCT-a meta analysis of published data and additional data for nine CBCT units. *Dentomaxillofac Radiol* 2015; 44: 20140197.
21. Kau CH, Richmond S, Palomo JM, Hans MG. Three-dimensional cone beam computerized tomography in orthodontics. *J Orthod* 2005; 32: 282-93.
22. Kim SH, Jung WY, Seo YJ, Kim KA, Park KH, Park YG. Accuracy and precision of integumental linear dimensions in a three-dimensional facial imaging system. *Korean J Orthod* 2015; 45: 105-12.
23. Aynechi N, Larson BE, Leon-Salazar V, Beiraghi S. Accuracy and precision of a 3D anthropometric facial analysis with and without landmark labeling before image acquisition. *Angle Orthod* 2011; 81: 245-52.
24. Baysal A, Sahan AO, Ozturk MA, Uysal T. Reproducibility and reliability of three-dimensional soft tissue landmark identification using three-dimensional stereophotogrammetry. *Angle Orthod* 2016; 86: 1004-9.
25. de Menezes M, Rosati R, Ferrario VF, Sforza C. Accuracy and reproducibility of a 3-dimensional stereophotogrammetric imaging system. *J Oral Maxillofac Surg* 2010; 68: 2129-35.
26. Plooi JM, Swennen GR, Rangel FA, Maal TJ, Schutyser FA, Bronkhorst EM, et al. Evaluation of reproducibility and reliability of 3D soft tissue analysis using 3D stereophotogrammetry. *Int J Oral Maxillofac Surg* 2009; 38: 267-73.
27. Weinberg SM, Scott NM, Neiswanger K, Brandon CA, Marazita ML. Digital three-dimensional photogrammetry: evaluation of anthropometric precision and accuracy using a Genex 3D camera system. *Cleft Palate Craniofac J* 2004; 41: 507-18.
28. Wong JY, Oh AK, Ohta E, Hunt AT, Rogers GF, Mulliken JB, et al. Validity and reliability of craniofacial anthropometric measurement of 3D digital photogrammetric images. *Cleft Palate Craniofac J* 2008; 45: 232-9.
29. Schendel SA, Lane C. 3D Orthognathic surgery simulation using image fusion. *Semin Orthod* 2009;

- 15:48-56.
30. Gwilliam JR, Cunningham SJ, Hutton T. Reproducibility of soft tissue landmarks on three-dimensional facial scans. *Eur J Orthod* 2006; 28: 408-15.
31. Hajeer MY, Ayoub AF, Millett DT, Bock M, Siebert JP. Three-dimensional imaging in orthognathic surgery: the clinical application of a new method. *Int J Adult Orthodon Orthognath Surg* 2002; 17: 318-30.
32. Baik HS, Lee HJ, Lee KJ. A proposal for soft tissue landmarks for craniofacial analysis using 3-dimensional laser scan imaging. *World J Orthod* 2006; 7: 7-14.
33. Xia JJ, Gateno J, Teichgraeber JF, Christensen AM, Lasky RE, Lemoine JJ, et al. Accuracy of the computer-aided surgical simulation (CASS) system in the treatment of patients with complex craniomaxillofacial deformity: A pilot study. *J Oral Maxillofac Surg* 2007; 65: 248-54.
34. Liebrechts J, Xi T, Timmermans M, de Koning M, Berge S, Hoppenreijts T, et al. Accuracy of three-dimensional soft tissue simulation in bimaxillary osteotomies. *J Craniomaxillofac Surg* 2015; 43: 329-35.
35. Marchetti C, Bianchi A, Muyldermans L, Di Martino M, Lancellotti L, Sarti A. Validation of new soft tissue software in orthognathic surgery planning. *Int J Oral Maxillofac Surg* 2011; 40: 26-32.
36. Xia JJ, Gateno J, Teichgraeber JF, Christensen AM, Lasky RE, Lemoine JJ, et al. Accuracy of the computer-aided surgical simulation (CASS) system in the treatment of patients with complex craniomaxillofacial deformity: A pilot study. *J Oral Maxillofac Surg* 2007; 65: 248-54.
34. Jacobson R, Sarver DM. The predictability of maxillary repositioning in LeFort I orthognathic surgery. *Am J Orthod Dentofacial Orthop* 2002; 122: 142-54.
35. Kaipatur NR, Flores-Mir C. Accuracy of computer programs in predicting orthognathic surgery soft tissue response. *J Oral Maxillofac Surg* 2009; 67: 751-9.
36. Nadjmi N, Defrancq E, Mollemans W, Hemelen GV, Berge S. Quantitative validation of a computer-aided maxillofacial planning system, focusing on soft tissue deformations. *Ann Maxillofac Surg* 2014; 4: 171-5.
37. Mollemans W, Schutyser F, Nadjmi N, Maes F, Suetens P. Predicting soft tissue deformations for a maxillofacial surgery planning system: from computational strategies to a complete clinical validation. *Med Image Anal* 2007; 11: 282-301.
38. Day CJ, Robert T. Three-dimensional assessment of the facial soft tissue changes that occur postoperatively in orthognathic patients. *World J Orthod* 2006; 7: 15-26.
39. Amit G, Jps K, Pankaj B, Suchinder S, Parul B. Periodontally accelerated osteogenic orthodontics (PAOO) - a review. *J ClinExp Dent* 2012; 4: e292-6.
40. Verna C. Regional Acceleratory Phenomenon. *Front Oral Biol* 2016; 18: 28-35.
41. Nam KU, Hong J. Is Three-Dimensional Soft Tissue Prediction by Software Accurate? *J Craniofac Surg* 2015; 26: e729-33.
42. Hsu SS, Gateno J, Bell RB, Hirsch DL, Markiewicz MR, Teichgraeber JF, et al. Accuracy of a computer-aided surgical simulation protocol for orthognathic surgery: a prospective multicenter study. *J Oral Maxillofac Surg* 2013; 71: 128-42.
43. Chew MT, Koh CH, Sandham A, Wong HB. Subjective evaluation of the accuracy of video imaging prediction following orthognathic surgery in Chinese patients. *J Oral Maxillofac Surg* 2008; 66: 291-6.
44. Eckhardt CE, Cunningham SJ. How predictable is orthognathic surgery? *Eur J Orthod* 2004; 26: 303-9.
45. Koh CH, Chew MT. Predictability of soft tissue profile changes following bimaxillary surgery in skeletal class III Chinese patients. *J Oral Maxillofac Surg* 2004; 62: 1505-9.
46. Maal TJ, Plooij JM, Rangel FA, Mollemans W, Schutyser FA, Berge SJ. The accuracy of matching three-dimensional photographs with skin surfaces derived from cone-beam computed tomography. *Int J Oral Maxillofac Surg* 2008; 37: 641-6.
47. Naudi KB, Benramadan R, Brocklebank L, Ju X, Khambay B, Ayoub A. The virtual human face: superimposing the simultaneously captured 3D photorealistic skin surface of the face on the untextured skin image of the CBCT scan. *Int J Oral Maxillofac Surg* 2013; 42: 393-400.

ความเที่ยงตรงของการทำนายเนื้อเยื่ออ่อนด้วย Morpheus 3D ซอฟต์แวร์โดยการจำลองใบหน้าเพื่อวางแผนการผ่าตัดกระดูกขากรรไกร

กิริติญา ไตรศรีศิลป์, ทศนีย์ วังศรีมงคล, พูนศักดิ์ ภิสเอก, ภัทธมน รัตนพันธุ์, สุบิน พัวศิริ

วัตถุประสงค์: เพื่อประเมินความเที่ยงตรงของการจำลองใบหน้าแบบภาพสามมิติ โดยใช้ Morpheus 3D ซอฟต์แวร์ ในการเปรียบเทียบค่าความคลาดเคลื่อนของตำแหน่ง 17 จุดบนเนื้อเยื่ออ่อนระหว่างการจำลองใบหน้าแบบ 3 มิติ และภาพผู้ป่วยจริงแบบ 3 มิติ

วัสดุและวิธีการ: ทำการถ่ายภาพใบหน้า 3 มิติ ก่อนผ่าตัดภายใน 1 เดือน และหลังผ่าตัด 3 เดือน ของอาสาสมัคร 20 คน (อายุเฉลี่ย, 24 ± 5.13 ปี) ภาพ 3 มิติเสมือนจริงที่ได้จากการรวมภาพของภาพถ่ายรังสีเซฟาโลเมตริกแบบดิจิตอล และภาพ 3 มิติที่สแกนก่อนการผ่าตัดถูกจัดทำขึ้น การผ่าตัดจำลองใบหน้าที่จะเป็นไปได้หลังการผ่าตัดถูกออกแบบด้วย Morpheus Facemaker® ซอฟต์แวร์ จากนั้นนำภาพ 3 มิติที่เกิดจากการจำลองใบหน้าหลังผ่าตัดและภาพ 3 มิติจริง หลังผ่าตัดมาทำการเปรียบเทียบ โดยใช้ 17 จุดบนเนื้อเยื่ออ่อนรอบปากและจมูกโดยใช้การคำนวณทางสถิติ paired t-tests ($p < 0.05$) ในการวิเคราะห์ข้อมูลพร้อมทั้งมีการประเมินผลการตรวจสอบภายในของการทำซ้ำของการกำหนดจุด ของเนื้อเยื่ออ่อนโดยใช้การประเมินแบบ Bland-Altman Limits of Agreement

ผลการศึกษา: จากอาสาสมัครทั้ง 20 คน ไม่พบความแตกต่างอย่างมีนัยสำคัญทางสถิติ ทั้ง 3 แนวแกน (x, y and z) ตำแหน่งทั้ง 17 จุดเมื่อทำการเปรียบเทียบภาพ 3 มิติหลังการผ่าตัดโดยใช้ Morpheus 3D ซอฟต์แวร์กับภาพใบหน้า 3 มิติ จริงของผู้ป่วยหลังจากผ่าตัดกระดูกขากรรไกร ร่วมกับการจัดฟัน ยกเว้นจุดบริเวณกึ่งกลางริมฝีปากบน (Ls and Stms) แสดงความแตกต่างอย่างมีนัยสำคัญทางสถิติในแนวหน้าหลัง (ค่าเฉลี่ย 0.98 mm and 1.30 mm, ตามลำดับ)

สรุป: ขั้นตอนวิธีการทำนายเนื้อเยื่ออ่อนภายหลังการผ่าตัดโดย Morpheus 3D Facemaker ซอฟต์แวร์ ถูกพบว่ามี ความถูกต้องเพียงพอในการทำนายการเปลี่ยนแปลงของเนื้อเยื่ออ่อนหลังการผ่าตัดกระดูกขากรรไกร การศึกษานี้จะช่วยเพิ่มการยอมรับและความเชื่อมั่นมากขึ้นในการใช้ความสามารถนี้ในการจำลองเนื้อเยื่ออ่อน ภายหลังการผ่าตัดในกลุ่มแพทย์ผู้ทำการศึกษาและในงานประจำที่ให้คำปรึกษาผู้ป่วยก่อนการผ่าตัด
