

Pedicled Latissimus Dorsi Muscle Flap in Thoracic Surgery

Montien Ngodngamthaweek MD*, Chanawit Sitthisombat MD**

* Division of Cardiothoracic Surgery, Department of Surgery, Faculty of Medicine Ramathibodi Hospital, Mahidol University, Bangkok, Thailand

** Division of Cardiothoracic Surgery, Department of Surgery, Chiangrai Prachanukroh Hospital, Chiang Rai, Thailand

Background: Bronchopleural fistula and empyema are serious complications after thoracic surgery and their prevention is very important. The use of transposed extrathoracic muscle flaps to cover bronchial stumps and to eliminate dead space is a good management technique.

Objective: Evaluate the efficacy and safety of a pedicled latissimus dorsi (PLD) muscle flap in high-risk thoracic surgery.

Material and Method: This retrospective study was performed between July 2008 and December 2013 in 17 patients who underwent PLD muscle flap and decortication or bullectomy. These patients were divided into three groups from their diseases. The first group (empyema) was eleven patients (7 men, 16- to 78-year-old). The second group (spontaneous pneumothorax, bullae, and COPD) was five patients (5 men, 42- to 81-year-old), and the third group (malignant pleural effusion) was one patient (woman, 57-year-old).

Results: In the first group (empyema), there were three postoperative death from eleven patients (27.27%) (two with septic shock from pneumonia with lung cancer stage IV and pulmonary tuberculosis and one with congestive heart failure with severe aortic stenosis) after decortication and PLD muscle flap. Additionally, six patients required packed red blood cells, about 270 mL per patient and eight patients needed intensive care unit (ICU) for 1 to 9 days (mean = 2.38 days). Mean length of hospital stay was 13.27 days (7 to 40 days). In the second group (spontaneous pneumothorax, bullae and COPD) there were no morbidity and mortality after bullectomy, pleurectomy, and PLD muscle flap. Two patients needed ICU for a day. In the third group (malignant pleural effusion from breast cancer), there was one postoperative death (100%) from sudden cardiac arrest after decortication and PLD muscle flap.

Conclusion: The use of pedicled latissimus dorsi muscle flap is effective and safe in high-risk thoracic surgery for the obliteration of chronically infected pleural space and prevention of bronchopleural fistula.

Keywords: Pedicled latissimus dorsi (PLD) muscle flap, Bronchopleural fistula, Empyema

J Med Assoc Thai 2017; 100 (Suppl. 9): S40-S46

Full text. e-Journal: <http://www.jmatonline.com>

Bronchopleural fistula (BPF) and empyema after pulmonary resections are dangerous complications. The incidence of postoperative BPF is 1.5% to 28%⁽¹⁻³⁾, which has been related to the cause of disease, surgical technique, and experience of the surgeons^(4,5). The incidence of empyema after pulmonary surgery is 2% to 16%^(6,7). The postoperative BPF and recurrent empyema are high morbidity and mortality. The prevention of postoperative complications is paramount. The use of transposed extrathoracic muscle flaps to cover bronchial stumps to eliminate dead space is a well-established management.

Correspondence to:

Ngodngamthaweek M, Division of Thoracic Surgery, Department of Surgery, Ramathibodi Hospital, Mahidol University, Bangkok 10400, Thailand
Phone: +66-2-2011315, Fax: +66-2-2011316
E-mail: montien.ngo@mahidol.ac.th

We have used the pedicle latissimus dorsi (PLD) muscle flap as our preferred flap in high-risk thoracic surgery patients who have under decortication, bullae, resection procedures. The latissimus dorsi muscle is the largest muscle in the body, up to 20 by 40 centimeters, and there is no significant donor functional deficit resulting from removal of the muscle. Here, we review our experience with this technique in 17 patients and their clinical outcomes.

Material and Method

This retrospective study was performed by review of medical records between July 2008 and December 2013 at Ramathibodi Hospital. All patients had undergone posterolateral thoracotomies and pedicled latissimus dorsi muscle flaps at our institution for decortication from chronic empyema and malignant pleural effusion from breast cancer,

bullectomy from spontaneous pneumothorax with chronic obstructive pulmonary disease (COPD). We noted the characteristics of the patients, the preoperative diagnosis, type of procedures, estimated blood loss, blood transfusion requirements, postoperative complications, length of stay (LOS) in intensive care unit, and LOS in hospital. Committee Human subject, Ramathibodi Hospital, Mahidol University on May 23, 2014 (ED 05-57-32).

Technique

The patient is placed in the lateral decubitus position on a beanbag, with an axillary roll placed in the dependent axilla. The latissimus border is outlined with a marking pen (Fig. 1). The incision is a standard posterolateral thoracotomy.

Anterior and posterior flaps are raised superficial to the muscle to expose the latissimus. A small amount of muscular fascia can be left on the latissimus, but this is not necessary. The skin and fat flaps are elevated to the extent of the pocket necessary for adequate muscle size harvest.

The superior edge of the latissimus is identified at the inferior angle of the scapula. The superior of the latissimus, below the inferior angle of the scapula is then elevated (Fig. 2).

This areolar plane is easy to dissect, and any large caliber perforators can be ligated and divided. The dissection is then directed toward the midline, and the insertion of the muscle near the midline of back is divided. The dissection proceeds inferiorly freeing the medial muscle insertion. After the medial and inferior part of muscle are released, the dissection proceeded toward the axilla. The vessels to the latissimus is preserved. The pedicled latissimus dorsi muscle is moved into the ipsilateral pleural space via a thoracotomy site (Fig. 3, 4).

Results

We identified 17 patients (12 men, age range 16 to 81 years) in whom the ipsilateral PLD muscle flap was done. The characteristics of the patients is shown in Table 1. There were three groups of characteristic of patients and result of operations. In the first group (empyema), there was three postoperative death out of eleven patients (27.27%) (two patients with septic shock from pneumonia with lung cancer stage IV and pulmonary tuberculosis and one patient with congestive heart failure with severe aortic stenosis) after decortication and PLD muscle flap. The average estimated blood loss was 350 mL. Six patients required

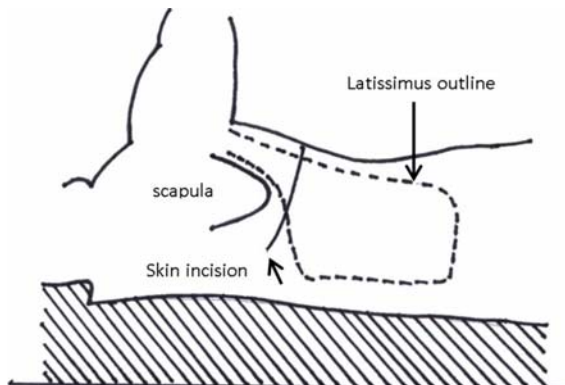


Fig. 1 The patient is marked in the lateral decubitus position for the extent of the muscle and skin incision for thoracotomy.

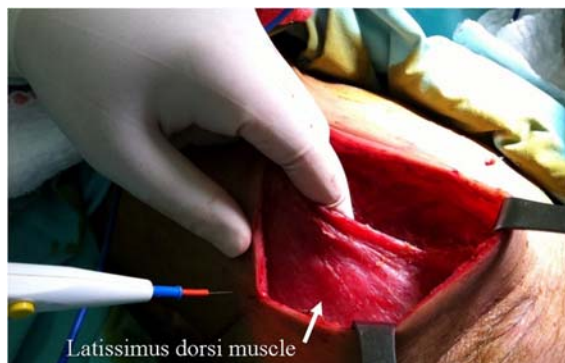

Fig. 2 The superior edge of the latissimus dorsi muscle is elevated.

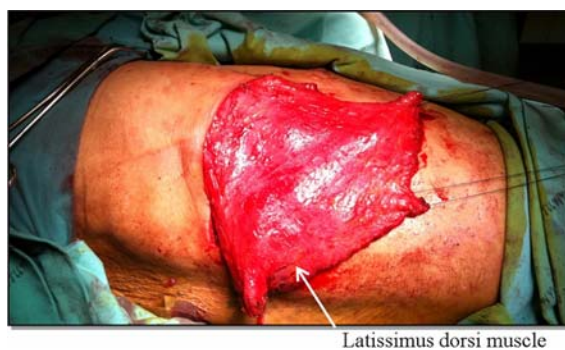

Fig. 3 The latissimus dorsi muscle harvest is complete.

transfusion of an average of 270 mL of packed red blood cells (PRC) per patient and eight patients needed ICU for 1 to 9 days (mean = 2.38 days). Mean length of hospital stay was 13.27 days (7 to 40 days).

In the second group (spontaneous pneumothorax, bullae, and COPD), there were no

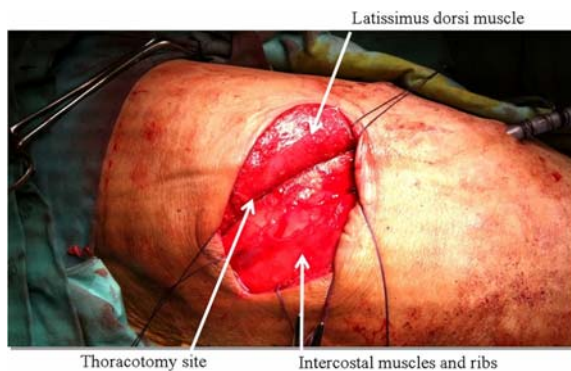


Fig. 4 The pedicled latissimus dorsi muscle is moved into the ipsilateral pleural space via a thoracotomy site.

morbidity and mortality after bullectomy, pleurectomy, and PLD muscle flap. The average estimated blood loss was 150 mL. No patients needed a blood transfusion. Two patients needed ICU for a day. Mean length of hospital stay was 14.6 days (7 to 35 days).

In the third group (malignant pleural effusion), there was one patient with breast cancer who needed decortication and PLD muscle flap due to trapped lung syndrome after insertion of chest drain. She needed PRC transfusion about 520 mL during operation. She died from sudden cardiac arrest on the seventh postoperative day.

Discussion

In the thoracic surgery, several studies show that patients with immunosuppressive disorders such as preoperative chemotherapy have a higher tendency to develop bronchopleural fistula and empyema after pulmonary resection⁽⁸⁾. Chronic malnutrition, severe chronic obstructive pulmonary disease, and other underlying parenchymal lung diseases are additional risk factors⁽⁸⁾. Thoracic surgeons face many problems when patients present with chronic primary empyema from an inadequately treated parapneumonic effusion. The standard treatment of chronic primary empyema is total pleural decortication, obliteration of the empyema cavity, coverage of the raw parenchymal surface with viable tissue, and effective pleural drainage.

In 1911, Abrashanoff⁽⁹⁾ described the use of intrathoracic muscle transposition in the treatment of BPF. Many thoracic surgeons used extrathoracic muscle flaps to treat difficult pleural space infections and to buttress the repair of BPF.

The chest wall skeletal muscles, including the intercostals, latissimus doris, pectoralis major, and serratus anterior muscles, have been transposed most

frequently⁽¹⁰⁻¹²⁾. In addition, the rectus abdominis muscle and pedicled omentum have also been used successfully^(13,14).

In elective surgery in low-risk patients, transposing an intercostal muscle flap to cover a bronchial stump after lobectomy or pneumonectomy because it is easy to harvest, and it avoids additional incisions, is done frequently.

However, in chronic infectious or inflammatory pulmonary conditions and consequential pleural symphysis, it precludes the use of intercostal muscle flaps. These thoracotomies commonly require extrapleural dissection to mobilize the underlying lung. Thus, preserving an intact, well-vascularized intercostal muscle flap is problematic. In addition, intercostal muscle is of inadequate bulk to obliterate the fibrotic, infected bed of resection. Therefore, in these situations, transposition of extrathoracic muscle is preferred. We believe that the PLD muscle is the most suitable flap because there is enough length and bulk to reach the desired intrapleural location and obliterate the infected pleural space, not affecting a patient's shoulder or arm function. In contrast, the serratus anterior and pectoralis major muscles are not entirely expandable and functional disability or physical deformity may result if they are harvested.

The rectus abdominis muscle and omentum are generally the last flaps to be considered for intrathoracic transposition. Furthermore, harvesting an omental flap requires entry into the peritoneal cavity. The risks of bleeding, infection, and injury to visceral organs are great. Finally, the rectus abdominis muscle is thin and may result in hernia formation or substantial deformity of the abdominal wall. In our patients population, there are three groups. The first group (empyema) had three postoperative death out of eleven (27.27%) (two patients with septic shock from pneumonia with lung cancer stage IV and pulmonary tuberculosis and one patient with congestive heart failure with severe aortic stenosis). In case of pneumothorax, bullae, and COPD, we used PLD muscle flap to reduce pleural space like a pleural tent⁽¹⁵⁾ when the lung did not appear to be large enough to fill the entire space. In addition, this flap was useful to improve airtightness to prevent air leakage. Other techniques designed to improved airtightness and minimize leakage from the suture are polydio-xianone ribbon⁽¹⁶⁾, teflon strips⁽¹⁷⁾, and bovine pericardial strips⁽¹⁸⁾. The second group (spontaneous pneumothorax, bullae, and COPD) had no morbidity and mortality. The malignant pleural effusion, the pleurectomy should be reserved for

Table 1. Characteristic of the patients, Clinical diagnosis, Postoperative complications, Length of stay in Intensive care unit and hospital and results

No.	Age (years) /sex	Underlying diseases	Type of procedures	Estimated blood loss (mL)	Blood transfusion (PRC) (mL)	Duration of intubation (days)	Postoperative complications	Length of stay in ICU (days)	Length of stay in hospital (days)	Result
First Group (Empyema)										
1	33/male	Pulmonary TB	Decortication	200	-	-	-	1	10	Improved
2	59/male	Pulmonary TB Non-Insulin dependent DM	Decortication	250	-	-	-	-	7	Improved
3	57/Female	Pulmonary TB Non-Insulin dependent DM	Decortication	200	-	-	-	-	10	Improved
4	52/male	Chronic malnutrition Lung abscess	Decortication Lung abscess Resection	250	-	-	-	2	40	Improved
5	51/Female	Lung cancer stage IV Preoperative chemotherapy	Decortication	400	220	-	-	1	12	Improved
6	70/male	Chronic malnutrition Lung cancer stage IV Pulmonary TB COPD	Decortication	750	520	13	Pneumonia and septic shock	1	13	Death
7	70/Female	Chronic malnutrition Lung cancer stage IV Pulmonary TB	Decortication	500	220	8	Pneumonia and septic shock	1	8	Death
8	55/male	Chronic malnutrition Lung cancer stage IV HT	Decortication	300	220	1	-	3	7	Improved
9	78/Female	Chronic malnutrition Severe aortic stenosis	Decortication	300	220	9	Congestive heart failure	9	9	Death
10	62/male	Hepatoma	Decortication	500	220	-	-	1	20	Improved
11	16/male	Post encephalitis Mental retardation	Decortication	200	-	-	-	-	10	Improved

TB = Tuberculosis; DM = Diabetes mellitus; HT = Hypertension; COPD = Chronic obstructive pulmonary disease; ICU = Intensive care unit; PRC = packed red blood cell. Chronic malnutrition was defined as a preoperative serum albumin level <3 g/dL

Table 1. Cont.

No.	Age (years) /sex	Underlying diseases	Type of procedures	Estimated blood loss (mL)	Blood transfusion (PRC) (mL)	Duration of intubation (days)	Postoperative complications	Length of stay in ICU (days)	Length of stay in hospital (days)	Result
Second Group (spontaneous pneumothorax, bullae and COPD)										
1	47/male	Pulmonary TB	Bullectomy and pleurectomy	200	-	-	-	-	8	Improved
2	72/male	Bronchiectasis COPD	Bullectomy and pleurectomy	100	-	1	-	-	7	Improved
3	81/male	COPD	Bullectomy and pleurectomy	150	-	1	-	-	35	Improved
4	42/male	Malnutrition COPD	Bullectomy and pleurectomy	150	-	-	-	-	11	Improved
5	57/male	COPD	Bullectomy and pleurectomy	150	-	-	-	-	12	Improved
Third Group (Malignant pleural effusion)										
1	57/Female	Breast cancer stage IV Chronic malnutrition Trapped lung syndrome after insertion of chest drain	Decortication	1,000	520	2	Sudden cardiac arrest	1	7	Death

TB = Tuberculosis; DM = Diabetes mellitus; HT = Hypertension; COPD = Chronic obstructive pulmonary disease; ICU = Intensive care unit; PRC = packed red blood cell. Chronic malnutrition was defined as a preoperative serum albumin level <3 g/dL

patients with an expected survival of at least six months who have a trapped lung or who have failed pleurodesis^(19,20). PLD muscle flap was used for an additional procedure to reduce pleural space and bronchopleural fistulae after decortication and lung injury. The third group (malignant pleural effusion from breast cancer) had a postoperative death, which was the only patient in this group, (100%). It was from sudden cardiac arrest.

What is already known on this topic? and What this study adds?

We believe that the use of a PLD muscle flap enables the obliteration of non-infected or chronically infected pleural space and reduces the chance of bronchopleural fistula in our high-risk thoracic operations. Although our study was retrospective and limited by the quantity of our patients, we consider the good outcomes and low mortality rate in our high-risk patients to be very encouraging.

Potential conflicts of interest

None.

References

1. Cerfolio RJ. The incidence, etiology, and prevention of postresectional bronchopleural fistula. *Semin Thorac Cardiovasc Surg* 2001; 13:3-7.
2. Sirbu H, Busch T, Aleksic I, Schreiner W, Oster O, Dalichau H. Bronchopleural fistula in the surgery of non-small cell lung cancer: incidence, risk factors, and management. *Ann Thorac Cardiovasc Surg* 2001; 7: 330-6.
3. Turk AE, Karanas YL, Cannon W, Chang J. Staged closure of complicated bronchopleural fistulas. *Ann Plast Surg* 2000; 45: 560-4.
4. al Kattan K, Cattelani L, Goldstraw P. Bronchopleural fistula after pneumonectomy for lung cancer. *Eur J Cardiothorac Surg* 1995; 9: 479-82.
5. Conlan AA, Lukanich JM, Shutz J, Hurwitz SS. Elective pneumonectomy for benign lung disease: modern-day mortality and morbidity. *J Thorac Cardiovasc Surg* 1995; 110: 1118-24.
6. Pairolero PC, Trastek VF, Allen MS. Empyema and bronchopleural fistula. *Ann Thorac Surg* 1991; 51: 157-8.
7. Deschamps C, Bernard A, Nichols FC 3rd, Allen MS, Miller DL, Trastek VF, et al. Empyema and bronchopleural fistula after pneumonectomy: factors affecting incidence. *Ann Thorac Surg* 2001; 72:243-7.
8. Sonobe M, Nakagawa M, Ichinose M, Ikegami N, Nagasawa M, Shindo T. Analysis of risk factors in bronchopleural fistula after pulmonary resection for primary lung cancer. *Eur J Cardiothorac Surg* 2000; 18: 519-23.
9. Abrashanoff X. Plastische methods des schliessung von fistel-gangen, welche von inneren organen Kommen. *Zentralbl Chir* 1911; 38: 186-91. [in German]
10. Cerfolio RJ, Bryant AS, Yamamuro M. Intercostal muscle flap to buttress the bronchus at risk and the thoracic esophageal-gastric anastomosis. *Ann Thorac Surg* 2005; 80: 1017-20.
11. Meyer AJ, Krueger T, Lepori D, Dusmet M, Aubert JD, Pasche P, et al. Closure of large intrathoracic airway defects using extrathoracic muscle flaps. *Ann Thorac Surg* 2004; 77: 397-404.
12. Chan EC, Lee TW, Ng CS, Wan IY, Sihoe AD, Yim AP. Closure of postpneumonectomy bronchopleural fistula by means of single, perforator-based, latissimus dorsi muscle flap. *J Thorac Cardiovasc Surg* 2002; 124: 1235-6.
13. Hochberg J, Ardenghy M, Yuen J, Graeber GM, Warden HE, Gonzalez-Cruz R, et al. Utilization of muscle flaps in the treatment of bronchopleural fistulas. *Ann Plast Surg* 1999; 43: 484-92.
14. Chichevatov D, Gorshenev A. Omentoplasty in treatment of early bronchopleural fistulas after pneumonectomy. *Asian Cardiovasc Thorac Ann* 2005; 13: 211-6.
15. Miscall L, Duffy RW. Surgical treatment of bullous emphysema; contributions of angiocardiology. *Dis Chest* 1953; 24: 489-99.
16. Juettner FM, Kohek P, Pinter H, Klepp G, Friehs G. Reinforced staple line in severely emphysematous lungs. *J Thorac Cardiovasc Surg* 1989; 97: 362-3.
17. Connolly JE, Wilson A. The current status of surgery for bullous emphysema. *J Thorac Cardiovasc Surg* 1989; 97: 351-61.
18. Cooper JD. Technique to reduce air leaks after resection of emphysematous lung. *Ann Thorac Surg* 1994; 57: 1038-9.
19. Martini N, Bains MS, Beattie EJ Jr. Indications for pleuroctomy in malignant effusion. *Cancer* 1975; 35: 734-8.
20. Fry WA, Khandekar JD. Parietal pleuroctomy for malignant pleural effusion. *Ann Surg Oncol* 1995; 2: 160-4.

การใช้กล้ามเนื้อ *Latissimus Dorsi* ในการผ่าตัดทรวงอก

มณเฑียร งดงามทวิสุข, ขาววิทย์ สิทธิสมบัติ

ภูมิหลัง: ทางต่อของหลอดลมกับช่องเยื่อหุ้มปอดและหนองในช่องเยื่อหุ้มปอด เป็นภาวะแทรกซ้อนที่มีอันตรายมากหลังผ่าตัดทรวงอก ดังนั้นการป้องกันการเกิดภาวะแทรกซ้อนดังกล่าวจึงมีความสำคัญอย่างมาก การใช้กล้ามเนื้อผนังทรวงอกเพื่อปิดหลอดลมที่เย็บปิดและการลดลงของช่องว่างในช่องเยื่อหุ้มปอดเป็นวิธีการที่คืออย่างหนึ่งในการรักษา

วัตถุประสงค์: การศึกษาประสิทธิภาพและความปลอดภัยของการใช้กล้ามเนื้อ *Latissimus dorsi* ในการผ่าตัดทรวงอก

วัสดุและวิธีการ: เป็นการศึกษาแบบย้อนหลังจากเวชระเบียนเริ่มตั้งแต่เดือนกรกฎาคม พ.ศ. 2551 ถึง เดือนธันวาคม พ.ศ. 2556 ในผู้ป่วย 17 ราย ที่ใช้กล้ามเนื้อ *Latissimus dorsi* ร่วมกับเอาหนองและเยื่อหุ้มปอดที่รั่วปอดออกหรือตัดถุงลมโป่งพองขนาดใหญ่ออกโดยแบ่งผู้ป่วยเป็น 3 กลุ่ม จากโรคของผู้ป่วย โดยกลุ่มที่หนึ่ง (หนองในช่องเยื่อหุ้มปอด) มี 11 ราย (7 ราย เป็นเพศชาย และช่วงอายุ 16 ถึง 78 ปี) กลุ่มที่สอง (ลมในช่องเยื่อหุ้มปอด, ถุงลมโป่งพองขนาดใหญ่และโรคหลอดลมปอดอุดกั้นเรื้อรัง) มี 5 ราย (เพศชายทั้งหมด และช่วงอายุ 42 ถึง 81 ปี) และกลุ่มที่สาม (สารเหลวและมะเร็งในช่องเยื่อหุ้มปอด) มี 1 ราย (เพศหญิง และอายุ 57 ปี)

ผลการศึกษา: กลุ่มที่หนึ่ง (หนองในช่องเยื่อหุ้มปอด) มี 3 ใน 11 ราย (27.77%) เสียชีวิตหลังผ่าตัดโดย 2 ราย จากการติดเชื้อจากปอดอักเสบ, มะเร็งปอดระยะที่สี่ และวัณโรคปอด และ 1 ราย จากหัวใจล้มเหลวและลิ้นหัวใจ aortic valve ตีบมาก หลังผ่าตัดเอาหนองและเยื่อหุ้มปอดที่รั่วปอดออก และใช้กล้ามเนื้อ *Latissimus dorsi* 6 ราย ได้รับเลือดชนิด packed red blood cells ประมาณ 270 mL ต่อคน, 8 ราย ได้นอนรักษาในหออภิบาลผู้ป่วยหนักนาน 1 ถึง 9 วัน (เฉลี่ย 2.38 วัน) และระยะเวลาอนรักษาในโรงพยาบาลเฉลี่ย 13.27 วัน (7 ถึง 40 วัน) กลุ่มที่สอง (ลมในช่องเยื่อหุ้มปอด, ถุงลมโป่งพองในปอดขนาดใหญ่ และโรคหลอดลมปอดอุดกั้นเรื้อรัง) มี 5 ราย โดยไม่มีภาวะแทรกซ้อนและเสียชีวิต หลังผ่าตัดถุงลมโป่งพองในปอดออก, ลอกเยื่อหุ้มปอดด้านผนังทรวงอกออกและใช้กล้ามเนื้อ *Latissimus dorsi* 2 ราย ต่อนอนรักษาในหออภิบาลผู้ป่วยหนักนาน 1 วัน และระยะเวลาอนรักษาในโรงพยาบาลเฉลี่ย 14.6 วัน (7 ถึง 35 วัน) กลุ่มที่สาม (สารเหลวและมะเร็งในช่องเยื่อหุ้มปอด) จากมะเร็งเต้านมแล้วปอดไม่ขยาย หลังใส่ท่อระบายทรวงอก และผู้ป่วยเสียชีวิต (100%) จากหัวใจหยุดเต้นฉับพลันในวันที่ 7 หลังผ่าตัดเอาเยื่อหุ้มปอดที่รั่วปอดออกและใช้กล้ามเนื้อ *Latissimus dorsi*

สรุป: การใช้กล้ามเนื้อ *Latissimus dorsi* มีประสิทธิภาพและปลอดภัยในผู้ป่วยที่มีความเสี่ยงสูงในการผ่าตัดทรวงอก สำหรับปิดช่องว่างของช่องเยื่อหุ้มปอดที่ไม่ติดหรือติดเชื้อเรื้อรัง และป้องกันการเกิดทางต่อของหลอดลมกับช่องเยื่อหุ้มปอด
