

# A Woman with Sudden Bilateral Sensorineural Hearing Loss after Treatment Psoriasis with Acitretin

Visan Mahasitthiwat, MD\*

\* Department of Ophthalmology and Oto-Rhino-Laryngology, Faculty of Medicine,  
Srinakharinwirot University, Nakhon-Nayok

A case of psoriasis presented with sudden simultaneous bilateral sudden sensorineural hearing loss after taking oral acitretin. Audiogram showed bilateral symmetrical sensorineural hearing loss. Her symptom improved after a short course of prednisolone. It is suggested that acitretin may affect hearing acuity.

**Keywords:** Ototoxic drug, Sudden sensorineural hearing loss, Acitretin

*J Med Assoc Thai* 2005; 88(Suppl 1): S79-81

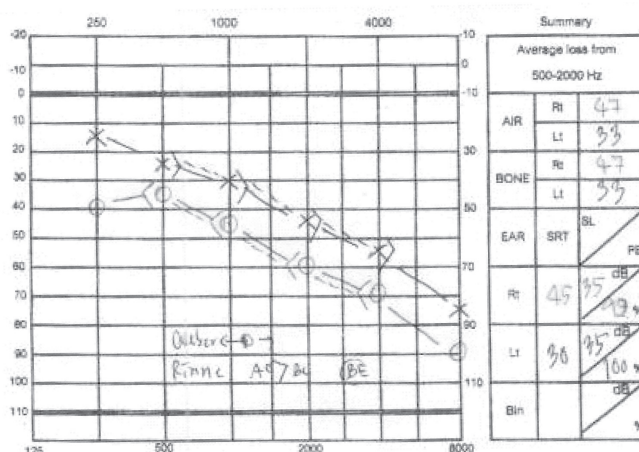
**Full text. e-Journal:** <http://www.medassocthai.org/journal>

Sudden bilateral sensorineural hearing loss is not common in clinical practice, and the causes from the new drugs are rare. This report presents a case with difficulty hearing after treatment of psoriasis with acitretin.

## Case Report

A 31-year-old Thai woman presented with the complaint of reduction of hearing perception and tinnitus in both ears, more severe in the right side. Her symptom progressed in one week after receiving

acitretin for control of her psoriasis. She denied dizziness, head trauma, headache and fever. There was no history of diabetes mellitus, hypertension, thyroid disorder, migraine, and autoimmune diseases. Physical examination including otologic and neurologic examination was unremarkable. Audiogram showed bilateral near symmetrical downward pattern of sensorineural hearing loss (Fig. 1). Pure tone average was 47 dB on right and 33 dB on left. Speech discrimination scores were 92% and 100% on right and left ear respectively. She was treated with 1 mg/



**Fig. 1** Bilateral sensorineural hearing loss

Correspondence to : Mahasitthiwat V , Department of Ophthalmology and Oto-Rhino-Laryngology, Faculty of Medicine, Srinakharinwirot University, HRH Princess Maha Chakri Sirindhorn Medical Center, Nakhon-Nayok 26120, Thailand.



**Table 1.** Audiograms

| Date        | Pure tone average |      | Speech reception threshold |      |
|-------------|-------------------|------|----------------------------|------|
|             | Right             | Left | Right                      | Left |
| 12 Jun 2003 | 47                | 33   | 45                         | 30   |
| 8 Sep 2003  | 40                | 33   | 40                         | 33   |
| 5 Oct 2003  | 35                | 30   | 35                         | 25   |
| 6 Feb 2005  | 35                | 30   | 30                         | 25   |

kg/day of orally route prednisolone and tapering off in one week. She was follow up lost to for about 4 months because she was not able to leave her young daughter alone at home. Although she still took a reduced dose of acitretin, she felt slight improvement of hearing in the right ear and markedly decrease tinnitus on her second visit. Repeated audiogram showed puretone average of 40 dB on right and 33 dB on left. All of the results of the audiograms are presented in Table 1. In the last visit, there was greater improvement of her hearing. In addition, she had no interpersonal communication problem and no tinnitus. Her psoriasis has been successfully controlled with a full course of acitretin.

### Discussion

Acitretin<sup>(1)</sup> is the second generation oral aromatic retinoid. This drug has been effective for treatment of severe keratinizing skin lesions such as psoriasis and ichthyosis since the early 1980s. Its adverse effects<sup>(2)</sup> are hepatotoxic and teratogenic effects. Moreover, hypervitaminosis A<sup>(3-5)</sup> which presents as mucocutaneous lesions, hyperostosis of skeleton, and ligament calcification is also included. The metabolite of acitretin named Etretnate<sup>(6)</sup> can cause myopathy with peripheral neuropathy. A recent report from Greece<sup>(6,7)</sup> showed 2 cases of peripheral sensory neuropathy. At present, there is no literature demonstrating sensorineural hearing loss from acitretin. The presented patient developed simultaneous bilateral sudden sensorineural hearing loss

after taking acitretin and improved after changing to a reduced dose. Without evidence of other causes, it is suggested that acitretin should be considered as a possible ototoxic drug.

### Reference

1. Barbis P. Acitretin. *Ann Dermatol Veneral* 2001; 128: 737-45.
2. Katz HI, Waalen J, Leach EE. Acitretin in psoriasis: an overview of adverse effects. *J Am Acad Dermatol* 1990; 41: S7-12.
3. Kullavanijaya P, Kulthanan K. Clinical efficacy and side effected of acitretin on the disorder of keratinization: a one-year study. *J Dermatol* 1993; 20: 501-6.
4. Orfanos CE. Treatment of psoriasis with retinoids: present status. *Cutis* 1999; 64: 347-55.
5. Magis NL, Blummel JJ, Kerkhof PC, Gerritsen RM. The treatment of psoriasis with etretinate and acitretin: a follow up of actual use. *Eur J Dermatol* 2000; 10: 517-21.
6. Tsambaos D, Sakkis T, Chroni E, Koniavitou K, Monastirli A. Peripheral sensory neuropathy associated with short-term oral acitretin therapy. *Skin Pharmacol Appl Skin Physiol* 2003; 16: 46-9.
7. Chroni E, Monastirli A, Pasmatzis E, Sakkis T, Georgiou S, Paschalis C, Tsambaos D. Sensorimotor polyneuropathy after a three-month oral acitretin therapy. *Clin Neuropharmacol* 2002; 25: 310-2.



---

## อาการสูญเสียการได้ยินในผู้ป่วยหลังได้รับการรักษา psoriasis ด้วยยา acitretin

วิศาล มหาสิทธิวัฒน์

รายงานผู้ป่วย 1 ราย ที่เป็นโรคเรื้อนกวาง หลังการรักษาด้วย acitretin ผู้ป่วย มีอาการหูตึง การได้ยินลดลง ในหูทั้ง 2 ข้าง ตรวจการได้ยินพบเป็นแบบระบบประสาทเสียงบกพร่อง หลังการรักษาและลดปริมาณยา acitretin ผู้ป่วยมีอาการดีขึ้น จึงตั้งข้อสมมติฐานการวินิจฉัยโรคว่าอาจเกิดจากยาชนิดนี้

---