

Anatomy of Lamina of Subaxial Spine Based on Computerized Tomographic Measurement

Jittipong Sanpote MD*, Thanwa Sudsang MD**, Kriangsak Saetia MD*

* Division of Neurosurgery, Department of Surgery, Faculty of Medicine, Ramathibodi Hospital, Mahidol University, Bangkok, Thailand

** Department of Diagnostic and Therapeutic Radiology, Faculty of Medicine, Ramathibodi Hospital, Mahidol University, Bangkok, Thailand

Background: Translaminar screw fixation of C2 has been widely used because of the safety and the ease of surgical technique. However, there were only few reports regarding anatomy of subaxial cervical spine for translaminar screw fixation.

Objective: To collect the database of morphometric parameters of lamina of subaxial cervical spines and determine the feasibility of translaminar screw fixation at subaxial cervical spines.

Material and Method: The authors analyzed CT scans of cervical spines of 100 patients at Ramathibodi Hospital between June and December 2016. Morphometric study of each lamina from C3 to C7 was done. The feasibility of translaminar screw placement was determined and analyzed.

Results: There were 61 male and 39 female patients. The largest laminar thickness was at C7 while the smallest was at C5. C7 translaminar screw placement provided a high success rate of 97% and 89% by unilateral and bilateral screw placement, respectively. C3 and C6 had a moderate chance of success but relatively poor chance of success at C4 and C5. There were no statistical differences between genders, left and right side in terms of morphometric parameters, and feasibility of screw placement.

Conclusion: C7 translaminar screw placement offers an alternative method of posterior fixation in subaxial cervical spine. There are variations in thickness of lamina of C3 and lamina of C6, therefore, a CT scan of cervical spine is recommended before the attempt of screw placement. C4 and C5 translaminar screw should be avoided due to the small diameter of lamina.

Keywords: Translaminar screw, Cervical spine, Cervical fixation, Anatomy

J Med Assoc Thai 2017; 100 (Suppl. 9): S8-S13

Full text. e-Journal: <http://www.jmatonline.com>

Posterior fixation of subaxial cervical spine has been used for a long time for many spinal pathologies. The common approaches are lateral mass screw fixation and pedicular screw fixation. Although pedicular screw fixation offers a strong biomechanical stability⁽¹⁾, technically it is more challenging, and could lead to a disastrous neurovascular complications⁽²⁻⁴⁾. Lateral mass screw fixation is an easier technique with less complications but provides less biomechanical stability⁽¹⁾.

In some situation, either method might not be applicable due to abnormal vertebral arteries, lateral mass breakage, and incompatible pedicle size, therefore, the translaminar screw insertion was introduced as a

salvage technique. The translaminar screw placement is commonly used at C2 vertebra due to the safety and the ease of surgical technique^(5,6). However, the suitability of this technique for subaxial cervical spines is still inconclusive. There are some studies regarding the feasibility of this technique with a 3.5 mm diameter screw. Alvin et al⁽⁷⁾ and Shin et al⁽⁸⁾ used a computer simulation to place the 3.5 mm-diameter translaminar screw. They proposed that a 4 mm-diameter of lamina is required to achieve the successful 3.5 mm-diameter screw placement.

The present study aimed to collect the database of morphometric parameters of lamina of subaxial cervical spines and determine the feasibility of translaminar screw fixation at subaxial cervical spines.

Material and Method

CT scans of cervical spines of 100 patients at Ramathibodi hospital between June 2016 and December 2016 were included for measurement. All imaging was performed with a 128-MDCT scanner (Aquilion CX,

Correspondence to:

Saetia K, Division of Neurosurgery, Department of Surgery, Faculty of Medicine Ramathibodi Hospital, Mahidol University 270 Rama 6 Road, Phyathai, Ratchathewi, Bangkok 10400, Thailand.

Phone: +66-2-2011315, Fax: +66-2-2011316

E-mail: kriangsak.saetia@windowslive.com

Toshiba medical systems). Three-dimensional software (Vitre2, Vital images) was used to reconstruct the acquired image into 1-mm-thick CT images in three orthogonal planes. Standard protocol for bone window with window level of 650 and window width of 3,500 was used for measurement. The exclusion criteria were age, younger than 18 years old, pathology of the posterior column (fractures, tumors, and infection), previous surgery at posterior column, and poor image quality. The study has been reviewed and approved by the local research ethics committee at Ramathibodi Hospital, Mahidol University on human rights related to research involving human subjects, based on the declaration of Helsinki.

Each lamina from C3 to C7 was measured bilaterally. On the axial plane, the authors measured the thickness and length. The thickness of inner and outer diameters were measured at the narrowest portion of lamina. The length of laminae was measured from the outer cortex of the contralateral spinous process (entry point) to the junction of lamina and lateral mass. On sagittal plane, the height of laminae were measured (Fig. 1).

The feasibility of 3.5 mm diameter translaminar screw placement was determined success if the outer diameter of laminar thickness and laminar height is at least 4mm. in both parameters.

The statistical analysis was performed with STATA software version 12.2. The results were expressed in mean \pm standard deviation. Student's t-test was used to assess the difference of parameters. Statistical significance was determined as *p*-value smaller than 0.05.

Results

CT scans of cervical spine of 100 patients were studied. Bilateral laminae at each level from C3 to C7 were measured. Therefore, there were 1,000 laminar measurement. Sixty-one patients were male, and 39 patients were female. The mean age of the patients was 47 ± 18.9 years (range 18 to 86).

Table 1 summarizes the morphometric details of each laminar level. The mean thickness of inner diameter of laminae of C3, C4, C5, C6, and C7 were 1.7, 1.0, 0.9, 1.5, and 3.1 mm, respectively. The mean thickness of outer diameter of laminae of C3, C4, C5, C6, and C7 were 3.8, 2.9, 2.8, 3.6, and 5.4 mm, respectively. The largest diameter of lamina was at C7 while C5 lamina had the smallest diameter. The mean length of lamina was 21.1 mm. The longest lamina is at C7 while the shortest is at C3. The mean laminar height was 13.5 mm

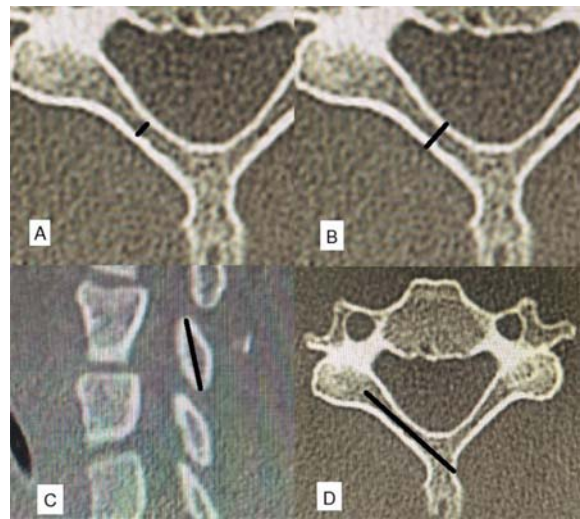


Fig. 1 Measurement of inner diameter of lamina (A), outer diameter of lamina (B), height of lamina (C) and length of lamina (D).

Table 1. Morphometric details of subaxial cervical spine

Level	Mean laminar thickness (mm)		Mean laminar length (mm)	Mean laminar height (mm)
	Inner	Outer		
C3	1.7 \pm 0.7	3.8 \pm 0.8	19.9 \pm 1.9	12.1 \pm 1.2
C4	1.0 \pm 0.6	2.9 \pm 0.8	20.1 \pm 2.2	12.2 \pm 1.3
C5	0.9 \pm 0.5	2.8 \pm 0.7	20.9 \pm 2.1	12.7 \pm 1.3
C6	1.5 \pm 0.8	3.6 \pm 0.7	21.2 \pm 2.4	13.9 \pm 1.5
C7	3.1 \pm 0.9	5.4 \pm 1.0	23.3 \pm 2.5	16.3 \pm 1.8

(range 4.2 to 21.6 mm). The highest lamina was at C7 and the lowest was at C3. There was no statistical difference in width, length, and height between left and right side (Table 2) and between men and women (Table 3).

The feasibility of unilateral translaminar screw fixation at C3, C4, C5, C6, and C7 was 50, 16, 10, 40, and 97%, respectively. While, the feasibility of bilateral translaminar screws fixation at C3, C4, C5, C6, and C7 was 31, 4, 2, 19, and 89%, respectively. As a result, the chance of successful fixation is highest at C7 and lowest at C5. There was no statistical difference between men and women in success rate of translaminar screw fixation in all levels as described in Table 4 and 5.

Discussion

Posterior fixation of subaxial cervical spine

Table 2. Comparison of laminar morphometric parameters between left and right side

Level	Mean inner laminar thickness		Mean outer laminar thickness		Mean laminar length		Mean laminar height	
	Right	Left	Right	Left	Right	Left	Right	Left
C3	1.7±0.8	1.7±0.8	3.8±0.8	3.8±0.8	19.9±2.2	20.0±1.9	12.0±1.4	12.1±1.3
C4	1.0±0.6	0.9±0.6	2.9±0.8	2.9±0.8	19.9±2.6	20.2±2.6	12.3±1.4	12.2±1.4
C5	0.9±0.6	0.9±0.6	2.8±0.8	2.8±0.8	20.9±1.9	21.0±2.7	12.7±1.4	12.7±1.5
C6	1.6±1.3	1.4±0.7	3.5±0.8	3.6±0.7	21.0±3.4	21.4±2.1	13.9±1.5	14.0±1.6
C7	3.1±0.9	3.1±1.0	5.4±1.0	5.5±1.1	23.2±2.8	23.4±2.7	16.4±2.3	16.3±2.1

Table 3. Comparison of laminar morphometric parameters between men and women

Level	Mean inner laminar thickness		Mean outer laminar thickness		Mean laminar length		Mean laminar height	
	Men	Women	Men	Women	Men	Women	Men	Women
C3	1.8±0.7	1.7±0.8	3.8±0.7	3.7±0.8	20.5±1.9	19.1±1.5	12.6±1.1	11.4±1.0
C4	1.0±0.7	0.9±0.5	2.9±0.8	2.8±0.6	20.6±2.0	19.3±2.2	12.7±1.3	11.5±1.0
C5	0.9±0.6	0.8±0.5	2.8±0.8	2.7±0.6	21.4±2.1	20.1±1.8	13.0±1.3	12.1±1.1
C6	1.6±0.9	1.3±0.6	3.6±0.7	3.4±0.7	22.1±1.8	19.9±2.7	14.2±1.4	13.4±1.5
C7	3.3±0.9	2.7±0.9	5.7±0.9	5.0±4.0	24.3±2.2	21.8±2.0	16.8±2.0	15.7±1.1

Table 4. Feasibility of unilateral translaminar screw placement

Level	Unilateral fixation		p-value
	Men, n (%)	Women, n (%)	
C3	32 (52.46)	18 (46.15)	0.54
C4	12 (19.67)	4 (10.26)	0.27
C5	7 (11.48)	3 (7.69)	0.45
C6	25 (40.98)	15 (38.46)	0.61
C7	60 (98.36)	37 (94.87)	0.84

Table 5. Feasibility of bilateral translaminar screw placement screw

Level	Bilateral fixation		p-value
	Men, n (%)	Women, n (%)	
C3	19 (31.15)	12 (30.76)	0.97
C4	4 (6.56)	0 (0)	0.10
C5	2 (3.28)	0 (0)	0.75
C6	10 (16.39)	9 (23.08)	0.76
C7	56 (91.8)	33 (84.6)	0.40

could be done in various techniques. The well-known techniques are pedicular screw and lateral mass screw fixation. The former provides high pullout strength but carries a risk of serious neurovascular injury, while the latter provides lower biomechanical strength but offers a lower rate of neurovascular injury⁽¹⁾. In some situation, either technique may not be applicable such as lateral mass breakage or abnormal vertebral arteries⁽²⁻⁴⁾. Translaminar screw placement of subaxial cervical spine is considered to be an alternative method of fixation⁽⁹⁻¹²⁾.

In 1999, Xu et al⁽¹³⁾ studied the anatomy of lamina of C2 to L5 from 37 cadaveric specimens. They found that the overall parameters of subaxial cervical spine were greater in men than in women and C4 demonstrated the smallest thickness of all subaxial cervical spine while the largest thickness was at C2. The mean thickness of C3 to C7 did not seem to be suitable for translaminar screw fixation.

In 2004, Wright⁽⁵⁾ had described a novel technique of bilateral C2 translaminar screw fixation. This technique has been widely accepted not only in literatures, but also in real practice afterwards. The practice of this technique also extended into C7 and upper thoracic spines of both pediatric and adult

population^(9,10,12,14). However, the usefulness of this approach for remaining subaxial spines remains controversial. There were some studies of subaxial laminar morphology and feasibility of translaminar screw placement in subaxial cervical spines, but the results varied among ethnic groups⁽¹⁵⁾.

The present study aimed to collect database of morphometric of subaxial cervical spines and to determine the feasibility of translaminar screw placement. The authors found that mean laminar thickness decreased from C3 to C5 and then increased from C5 to C7. Although Yusof et al⁽¹⁶⁾ described the smallest thickness at C4, the present study showed that the smallest thickness was at C5. The difference between these results could be from the difference in population groups. The authors found that laminar thickness did not significantly differ between men and women. This finding was described by other studies^(7,8,15).

Mean thickness of outer diameter of subaxial spine in present study ranged from 2.8 to 5.4 mm, whereas mean laminar height ranged from 12.1 to 16.3 mm. These findings showed that feasibility of translaminar screw placement depends mainly on laminar thickness rather than laminar height. Yusof et al⁽¹⁶⁾ proposed that the determination of successful translaminar screw placement rely on the thickness of lamina because the thickness is consistently smaller than height⁽¹⁶⁾.

The feasibility of unilateral translaminar screw placement was impressively high at C7 (97%) then decreased to 50%, 40%, 16% and 10% at C3, C6, C4 and C5, respectively. There was no statistically significant difference between men and women, which is similar to the studies of Alvin et al⁽⁷⁾ and Yusof et al⁽¹⁶⁾. Shin et al⁽⁸⁾ described that the success rates of unilateral screw placement were significantly higher in male than in female at C7 (96.5% vs. 85.5%, $p < 0.001$) and at C6 (41.7% vs. 20.5%). However, the success rate at C7 was still high in both sexes. Nakanishi et al⁽¹¹⁾ demonstrated low success rate of translaminar screw placement for subaxial spine from 0 to 39%. The marked drop in success rate was due to different criterion of screw failure. They used inner diameter of laminar thickness as a criterion for feasibility of screw placement rather than outer diameter of laminar thickness as in other studies.

At C7, bilateral translaminar screw fixation still offers a high success rate of 89% while at C3 and C6 the success rate decreased to 31% and 19%, respectively. The similar findings were demonstrated

in previous studies^(7,8). The present study showed no significant difference in success rate between men and women. In contrast, Shin et al⁽⁸⁾ founded that men had significantly higher success rate for bilateral screw fixation than women (68.8% vs. 52%, $p < 0.001$).

There are some limitations of the present study. First, the present study based on CT scan of cervical spine to study the anatomy and feasibility of translaminar screw placement at subaxial cervical spine instead of real cadavers, which is more realistic than CT scan. However, in this way we could recruit more patients into the study. Second, the feasibility of the screw placement relies on the thickness of lamina without actual screw placement or computer simulation, so the accuracy of the result might be less reliable. However, we counter this problem by following the previous study of Alvin et al⁽⁷⁾ and Shin et al⁽⁸⁾, which determine that success screw placement required at least 4 mm of lamina thickness. Size of screw is another limitation. If the surgeons use screw larger than 3.5 mm, the success rate might not be as high as demonstrated in the present study.

Conclusion

C7 translaminar screw placement could be used as an alternative fixation method because of a high success rate. However, translaminar screw fixation at C3 and C6 without CT scan to determine the thickness of lamina is not recommended and should not be used as a routine method. As the translaminar screw placement at C4 and C5 provides a very low success rate, the authors suggest avoiding the procedure at these levels. Gender did not seem to play a significant role in success rate of screw placement.

What is already known on this topic?

There were some studies of subaxial laminar morphology and feasibility of translaminar screw placement of subaxial cervical spines. However, the results varied. Most studies reported highest success rate of subaxial translaminar screw placement at C7.

What this study adds?

The present study showed additional data of subaxial laminar morphology and the feasibility of translaminar screw placement. The highest success rate was at C7 while C3 and C6 showed moderate success rate, and C4 and C5 had very poor chance of success.

Acknowledgements

The authors thank Mrs. Sukanya Siriyotha

for the statistical analysis.

Potential conflicts of interest

None.

References

1. Jones EL, Heller JG, Silcox DH, Hutton WC. Cervical pedicle screws versus lateral mass screws. Anatomic feasibility and biomechanical comparison. *Spine (Phila Pa 1976)* 1997; 22: 977-82.
2. Mueller CA, Roessler L, Podlogar M, Kovacs A, Kristof RA. Accuracy and complications of transpedicular C2 screw placement without the use of spinal navigation. *Eur Spine J* 2010; 19: 809-14.
3. Yoshida M, Neo M, Fujibayashi S, Nakamura T. Comparison of the anatomical risk for vertebral artery injury associated with the C2-pedicle screw and atlantoaxial transarticular screw. *Spine (Phila Pa 1976)* 2006; 31: E513-7.
4. Neo M, Sakamoto T, Fujibayashi S, Nakamura T. The clinical risk of vertebral artery injury from cervical pedicle screws inserted in degenerative vertebrae. *Spine (Phila Pa 1976)* 2005; 30: 2800-5.
5. Wright NM. Posterior C2 fixation using bilateral, crossing C2 laminar screws: case series and technical note. *J Spinal Disord Tech* 2004; 17: 158-62.
6. Cassinelli EH, Lee M, Skalak A, Ahn NU, Wright NM. Anatomic considerations for the placement of C2 laminar screws. *Spine (Phila Pa 1976)* 2006; 31: 2767-71.
7. Alvin MD, Abdullah KG, Steinmetz MP, Lubelski D, Nowacki AS, Benzel EC, et al. Translaminar screw fixation in the subaxial cervical spine: quantitative laminar analysis and feasibility of unilateral and bilateral translaminar virtual screw placement. *Spine (Phila Pa 1976)* 2012; 37: E745-51.
8. Shin SI, Yeom JS, Kim HJ, Chang BS, Lee CK, Riew KD. The feasibility of laminar screw placement in the subaxial spine: analysis using 215 three-dimensional computed tomography scans and simulation software. *Spine J* 2012; 12: 577-84.
9. Hong JT, Sung JH, Son BC, Lee SW, Park CK. Significance of laminar screw fixation in the subaxial cervical spine. *Spine (Phila Pa 1976)* 2008; 33: 1739-43.
10. Jea A, Johnson KK, Whitehead WE, Luerssen TG. Translaminar screw fixation in the subaxial pediatric cervical spine. *J Neurosurg Pediatr* 2008; 2: 386-90.
11. Nakanishi K, Tanaka M, Sugimoto Y, Misawa H, Takigawa T, Fujiwara K, et al. Application of laminar

- screws to posterior fusion of cervical spine: measurement of the cervical vertebral arch diameter with a navigation system. Spine (Phila Pa 1976) 2008; 33: 620-3.
12. Chamoun RB, Relyea KM, Johnson KK, Whitehead WE, Curry DJ, Luerssen TG, et al. Use of axial and subaxial translaminar screw fixation in the management of upper cervical spinal instability in a series of 7 children. Neurosurgery 2009; 64: 734-9.
 13. Xu R, Burgar A, Ebraheim NA, Yeasting RA. The quantitative anatomy of the laminae of the spine. Spine (Phila Pa 1976) 1999; 24: 107-13.
 14. Wang MY. Cervical crossing laminar screws: early clinical results and complications. Neurosurgery 2007; 61: 311-5.
 15. Ji GY, Oh CH, Park SH, Kurniawan F, Lee J, Jeon JK, et al. Feasibility of translaminar screw placement in Korean population: morphometric analysis of cervical spine. Yonsei Med J 2015; 56: 159-66.
 16. Yusof MI, Shamsi SS. Translaminar screw fixation of the cervical spine in Asian population: feasibility and safety consideration based on computerized tomographic measurements. Surg Radiol Anat 2012; 34: 203-7.

กายวิภาคของ lamina ของกระดูกสันหลังส่วนคอข้อที่ 3 ถึง 7 โดยเอกซเรย์คอมพิวเตอร์

จิตติพงษ์ แสงโกชน, ธันวาท สุคนธ์, เกรียงศักดิ์ แซ่เตีย

ภูมิหลัง: การใส่สกรูผ่าน lamina ที่กระดูกสันหลังส่วนคอข้อที่ 2 ได้มีการใช้อย่างแพร่หลายเนื่องจากความปลอดภัยและความง่ายในการใส่ อย่างไรก็ตาม มีรายงานเพียงไม่กี่รายงานที่กล่าวถึงกายวิภาคของกระดูกสันหลังส่วนคอข้อที่ 3 ถึง 7 สำหรับการใส่สกรูผ่าน lamina

วัตถุประสงค์: เพื่อรวบรวมข้อมูลพื้นฐานด้านกายวิภาคของ lamina ของกระดูกสันหลังส่วนคอข้อที่ 3 ถึง 7 และประเมินความเป็นไปได้ในการใส่สกรูผ่าน lamina เพื่อยึดกระดูกสันหลังส่วนคอข้อที่ 3 ถึง 7

วัสดุและวิธีการ: ผู้เขียนได้วิเคราะห์ภาพเอกซเรย์คอมพิวเตอร์บริเวณกระดูกสันหลังส่วนคอของผู้ป่วยที่โรงพยาบาลรามธิบดีจำนวน 100 ราย ตั้งแต่เดือนมิถุนายนถึงเดือนธันวาคม พ.ศ. 2559 ข้อมูลพื้นฐานด้านกายวิภาคของ lamina ของกระดูกสันหลังส่วนคอข้อที่ 3 ถึง 7 จะถูกวัดเก็บข้อมูล และประเมินความเป็นไปได้ในการใส่สกรูผ่าน lamina

ผลการศึกษา: ผู้ป่วยทั้งหมดประกอบด้วยผู้ชาย 61 รายและผู้หญิง 39 ราย ขนาด lamina ที่หนาที่สุดอยู่ที่กระดูกสันหลังส่วนคอข้อที่ 7 ในขณะที่ lamina ที่บางที่สุดอยู่ที่กระดูกสันหลังส่วนคอข้อที่ 5 การใส่สกรูผ่าน lamina ที่กระดูกสันหลังส่วนคอข้อที่ 7 มีโอกาสสำเร็จสูงถึงร้อยละ 97 และร้อยละ 89 สำหรับการใส่สกรูข้างเดียวและการใส่สกรูทั้งสองข้างตามลำดับ ที่กระดูกสันหลังส่วนคอข้อที่ 3 และข้อที่ 6 โอกาสใส่สกรูสำเร็จอยู่ในระดับปานกลาง แต่ที่ระดับข้อที่ 4 และ 5 โอกาสใส่สกรูสำเร็จต่ำมาก ไม่มีความแตกต่างอย่างมีนัยสำคัญทางสถิติของข้อมูลด้านกายวิภาคและความเป็นไปได้ในการใส่สกรูผ่าน lamina ระหว่างเพศชายกับหญิงและระหว่างด้านซ้ายกับขวา

สรุป: ที่กระดูกสันหลังส่วนคอข้อที่ 7 การใส่สกรูผ่าน lamina สามารถใช้เป็นทางเลือกหนึ่งสำหรับการผ่าตัดยึดกระดูกสันหลังส่วนคอ สำหรับกระดูกสันหลังส่วนคอข้อที่ 3 และ 6 ขนาดของ lamina มีความแตกต่างกันในผู้ป่วยแต่ละราย ดังนั้นจึงควรทำเอกซเรย์คอมพิวเตอร์เพื่อประเมินขนาดของ lamina ก่อนการใส่สกรู ส่วนกระดูกสันหลังส่วนคอข้อที่ 4 และ 5 ควรหลีกเลี่ยงการใส่สกรูผ่าน lamina เนื่องจาก lamina มีขนาดเล็กมาก
