

# Adipose-Derived Stromal Cells in Lipofilling Injected Fat and Factors Associated with Outcomes: A Preliminary Report

Prakasit Chirappapha MD\*, Paweena Luadthai MD\*,  
Paisarn Boonsakan MD\*\*, Katesaree Suriyachand PhD\*\*, Panuwat Lertsithichai MD, MSc\*,  
Youwanush Kongdan MD\*, Thongchai Sukarayothin MD\*, Monchai Leesombatpaiboon MD\*

\* Development of Surgery, Faculty of Medicine Ramathibodi Hospital, Mahidol University, Bangkok, Thailand

\*\* Development of Pathology, Faculty of Medicine Ramathibodi Hospital, Mahidol University, Bangkok, Thailand

**Background:** Lipofilling has been developed to correct the problem after breast conserving surgery and breast reconstruction in the patient with breast cancer. The aim of this study is to evaluate amount and proportion of adipose-derived stromal cells (ADSCs) in harvested fat and other factors affecting outcome of the lipofilling.

**Objective:** The aims of this study are to evaluate the amount and proportion of ADSCs in harvested fat and factors associated with the lipofilling outcomes.

**Material and Method:** A prospective cohort study was performed between 2014 and 2016 in the breast cancer and phyllodes tumor patients who underwent breast conservative surgery and total mastectomy with reconstruction, or have a deformity, or asymmetry. The data of cluster of differentiation (CD) markers, cell viability, and outcome of the lipofilling were collected.

**Results:** Thirteen patients had undergone lipofilling and were included in the present study. Donor site complications were not found. One patient developed breast abscess after the operation, five patients had fat necrosis from mammography and ultrasonography, and two of these patients received intervention to prove fat necrosis. Three fat samples were analyzed for CD markers. The initial finding demonstrated CD45<sup>+</sup>, CD34<sup>+</sup> in all samples and one sample demonstrated CD45<sup>+</sup>, CD34<sup>+</sup>, CD105<sup>+</sup>, and CD90<sup>+</sup> to confirm the presence of ADSCs. No factors were found to affect the fat necrosis.

**Conclusion:** The present study used the CD surface markers to confirm that the fat graft has ADSCs. We could not find factors associated with fat necrosis. In further study, we will include more patients to demonstrate the outcome of lipofilling from amount and proportion of ADSCs and other factors.

**Keywords:** Lipofilling, Autologous fat grafting, Adipocyte-derived stromal cells, Breast reconstruction, Breast cancer

**J Med Assoc Thai 2017; 100 (Suppl. 9): S94-S102**

**Full text. e-Journal:** <http://www.jmatonline.com>

Lipofilling (also called autologous fat transfer or autologous fat grafting) have been developed to correct the problems after breast conserving surgery and breast reconstruction such as breast deformity, deflection, asymmetry, and tissue damage after radiotherapy. The lipofilling procedure consists of three steps, namely fat harvesting, fat preparation, and fat injection. Coleman describes his technique of lipofilling by injecting the processed fat in small amounts using multiple tunnels, in many layers and directions. This technique helps the adipocytes to contact with host tissue and receive the nutrition for survival<sup>(3-6)</sup>. The

injected fat consists of adipocytes, adipose-derived stromal cells (ADSCs), vascular endothelial cells, fibroblasts, and blood cells<sup>(1,21)</sup>. The ADSCs are the factor that improves the survival of injected fat, leading to lower incidence of fat necrosis and improve the aesthetic result.

The concerns about effect of ADSCs in the injected fat on the microenvironment of the breast that were raised, especially the oncological safety. There is no evidence to support these concerns. A number of studies for the oncologic safety after lipofilling in the breast cancer patients have been published with good results and do not interfere the long-term follow-up of the breast cancer surveillance<sup>(2,8-12,15-17,18-20)</sup>.

The method used to prove that there are ADSCs in the injected fat is to perform cell culture, surface marker, and flow cytometry analysis of cluster of differentiation (CD) 45<sup>+</sup>, CD31<sup>+</sup>, CD34<sup>+</sup>, CD90<sup>+</sup>,

## Correspondence to:

Boonsakan P, Development of Pathology, Faculty of Medicine Ramathibodi Hospital, Mahidol University Bangkok 10400, Thailand.

Phone: +66-2-2011432, Mobile: +66-83-2979696

E-mail: [pboonsakan@gmail.com](mailto:pboonsakan@gmail.com)

CD105-, CD146-(21). Few studies accounted for the ACSCs in the injected fat. Most of them focused on the oncologic safety and the efficacy of lipofilling.

The aims of this study are to evaluate the amount and proportion of ADSCs in harvested fat and factors associate with the lipofilling outcomes.

## Material and Method

A prospective cohort study was performed between 2014 and 2016 in the breast cancer and phyllodes tumor patients who underwent breast conservative surgery and total mastectomy with immediate or delay reconstruction and have deformity or asymmetry after surgery. The patients decided to take the lipofilling procedure. Informed consent was signed by all participants. The patients' age, weight, height, body mass index (BMI), breast cancer diagnosis, date of the first oncologic operation, pathologic report, and adjuvant treatment (chemotherapy, radiotherapy, hormonal, and targeted therapy) were recorded. All patients were evaluated preoperatively with clinical breast examination. The fat deficit volume was estimated by preoperative photographic assessment

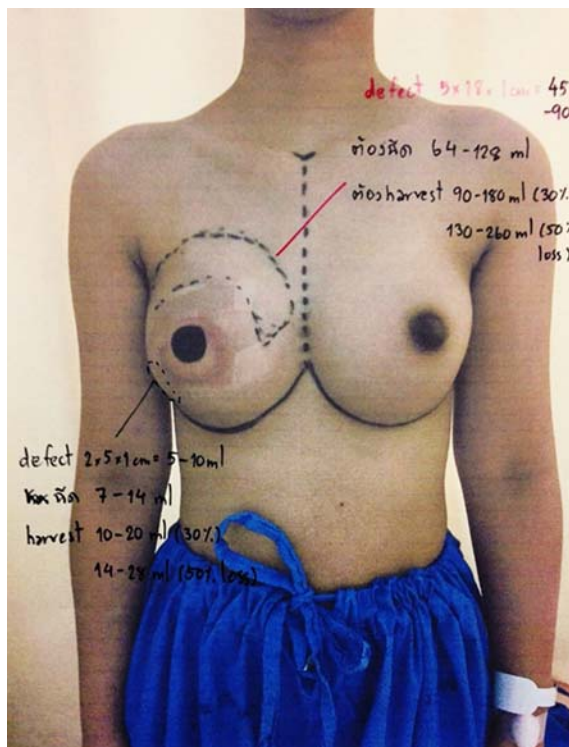
and 2-dimensional quantitative measurement using a caliper on its two major axis and depth by estimation as shown in Fig. 1. At the operation time, the patient was given lipofilling procedure using Coleman technique as follows. We infiltrated the donor site with Klein's solution. The composition was 500 mL Lactate Ringer's solution, 1ml of 1:200,000 epinephrine and 50 mL of 1% xylocaine. The fat was harvested with negative pressure applied to a blunt tipped cannula. The fat-aspirate fluid obtained was centrifuged at 3,000 revolutions per minute (rpm) for three minutes. The fat was separated in three layers namely the oily component, the purified adipocytes, and the lysed cells with blood residuals. We injected the purified fat into the recipient area, through a 17 G blunt Coleman's cannula. Multidirectional injections were performed with thin layer and multiple tunnel technique. Patients were given prophylaxis antibiotics prior to surgery and they wore elastic banding on the liposuctioned area. The fat samples were sent to the pathologist and clinician to evaluate about cell surface marker (CD 34, CD 45, CD 31, CD 146) flow cytometry analysis and cell viability. We evaluated early postoperative complications at the recipient site such as cellulitis, hematoma, or abscess, and at the donor site such as seroma and cellulitis. At the follow-up time, we collected the data on the donor site complications and recipient site complications such as fat necrosis, abscess, and hematoma and the result of mammographic finding at three to six months after the lipofilling procedure.

## Statistical analysis

The statistical analysis was performed using STATA version 14. Quantitative variables were summarized as mean and standard deviation or median and range. Categorical variables were summarized as counts and percentage. Difference in quantitative variables between groups was test using unpaired t-test and Fisher's exact test was used for categorical variables. Statistical significant was defined as a two-side *p*-value of less than 0.05.

## Results

Thirteen patients underwent the lipofilling procedure. The fat specimens from three of these 13 patients were sent to be evaluated about cell surface markers. The mean age of patients was 44.78 years (SD = 10.25, range 28 to 57 years). Patients had history of invasive breast cancer, carcinoma in situ, and phyllodes tumor. One patient had invasive breast cancer in the right breast and we performed the lipofilling in left



**Fig. 1** Preoperative planning photograph showing the area of defect and estimated the defect volume.

breast to correct the defect in the upper inner quadrant at the same operation. The patients' characteristics are shown in Table 1. Type of oncologic surgery and breast reconstruction prior to the lipofilling procedure are shown in Table 2. The mean total harvested fat volume was 314.11 mL with a range from 208 to 408 mL. The mean volume of total fat after centrifugation was 131.11 mL or 42.07% of the harvested fat from the patients. The mean volume of the fat graft that was injected to the patient was 118 mL (range 62 to 232 mL). The mean interval time after oncologic surgery to lipofilling procedure was 39.5 month (range 7.5 to 171 month) and the mean follow-up time was nine months. All patients underwent one lipofilling procedure. There was no complication of the donor site after

**Table 1.** Summary of patients' characteristic

Patient characteristics	Summary n = 13
Age (year), mead (SD)	44.78 (10.25)
Weight (Kg), mean (SD)	57.98 (6.06)
Height (m), mean (SD)	1.57 (0.06)
BMI, mean (SD)	23.46 (2.22)
Diagnosis	
Invasive cancer	53.8%
Carcinoma in situ	23.1%
Phyllodes tumor	23.1%
Normal breast	7.7%
Stage	
0	30% (3)
1A	20% (2)
2A	30% (3)
3A	10% (1)
3C	10% (1)
Chemotherapy	46.2% (6)
Radiotherapy	30.8% (4)
Hormonal therapy	76.9% (10)

**Table 3.** Summary of lipofilling procedure

Parameter	Mean (n = 9)	Median (range)
Total harvested fat volume (mL)	314.11	308 (208 to 408)
Harvest from thigh (mL)	93.67	93.67 (0 to 230)
Harvest from abdomen (mL)	203.78	160 (96 to 420)
Total fat graft after centrifugation (mL)	131.11	123 (72 to 232)
Fat after centrifugation (%)	42.07	39 (23 to 57)
Total fat graft (mL) (injected to the recipient)	118	120 (62 to 132)
Time after oncologic surgery (month)	39.5	14.46 (7.5 to 171)
Follow-up time (month)	9.0	7.3 (0.5 to 20.5)

liposuction and one patient had abscess in the recipient site, which needed surgical intervention (Table 4). A Mammography and ultrasound were performed in eight patients. The result of the mammography showed BIRADS2 (Breast Imaging Recording And Data System) and BIRADS3. Two patients developed BIRADS4A in mammography and needed tissue diagnosis, one patient had fat necrosis proven from fine needle aspiration (FNA) and another had fat necrosis proven from core needle biopsy. No local recurrent and

**Table 2.** The surgical characteristic

Parameters	Number (%)
Site	
Right	6 (46.2)
Left	7 (53.8)
Oncologic surgery	
BCT	2 (15.4)
Total mastectomy	6 (46.2)
Nipple sparing mastectomy	2 (15.4)
Skin sparing mastectomy	2 (15.4)
Normal breast	1 (7.7)
Axillary lymph node management	
No	2 (16.7)
SLNB	8 (66.7)
ALND	2 (16.7)
Reconstruction	
No	2 (16.7)
Yes	10 (83.7)
Type of reconstruction	
TRAM	6 (50)
Delayed TRAM	2 (16.7)
LD with prosthesis	1 (8.3)
Prosthesis alone	1 (8.3)

BCT = Breast conserving therapy, SLNB = Sentinel lymph node biopsy, ALND = Axillary lymph node dissection TRAM = Transeverse rectus abdominis musculocutaneous, LD = Latissimus dorsi

metastasis was found in the period of follow-up time. The correlation between possible factors and fat necrosis are shown in Table 5. No factors were found to be affecting the fat necrosis. Three fat samples were sent to evaluate the CD marker; the results of which are shown in Fig. 2. The clinical outcome is shown in Fig. 3 to 6.

## Discussion

This study had many limitations because of small sample size. We studied only 25 patients. However, this preliminary study confirm that the fat graft demonstrated CD45- and CD34+ in all samples, thus, it confirmed that there are adipose-derived cell populations. One sample demonstrated CD45-, CD34+, CD90+, and CD105-, thus, confirmed that there are ADSCs<sup>(21)</sup>. The cell viability in all three specimens is high. In the future, we will include more patients and will evaluate the amount and proportion of ADSCs on the lipofilling outcome in a better way than this study. In the previous studies, the patients underwent more than one lipofilling procedure to correct the defect<sup>(3)</sup>. In our study, all the patients received only one lipofilling

procedure. We cannot conclude that the patients have a good cosmetic result. We need long-term follow-up and re-evaluation of the cosmetic result again. In our series, one patient who had the lipofilling procedure, returned for mammoplasty because she still had a large deformity, but she refused a second lipofilling procedure.

The lipofilling procedure was safe, with low complication rate and improved cosmetic result in patients that received oncoplastic surgery. One patient had breast abscess a week after the operation. The patient had underlying diabetes mellitus. Therefore, we should be more concerned in the patients who have underlying disease<sup>(3)</sup>.

The fat necrosis seen in five patients, were not correlated with other factors. We cannot conclude this result because of the few patients in this study. In the literature reviews, we found that 7 to 10% of the lipofilling patients have fat necrosis but there is no clinical, pathological, or clinical variable to predict the development of fat necrosis<sup>(8,9)</sup>.

Previous studies suggest how to reduce the occurrence of the liponecrosis or fat necrosis by using Coleman's technique. It is to inject the fat graft from a separate column of fat to maximize the surface contact between the grafted fat and the healthy tissue. However, it does not perform overcorrection of the breast defect that might impair the viability of adipose tissue leading to liponecrosis<sup>(3)</sup>.

Delay et al reported that approximately 30% of the harvested material is lost after centrifugation

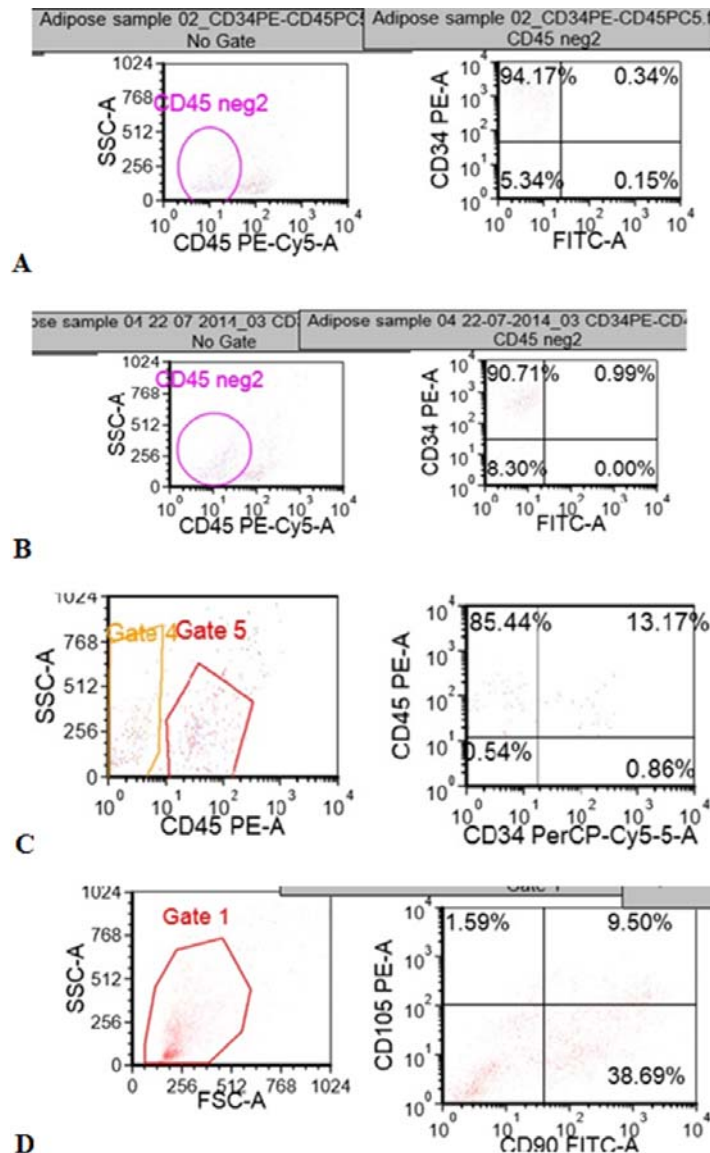
**Table 4.** Complication of lipofilling

Complications	Number (%)
Abscess	1 (7.7)
Fat necrosis	5 (62.5)

**Table 5.** The correlation between the patient's factors and fat necrosis

Factors	No. fat necrosis (%) n = 3	Fat necrosis (%) n = 5	p-value
Diagnosis			
IDC	0	3 (100%)	0.076
DCIS	1 (33.3%)	2 (66.7%)	
phyllodes	2 (100%)	0	
Chemotherapy			
No	3 (50%)	3 (50%)	0.357
Yes	0	2 (100%)	
Radiotherapy			
No	3 (42.9%)	4 (57.1%)	0.625
Yes	0	1 (100%)	
Hormone therapy			
No	2 (100%)	0	0.107
Yes	1 (16.7%)	5 (83.3%)	

IDC = Invasive ductal carcinoma, DCIS = Ductal carcinoma in situ



**Fig. 2** Cell viability and CD marker. A) Female patient with Ductal carcinoma in situ, Left breast. Cell viability 97.77%, population of CD45<sup>-</sup> CD34<sup>+</sup> 94.17%. B) Female patient with Ductal carcinoma in situ, Left breast. Cell viability 56.36%, population of CD45<sup>-</sup> CD34<sup>+</sup> 90.17%. C) Female patient with Invasive ductal carcinoma, Left breast. Cell viability 87.51%, population of CD45<sup>-</sup> CD34<sup>+</sup> 85.44%. D) CD90<sup>+</sup> CD105<sup>-</sup> 38.69%.

and 30% of volume transferred is reabsorb after grafting<sup>(7)</sup>. In this study, approximately 52% of the harvested materials was loss after centrifugation. This problem probably arises from technical issues. The results from the present study may help improve fat harvesting technique in the future.

## Conclusion

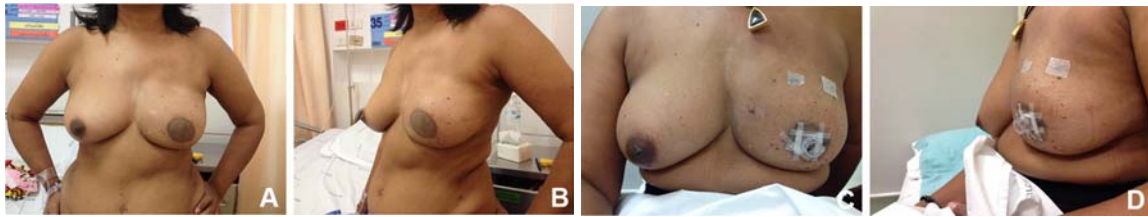
The preliminary report confirms that we can

demonstrate CD45<sup>-</sup>, CD34<sup>+</sup>, CD90<sup>+</sup>, and CD105<sup>-</sup> in the harvested fat. Lipofilling procedure can be used safety in patients who have defect from oncologic breast surgery. In future studies, we will evaluate the long-term safety and factors effecting outcome of this procedure.

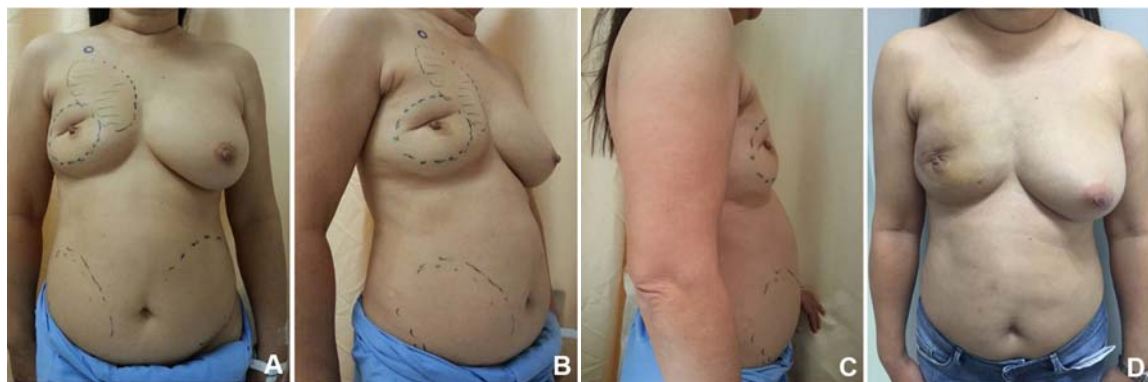## What is already known on the topic?

The injected fat for lipofilling consists of

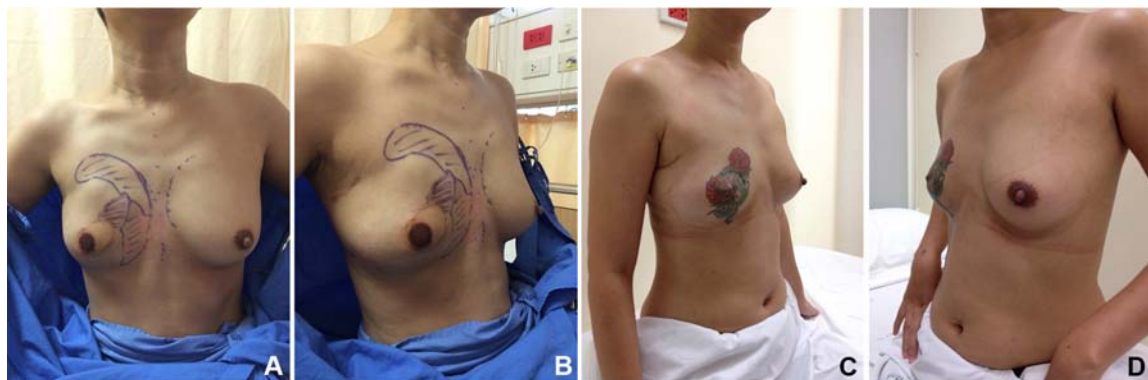




**Fig. 3** A 54 years old women present with ductal carcinoma in situ Lt. breast, she received left total mastectomy and SLNB with TRAM flap reconstruction. A) Anterior view of deformity at upper inner quadrant of the reconstructed breast. B) Lateral view of deformity at upper inner quadrant of the reconstructed breast. C) Anterior view of the results at 3 weeks after lipofilling procedure, the Left breast had fullness in the upper inner quadrant. D) Lateral view of the results at 3 weeks after lipofilling procedure.



**Fig. 4** A 56 years old woman with invasive ductal carcinoma in right breast, she received breast conserving operation and sentinel lymph node biopsy then radiation. A) Preoperative anterior view, she had breast defect and deformity. B) Preoperative oblique view. C) Preoperative lateral view. D) Anterior view, a week after lipofilling procedure, the breast had fullness and decreased deformity. E) Oblique view.

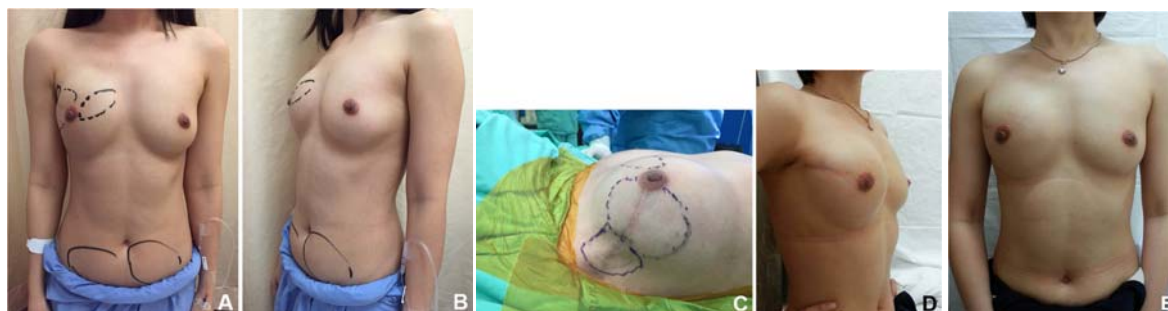

**Fig. 5** A 31 years old woman with invasive ductal carcinoma in right breast, she received total mastectomy with sentinel lymph node biopsy and LD flap reconstruction. A) Anterior view, show loss of fullness in upper inner quadrant. B) Lateral view of deformity at upper inner quadrant of the reconstructed breast. C) Oblique view, 11 months postoperatively, she underwent tattoo and upper inner quadrant had fullness. D) Oblique view.

adipocytes, adipose-derived stromal cells (ADSCs), vascular endothelial cells, fibroblasts, and blood cells. The ADSCs are the factor that improves the survival of

injected fat, leading to lower incidence of fat necrosis and improve the esthetic result.

Many studies about the oncologic safety of



**Fig. 6** A 36 years old woman with invasive ductal carcinoma in right breast, she received nipple sparing mastectomy with sentinel lymph node biopsy and LD flap reconstruction with prosthesis. A) Preoperative anterior view, She had the defect around surgical scar and the normal Left breast had loss of fullness in the upper outer quadrant. B) Preoperative oblique view. C) Preoperative lateral view. D) Oblique view, two months after lipofilling procedure, the right breast shows fullness. E) Anterior view.

lipofilling in the breast cancer patients have been published. They show good results and do not interfere with the long-term follow-up of the breast cancer surveillance.

Few previous studies accounts for the ACSCs in the injected fat. Most of them focus on the oncologic safety and the efficacy of lipofilling.

#### What this study adds?

This preliminary report confirms that we can demonstrate ACSCs in the harvested fat.

#### Acknowledgements

We wish to acknowledge my clinical fellows team as follows: Dr. Saowanee Kitudomrat, Dr. Suragit Pornchai, Dr. Watoo Vassanasiri, Dr. Noppadol Trikunagonvong, Dr. Chayanoot Rattadilok, Dr. Rupporn Sukpanich, Dr. Rujira Panawattanakul, Dr. Natthapong Saengow to encourage these operations and Miss Nichakarn Kuphirun for English revision of the text.

#### Potential conflicts of interest

None.

#### References

1. Rowan BG, Gimble JM, Sheng M, Anbalagan M, Jones RK, Frazier TP, et al. Human adipose tissue-derived stromal/stem cells promote migration and early metastasis of triple negative breast cancer xenografts. *PLoS One* 2014; 9: e89595.
2. Carvajal J, Patino JH. Mammographic findings after breast augmentation with autologous fat injection. *Aesthet Surg J* 2008; 28: 153-62.
3. Chirappapha P, Rietjens M, De Lorenzi F, Andrea M, Hamza A, Petit JY, et al. Evaluation of lipofilling safety in elderly patients with breast cancer. *Plast Reconstr Surg Glob Open* 2015; 3: e441.
4. Coleman SR, Saboeiro AP. Fat grafting to the breast revisited: safety and efficacy. *Plast Reconstr Surg* 2007; 119: 775-85.
5. Coleman SR. Hand rejuvenation with structural fat grafting. *Plast Reconstr Surg* 2002; 110: 1731-44.
6. Coleman SR. Structural fat grafting. In: Thorne C, Grabb WC, Smith JW, editors. *Grabb and Smith's plastic surgery*. 6th ed. Philadelphia, PA: Wolters Kluwer Health/Lippincott Williams & Wilkins; 2007: 480-6.
7. Delay E. Lipomodelling of the reconstructed breast. In: Spear SE, editor. *Surgery of the breast: principles and art*. 2nd ed. Philadelphia: Lippincott Williams & Wilkin; 2005: 930-46.
8. Doren EL, Parikh RP, Laronga C, Hiro ME, Sun W, Lee MC, et al. Sequelae of fat grafting postmastectomy: an algorithm for management of fat necrosis. *Eplasty* 2012; 12: e53.
9. Claro F Jr, Figueiredo JC, Zampar AG, Pinto-Neto AM. Applicability and safety of autologous fat for reconstruction of the breast. *Br J Surg* 2012; 99: 768-80.
10. Gutowski KA. Current applications and safety of autologous fat grafts: a report of the ASPS fat graft task force. *Plast Reconstr Surg* 2009; 124: 272-80.
11. Hamza A, Lohsiriwat V, Rietjens M. Lipofilling in breast cancer surgery. *Gland Surg* 2013; 2: 7-14.
12. Parikh RP, Doren EL, Mooney B, Sun WV, Laronga C, Smith PD. Differentiating fat necrosis from recurrent malignancy in fat-grafted breasts: an imaging classification system to guide

- management. *Plast Reconstr Surg* 2012; 130: 761-72.
13. Petit JY, Lohsiriwat V, Clough KB, Sarfati I, Ihrai T, Rietjens M, et al. The oncologic outcome and immediate surgical complications of lipofilling in breast cancer patients: a multicenter study-Milan-Paris-Lyon experience of 646 lipofilling procedures. *Plast Reconstr Surg* 2011; 128: 341-6.
  14. Petit JY, Botteri E, Lohsiriwat V, Rietjens M, De Lorenzi F, Garusi C, et al. Locoregional recurrence risk after lipofilling in breast cancer patients. *Ann Oncol* 2012; 23: 582-8.
  15. Petit JY, Rietjens M, Botteri E, Rotmensz N, Bertolini F, Curigliano G, et al. Evaluation of fat grafting safety in patients with intraepithelial neoplasia: a matched-cohort study. *Ann Oncol* 2013; 24: 1479-84.
  16. Rietjens M, De Lorenzi F, Rossetto F, Brenelli F, Manconi A, Martella S, et al. Safety of fat grafting in secondary breast reconstruction after cancer. *J Plast Reconstr Aesthet Surg* 2011; 64: 477-83.
  17. Rigotti G, Marchi A, Stringhini P, Baroni G, Galie M, Molino AM, et al. Determining the oncological risk of autologous lipoaspirate grafting for post-mastectomy breast reconstruction. *Aesthetic Plast Surg* 2010; 34: 475-80.
  18. Riggio E, Bordoni D, Nava MB. Oncologic surveillance of breast cancer patients after lipofilling. *Aesthetic Plast Surg* 2013; 37: 728-35.
  19. Rubin JP, Coon D, Zuley M, Toy J, Asano Y, Kurita M, et al. Mammographic changes after fat transfer to the breast compared with changes after breast reduction: a blinded study. *Plast Reconstr Surg* 2012; 129: 1029-38.
  20. Lohsiriwat V, Curigliano G, Rietjens M, Goldhirsch A, Petit JY. Autologous fat transplantation in patients with breast cancer: “silencing” or “fueling” cancer recurrence? *Breast* 2011; 20: 351-7.
  21. Yoshimura K, Shigeura T, Matsumoto D, Sato T, Takaki Y, Aiba-Kojima E, et al. Characterization of freshly isolated and cultured cells derived from the fatty and fluid portions of liposuction aspirates. *J Cell Physiol* 2006; 208: 64-76.



---

## การศึกษาเบื้องต้นเกี่ยวกับเซลล์ต้นตอที่พบในไขมันในการฉีดไขมันและปัจจัยที่มีผลต่อการฉีดไขมัน

ประกาศิต จิรปภา, ปวีณา เลือดไทย, ไพศาล บุญสะกันต์, เกตน์ศรี สุริยจันทร์, ภาณุวัฒน์ เลิศสิทธิชัย, เขาวนุช คงคำ, ธงชัย ศุกรโยธิน, มนต์ชัย ลิสมบัติไพบุลย์

**ภูมิหลัง:** การฉีดไขมัน (Lipofilling) ได้ถูกพัฒนาขึ้นเพื่อแก้ไขปัญหาเต้านมผิดปกติหลังการผ่าตัดในผู้ป่วยมะเร็งเต้านม adipose-derived stromal cells (ADSCs) ในไขมันเป็นปัจจัยที่ช่วยเพิ่มอัตราการรอดชีวิตของไขมันที่ฉีดเข้าไปทำให้ผลของการฉีดไขมันคงความสวยงาม จุดมุ่งหมายของการศึกษานี้คือการประเมินปริมาณและสัดส่วนของ ADSCs ในไขมัน และปัจจัยอื่นๆ ที่มีผลต่อการฉีดไขมัน

**วัตถุประสงค์:** จุดมุ่งหมายของการศึกษานี้ คือการประเมินปริมาณและสัดส่วนของ ADSCs ในไขมัน และปัจจัยอื่นๆ ที่มีผลต่อการฉีดไขมัน

**วัสดุและวิธีการ:** เป็นการศึกษาจากเหตุไปหาผลแบบไปข้างหน้า (prospective cohort study) ตั้งแต่ปี พ.ศ. 2557 ถึง 2559 ในผู้ป่วยมะเร็งเต้านมและผู้ป่วยเนื้องอกฟีลโลด (phyllodes tumor) ที่มีภาวะเต้านมผิดปกติหรือเต้านมไม่เท่ากัน ภายหลังจากการผ่าตัดแบบสงวนเต้านมหรือผ่าตัดเสริมสร้างเต้านมใหม่หลังตัดเต้านมทั้งทำการเก็บข้อมูลของการตรวจ cluster of differentiation (CD) markers การมีชีวิตของเซลล์ (cell viability) รวมทั้งปัจจัยอื่นๆ ที่อาจมีผลต่อการฉีดไขมัน

**ผลการศึกษา:** ผลการศึกษาเบื้องต้นพบว่าในผู้ป่วย 13 รายที่ได้รับการฉีดไขมัน ไม่พบว่ามีภาวะแทรกซ้อนของบริเวณที่ทำการฉีดไขมัน แต่พบภาวะแทรกซ้อนของบริเวณที่ทำการฉีดไขมัน คือเกิดฝีที่เต้านมในผู้ป่วยหนึ่งรายและผู้ป่วย 5 ราย พบว่ามีไขมันตายจากภาพถ่ายแมมโมแกรมและอัลตราซาวด์ ผู้ป่วย 2 ใน 5 รายดังกล่าวได้รับการเจาะชิ้นเนื้อพิสูจน์ว่าเป็นไขมันตาย ไขมันของผู้ป่วย 3 ราย ได้ทำการวิเคราะห์ CD markers พบว่าได้ผลเป็น CD45-, CD34+ ในตัวอย่างทั้งหมด และหนึ่งตัวอย่างได้ผลเป็น CD45-, CD34+, CD105- และ CD90+ ซึ่งแสดงถึงการมี ADSCs ในไขมันที่ทำการตรวจ นอกจากนี้ก็ไม่พบว่ามีปัจจัยใดที่มีผลต่อการเกิดไขมันตาย

**สรุป:** การศึกษาที่ใช้ CD markers เพื่อยืนยันว่ามี ADSCs ในไขมันที่ฉีดจริงแต่ในการศึกษาไม่พบปัจจัยที่เกี่ยวข้องกับการเกิดไขมันตาย การศึกษาหลังจากนี้จะรวบรวมผู้ป่วยจำนวนมากขึ้น เพื่อศึกษาผลของการฉีดไขมันกับจำนวนและสัดส่วนของ ADSCs และค้นหาปัจจัยอื่นๆ ที่อาจมีผลต่อการฉีดไขมัน

---