

Case Report

Traumatic Injury in a Child with Scurvy: A Case Report

Chanika Angsanuntsukh MD*, Kulapat Chulsomlee MD*,
Anan Taracheewin MD*, Suphaneewan Jaovisidha MD**,
Thira Woratanarat MD, MMedSc***, Patarawan Woratanarat MD, PhD*

* Department of Orthopaedics, Faculty of Medicine Ramathibodi Hospital, Mahidol University, Bangkok, Thailand

** Department of Radiology, Faculty of Medicine Ramathibodi Hospital, Mahidol University, Bangkok, Thailand

*** Department of Preventive and Social Medicine, Faculty of Medicine, Chulalongkorn University, Bangkok, Thailand

This case report aimed to describe the clinical presentation, treatments and prognosis of a child who had scurvy and traumatic injury of the left thigh. A 30-month-old boy had presented with left hip pain two weeks after falling down on the floor while walking. He developed pain, warmth of the left hip and thigh, and finally was unable to bear weight. He also had a high fever, gingival hemorrhage, dental caries, petechiae, positive rolling test and limited range of motion of the left hip. The radiographs revealed Wimberger's ring and Frenkel line as scurvy. Vitamin C supplement had been prescribed for one week. However, there was no clinical response and magnetic resonance imaging (MRI) suggested subperiosteal abscess as well as osteomyelitis of bilateral femurs and tibiae. Debridement and biopsy of the left femur were performed and found only subperiosteal blood. A clinical improvement was noted on the second day after surgery. Vitamin C level was reported at 0.03 mg/dl which was very low. Bacterial culture was negative and the pathological findings were callus formation with hemorrhage. The patient continued the treatment for two months and all conditions were healed eventually. In severe scurvy with trauma, prolonged subperiosteal hematoma was susceptible to infection, and may need debridement simultaneously with vitamin C supplement to shorten the clinical course.

Keywords: Scurvy, Child, Trauma, Injury

J Med Assoc Thai 2015; 98 (Suppl. 8): S95-S101

Full text. e-Journal: <http://www.jmatonline.com>

Scurvy is a rare condition caused by vitamin C or ascorbic acid deficiency. Vitamin C is significantly required for collagen synthesis by osteoblasts. Patients with scurvy usually present bleeding gums, spontaneous subperiosteal bleeding, especially in the femur and tibia. Symptoms occurred from bleeding response well after vitamin C supplement, mostly within a week. Traumatic injury in the patients with scurvy may increase the severity of subperiosteal bleeding, and may prolong the clinical course as well as the treatment responses. Although there were some reports of various clinical presentations among children with scurvy⁽¹⁻⁵⁾, there was limited evidence of traumatic injury in scurvy. In this case report, the researchers had the purpose to demonstrate a boy, diagnosed as scurvy, who sustained an injury at his left thigh and to describe his clinical presentations, diagnostic tests, clinical decision, treatment methods, and prognosis.

Correspondence to:

Woratanarat P, Department of Orthopedics, Faculty of Medicine Ramathibodi Hospital, Mahidol University, Bangkok 10400, Thailand.

Fax: +66-2-2011599

E-mail: patarawan.wor@mahidol.ac.th

Case Report

The patient was a 30-month-old boy living in Nakhonsawan Province, Thailand. He started to present left hip pain after two weeks of falling down on the floor while walking. He was limp without any wound or external bleeding. On the following day, he complained left hip pain with warmth of his left thigh. He could not walk, or move his left lower extremity due to the pain. His parents had given him an analgesic drug for a few days but his symptoms got worse. He was brought to Sawanpracharak Hospital, Nakhon Sawan Province ten days later. The physical examination revealed afebrile, left sacroiliac joint tenderness, and limited left hip range of motion due to the pain. The complete blood count showed hematocrit 24.9%, mean corpuscular volume 58.2 femtoliters, white blood cell 11,700/mm³ (neutrophil 55%, lymphocyte 36.2%), and platelets 458,000/mm³. The erythrocyte sedimentation rate was 47 mm/hr and C-reactive protein was 17.5 mg/dl. The radiographs of left femur showed mild soft tissue swelling without bony lesion (Fig. 1). Two days later after the check-up, he underwent left hip ultrasonography; the results showed muscle contusion or myositis with subperiosteal collection, no left hip joint effusion. The

orthopedist at Sawanpracharuk Hospital suspected left femoral osteomyelitis and septic arthritis of the left hip. Finally, he was referred to Ramathibodi Hospital, Bangkok. No antibiotic drug was administered at that time.

Tom was the first-born child from a 40-year-old mother. He was normally delivered with birth weight of 3,600 grams. He had a history of asthma exacerbations, normal growth and development, full vaccinations, and no history of surgery. His daily diet was milk and solid foods. He did not consume vegetables or fruits. His family lived in Nakhon Sawan Province located in the upper central region of Thailand. His father was a builder, and his mother was a general employee. National Health Insurance covered his medical treatment.

The physical examination at Ramathibodi Hospital revealed a Thai boy, pale, good consciousness, irritated and crying. His body weight was 18 kilograms (>95th percentile), and height was 91 centimeters (50th percentile). Other vital signs were temperature of 38.3° celsius, blood pressure of 130/90 mmHg, pulse rate 120 beats/minute, and respiratory rate of 30 breaths/minute. The head and neck regions demonstrated dental caries, and gingival hemorrhage. The cardiopulmonary system was normal. The abdomen was soft, not tender, and no hepatosplenomegaly. His skin presented acanthosis nigricans, minimal perifollicular hemorrhage, and petichial hemorrhage at the left arm and forearm. The musculoskeletal system documented inability to bear weight. The left hip was in flexion-external rotation position (Fig. 2), had limited range of motion, and a positive rolling test. The left thigh was swelling, warm and tender. The left knee was warm, with positive ballotement test, and limited range of motion according to level of pain. The distal neurovascular status was intact. The right lower extremity was normal. The provisional diagnosis was scurvy and differential diagnoses were septic arthritis as well as osteomyelitis of the left femur.

The laboratory investigations were done at Ramathibodi Hospital. The complete blood count showed white blood cell 12,970/mm³ (neutrophil 65%, lymphocyte 27%, monocyte 7%, eosinophil 1%), hematocrit 22.5%, mean corpuscular volume 57 femtoliters, anisocytosis 2+, microcytosis 2+, hypochromic 1+; platelets 486,000/mm³. Electrolytes analysis was sodium 138 mmol/L, potassium 4.49 mmol/L, chloride 103 mmol/L, and carbondioxide 29.3 mmol/L. International normalized ratio (INR) was 1.12. Erythrocyte sedimentation rate was 71 mm/hr, and C-

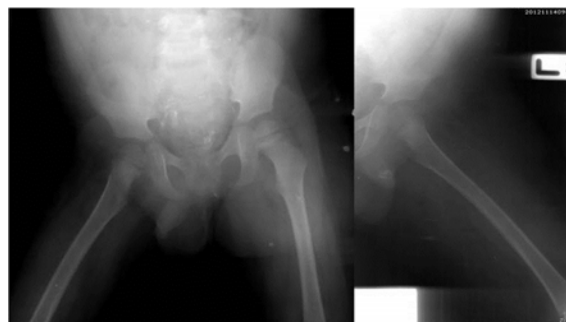

Fig. 1 The radiographs of left femur showed mild soft tissue swelling without bony lesion.

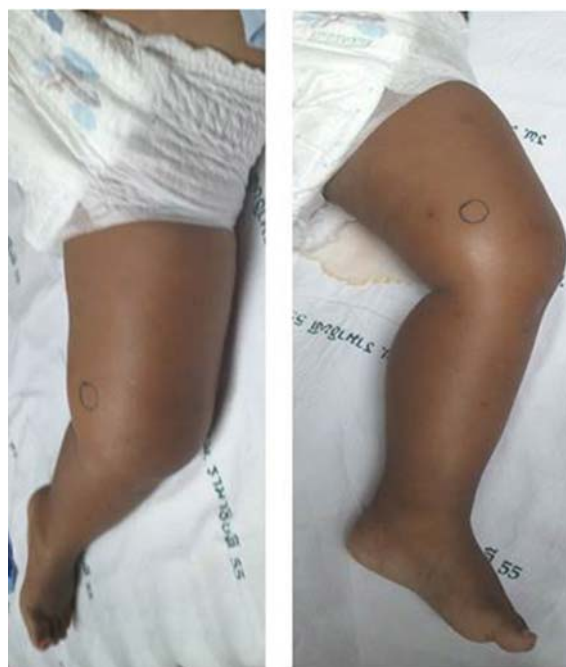

Fig. 2 The left hip was in flexion-external rotation position with the left knee swelling.

reactive protein was 54 mg/L. Serum iron was 9 ug/dL (normal ranged 35.0-150.0 ug/dL). Blood for vitamin C level was collected. The follow-up radiographs showed normal joint space of the left hip without epiphyseal or physeal irregularity. The left femur showed surrounding soft tissue swelling, osteolytic lesion and a thin periosteal formation along metaphyseal-diaphyseal area. There was also soft tissue density around the left knee indicating intra-articular fluid (Fig. 3). The ultrasonography of the left lower extremity showed unremarkable joint fluid at the left hip, heterogenous echogenicity of the left proximal quadriceps muscles

associated with subperiosteal fluid collection and periosteal reaction. There was also left knee effusion (Fig. 4).

Since osteomyelitis of the left femur and septic arthritis of the left knee could not be ruled out, the patient was brought to the operation room for the left femur and the left knee aspiration. From the left femur, there was 5 ml of fresh blood. There was 2 ml of clear fluid with 78 white blood cells (polymononuclear cell 60% and monocyte 40%) followed by fresh blood. The fluid was sent for bacteria culture. A long leg slab extended to hip was applied at the left lower extremity. Intravenous 650-mg cefazolin was administered every eight hours. Since his hematocrit was only 19.5%, 200-ml O-group leukocyte-poor blood was given intravenously rising his hematocrit up to 30%. A

pediatric nutritionist prescribed 100-mg vitamin C three times a day, multivitamin syrup 5 ml once daily, calcium carbonate 600 mg twice daily, and zinc sulfate 2.5 ml twice daily. On the 3rd admission day, bacterial culture was negative.

The patient had had a high fever ranged from 38.5-40.0° celsius since the admission. On the 5th day, the follow-up radiographs showed soft tissue swelling, solid periosteal formation, Frankel line, Pelkan spurs, and Wimberger's ring at the left femur. However, MRI of the left femur suggested diffused osteomyelitis of the entire femurs and tibias bilaterally (Fig. 5). There were diffused marrow enhancement of bilateral pelvic bones, sacrums, femurs and tibias with surrounding periosteal reaction and multiple visualized inguinal lymph nodes. Diffused subcutaneous soft tissue swelling was detected from the left hip to the left ankle.

The left femoral shaft revealed subperiosteal

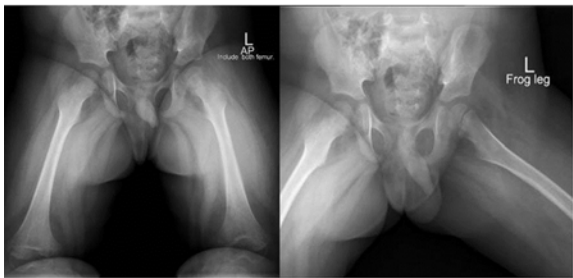


Fig. 3 On the admission date, the radiographs of the left femur showed surrounding soft tissue swelling, osteolytic lesion and thin periosteal formation along metaphyseal-diaphyseal area. The soft tissue density around the left knee indicated intra-articular fluid.

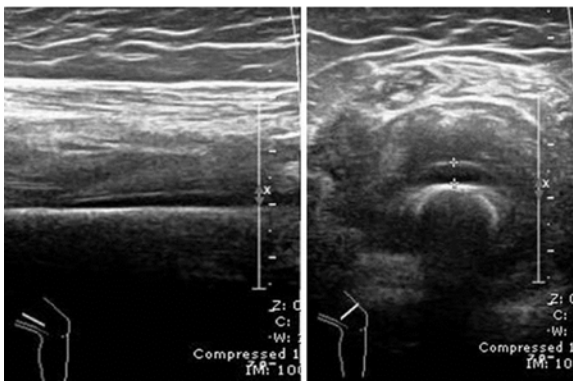


Fig. 4 The ultrasonography of the left lower extremity, Right: heterogenous echogenicity of the left proximal quadriceps muscles indicated subperiosteal fluid collection, and Left: left knee effusion.

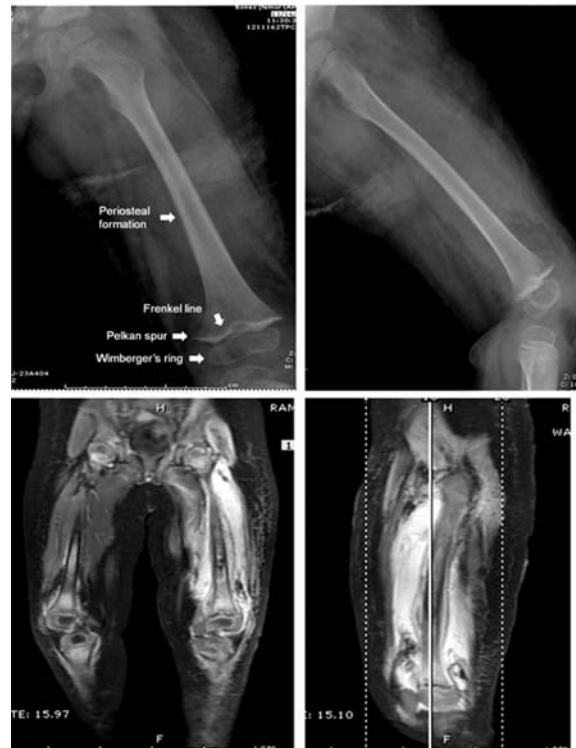

Fig. 5 Above: the radiographs on the 4th day of admission showed soft tissue swelling, solid periosteal formation, Frankel line, Pelkan spurs, and Wimberger's ring at the left femur, Below: MRI demonstrated diffused marrow enhancement of bilateral pelvic bones, sacrums, femurs and tibias with subperiosteal abscess along the left thigh.

abscess with 2-4 mm in thickness. There were also moderate joint effusion at the left knee, mild right knee synovitis, tiny abnormal fat signals within proximal left tibia, and a small focal cortical bony defect at the right proximal tibia. As the MRI findings were similar to typical scurvy, the patient had been observed, and antibiotic administration had been stopped for three days. On the 8th day, the patient still had a high fever and painful limb. Bone and joint infection on top was suspected, therefore, the debridement was set up. A small lateral incision was done at the left thigh (Fig. 6). The intra-operative findings were subperiosteal blood and no pus was seen. The tissue biopsy was performed and a long leg slab was applied. Blood components of 180-ml leukocyte-poor blood and 180-ml fresh frozen plasma were given postoperatively. The patient was clinically stable but still had a high fever for a few days.

On the 12th day of admission, the clinical manifestation was dramatically improved. The patient had no fever. Intravenous cefazolin was changed to oral cephalexin (100 mg/kg/day). Ferrous fumarate 1.2 ml twice daily was prescribed for iron deficiency treatment. The reported vitamin C level since the hospital admission was 0.03 mg/dl (below 0.2 mg/dl). The pathological diagnosis was callus formation with hemorrhage and mild chronic inflammation. The final diagnosis was scurvy and iron deficiency. The patient was discharged on the 14th day of admission. Home medications were vitamin C, multivitamin, calcium carbonate, zinc sulfate, and ferrous fumarate which had to be continuously taken for two months; cephalexin for three weeks, and paracetamol for pain rescue.

Two weeks after the hospital discharge, Tom was active, no gum bleeding, good surgical wound healing, and solid periosteal formation was seen at the entire left femur (Fig. 7). Two months later, he was healthy and ran around without any pain. The radiographic solid callus formation presented at the left femur. In the following six months, he was perfectly well and took vitamin every day. His left femur remodeled. At the latest follow-up, he was a 5-year-old kindergarten boy without scurvy recurrence or any malnutrition problem. His clinical courses were summarized as Table 1.

Discussion

Scurvy was a disease caused by vitamin C deficiency. It has been recognized a long time ago⁽⁶⁾ and discovered how to diagnose and prevent^(7,8). There are various recommendations and strategies to prevent vitamin C deficiency in children such as breast milk,

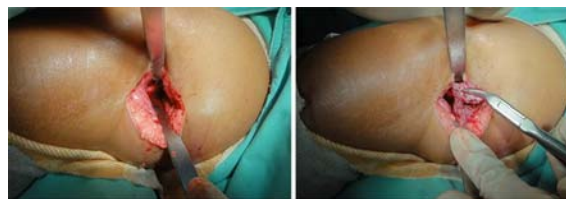

Fig. 6 The skin incision was made on the lateral aspect of the left thigh, and tissue biopsy was performed.

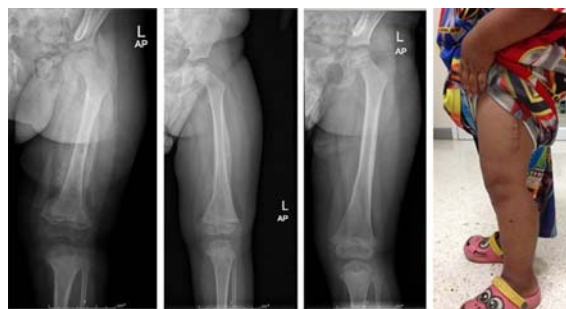

Fig. 7 From left to right, the radiographs of the left femur at one, three, and six months after the treatment. There was profuse callus formation followed by bone remodeling. The child was fully recovered.

orange juice but the disease still presents sporadically and is misdiagnosed in many reports according to different clinical presentations^(5,9). This study demonstrated the traumatic complaints in a child resulting in inability to walk for 3 weeks. Even though the bleeding gums were accompanied with a history of limited fruits and vegetables consumption leading to scurvy diagnosis which prompted treatment, the clinical course was prolonged with high fever for nearly two weeks. An infected hematoma, as well as subacute osteomyelitis was of concern. An irrigation and drainage procedure evacuated hematoma, which could be a good media for bacteria. Finally, the clinical response was dramatic during the following two days. Traumatic injury in scurvy had limited data about its clinical course. A previous study from Thailand in 2003⁽¹⁾ reported the most common clinical presentations in 28 children were inability to walk (96%), followed by limb pain (96%) tenderness of lower limbs (86%), and minor trauma (46%). Other studies^(2-4,10-15) documented chief complaints mostly gum bleeding, inability to walk, limb pain or swelling caused by subperiosteal bleeding (Table 1). In this study, the child had prolonged high fever for 11 days after taking standard a vitamin C supplement (300 mg/day). The radiographic findings showed extensive bone marrow enhancement from

Table 1. Clinical summary of children with scurvy

Study	Country	No. of cases	Age (year)	Gender	Presentation	Duration	Vitamin C level*	Vitamin C supplement
Ratanachu-ek 2003 ⁽¹⁾	Thailand	28	1-9	17 M, 11 F	Inability to walk, limb pain, minor trauma, gum bleeding	3.9 week	0.31-2.1 mg/dl	150-300 mg/d
Choi 2007 ⁽⁹⁾	Korea	1	5	F	Mild fever, thigh swelling	2 week	0.06 mg/dl (0.6-2.0)	NA
Bursali 2009 ⁽¹⁵⁾	Turkey	1	1	M	Inability to walk, knees pain, gum bleeding	NA	NA	1,500 mg/d
Ghedira Besbes 2010 ⁽¹⁶⁾	Tunisia	2	2, 5	2 M	Fever, inability to walk, knees swelling, gum bleeding	3 week	<3 µmol/l (26.1-84.6)	500 mg/d
Noordin 2012 ⁽¹⁴⁾	Pakistan	1	4.5	M	Fever, inability to walk, wrist, knee, ankle swelling	2-3 month	NA	250 mg/d
Duvall 2013 ⁽¹³⁾	USA	1	9	M	Limp	4 month	Undetected (0.4-2.0 mg/dl)	Multi-vitamin
Gongidi 2013 ⁽¹²⁾	USA	1	5	M	Fell, leg, wrists, and back pain	4 weeks	<0.1 mg/dl (0.6-2.0)	NA
Hag 2013 ⁽¹⁷⁾	India	1	6	M	Knee swelling	3 month	NA	200 mg/d
Rumsey 2013 ⁽¹¹⁾	Canada	1	8	M	Knees, ankles swelling	3 month	22 µmol/l (23-114)	NA
Kitcha-roensakkul 2014 ⁽²⁾	USA	3	5	2 M, 1 F	Inability to walk, gum bleeding	1-5 month	<0.1, 1.1 mg/dl (0.6-2.0)	300 mg/d
Pailhous 2014 ⁽¹⁰⁾	France	2	7	2 M	Gum bleeding	1 month	<3 µmol/l (17-94) <0.5 mg/l (5-15)	500 mg/d
Sobotka 2014 ⁽⁴⁾	USA	1	10	M	Inability to walk, knee swelling, gum bleeding	4 weeks	<0.12 mg/dl (0.2-1.9)	NA
Agarwal 2015 ⁽³⁾	India	1	4	M	Fever, thigh and knee swelling	15 day	NA	NA
This study 2015	Thailand	1	2	M	High fever, inability to walk, hip, thigh, knee swelling, gum bleeding	3 week	0.03 mg/dl (0.2-2.0)	300 mg/d

M = male, F = female, * reference range of vitamin C level in brackets, NA = not available

pelvis, sacrum, femurs, and tibiae. The delayed clinical responses and severe marrow involvement may occur from 1) profound subperiosteal bleeding due to traumatic injury, and substantially low level of vitamin C, and 2) impending infected hematoma according to massive subperiosteal bleeding and dental caries. Compared with other studies^(1,4,9-17), fever was only 18% and usually subsided by one week after the treatment⁽¹⁾. The radiographic findings were typically scurvy characteristics but had more extensive bone marrow

enhancement than other previous reports^(9,12,15).

The vitamin C level in this study was very low (0.03 mg/dl or 1.70 mmol/l) when compared with other studies^(1,9,11). The deficiency led to abnormal collagen synthesis, severe symptoms, extensive subperiosteal bleeding, anemia, and prolonged clinical course. Vitamin C supplement between 150-300 mg/day for two months was recommended^(1,14). Even though some studies^(10,15,16) used vitamin C of 500-1,500 mg/day, the dosage does not depend on the severity of its

deficiency. The average duration of recovery after the treatment ranged from 1-4 weeks^(1,13,14).

In general, debridement and irrigation is unnecessary for scurvy treatment. This case report had prolonged high fever and was suspected to be infected with hematoma. Normally, fever should subside within one week⁽¹³⁾. Therefore, debridement and irrigation was performed. With this combined treatment, duration of clinical improvement was 11 days and the patient could return to normal gait within two months. These findings are the same as other reports^(1,13,14) with the average duration of clinical improvement at 2.2 weeks, and the average duration of return to normal gait at 3.5 weeks. Injury may increase amount of bleeding in scurvy. If this condition was left untreated accompanied with dental caries, hematoma was at risk of infection. This study demonstrated the usefulness of debridement and irrigation in scurvy with prolonged high fever suspected from impending infected hematoma. Debridement and irrigation in scurvy should be considered in patients who have clinical unresponsiveness after vitamin C supplement with highly suspected infected hematoma.

Potential conflicts of interest

None.

References

1. Ratanachu-ek S, Sukswai P, Jeerathanyasakun Y, Wongtapradit L. Scurvy in pediatric patients: a review of 28 cases. *J Med Assoc Thai* 2003; 86 (Suppl 3): S734-40.
2. Kitcharoensakkul M, Schulz CG, Kassel R, Khanna G, Liang S, Ngwube A, et al. Scurvy revealed by difficulty walking: three cases in young children. *J Clin Rheumatol* 2014; 20: 224-8.
3. Agarwal A, Shaharyar A, Kumar A, Bhat MS. A swollen thigh and knee pain in a cerebral palsy child-Scurvy. *Joint Bone Spine* 2015 Mar 13. [Epub ahead of print]
4. Sobotka SA, Deal SB, Casper TJ, Booth KV, Listernick RH. Petechial rash in a child with autism and Trisomy 21. *Pediatr Ann* 2014; 43: 224-6.
5. Talarico V, Aloe M, Barreca M, Galati MC, Raiola G. Do you remember scurvy? *Clin Ter* 2014; 165: 253-6.
6. Carpenter G. A Case of Scurvy. *Proc R Soc Med* 1909; 2: 180-2.
7. Park EA, Guild HG, Jackson D, Bond M. The recognition of scurvy with especial reference to the early x-ray changes. *Arch Dis Child* 1935; 10: 265-94.
8. Desenclos JC, Berry AM, Padt R, Farah B, Segala C, Nabil AM. Epidemiological patterns of scurvy among Ethiopian refugees. *Bull World Health Organ* 1989; 67: 309-16.
9. Choi SW, Park SW, Kwon YS, Oh IS, Lim MK, Kim WH, et al. MR imaging in a child with scurvy: a case report. *Korean J Radiol* 2007; 8: 443-7.
10. Pailhous S, Lamoureux S, Caietta E, Bosdure E, Chambost H, Chabrol B, et al. Scurvy, an old disease still in the news: two case reports. *Arch Pediatr* 2015; 22: 63-5.
11. Rumsey DG, Rosenberg AM. Childhood scurvy: a pediatric rheumatology perspective. *J Rheumatol* 2013; 40: 201-2.
12. Gongidi P, Johnson C, Dinan D. Scurvy in an autistic child: MRI findings. *Pediatr Radiol* 2013; 43: 1396-9.
13. Duvall MG, Pikman Y, Kantor DB, Ariagno K, Summers L, Sectish TC, et al. Pulmonary hypertension associated with scurvy and vitamin deficiencies in an autistic child. *Pediatrics* 2013; 132: e1699-703.
14. Noordin S, Baloch N, Salat MS, Rashid MA, Ahmad T. Skeletal manifestations of scurvy: a case report from dubai. *Case Rep Orthop* 2012; 2012: 624628.
15. Bursali A, Gursu S, Gursu A, Yildirim T. A case of infantile scurvy treated only with vitamin C: a forgotten disease. *Acta Orthop Belg* 2009; 75: 428-30.
16. Ghedira BL, Haddad S, Ben Meriem C, Golli M, Najjar MF, Guediche MN. Infantile scurvy: two case reports. *Int J Pediatr* 2010; 2010: 717518.
17. Haq RU, Dhammi IK, Jain AK, Mishra P, Kalivanan K. Infantile scurvy masquerading as bone tumour. *Ann Acad Med Singapore* 2013; 42: 363-5.

รายงานผู้ป่วยเด็กโรคกระดูกเปิดที่ได้รับอุบัติเหตุ

ชนิกา อังสนันทสุข, กุลพัชร จุลสำลี, อนันต์ ธาราชวิน, สุนันวีวรรณ เขาวีสิษฐ, ธีระ วรรณรัตน์, ภทรวณย์ วรรณรัตน์

รายงานนี้มีวัตถุประสงค์เพื่ออธิบายลักษณะทางคลินิก การรักษาและการพยากรณ์โรคของเด็ก โรคกระดูกเปิดที่ได้รับอุบัติเหตุบริเวณต้นขาซ้าย เด็กชายอายุ 30 เดือน ปวดสะโพกซ้าย 2 สัปดาห์หลังจากหกล้ม ปวดรื้อนสะโพกและต้นขาซ้าย ไม่สามารถเดินลงน้ำหนัก มีไข้เลือดออกตามไรฟัน ฟันผุ มีจุดเลือดออกตามผิวหนัง ปวดเวลาหมุนสะโพกและจำกัดพิสัยข้อสะโพก ภาพรังสีพบ Wimberger's ring, Frenkel line เข้าได้กับโรคกระดูกเปิด เมื่อให้วิตามินซีนาน 1 สัปดาห์อาการไม่ดีขึ้น คลื่นไส้เหล็กไฟฟ้าพบ subperiosteal abscess และ osteomyelitis บริเวณ femur และ tibia ทั้งสองข้าง ผู้ป่วยได้รับการผ่าตัดล้าง femur ข้างซ้ายและส่งตรวจชิ้นเนื้อพบ subperiosteal blood จากนั้น 2 วันอาการดีขึ้น ผลตรวจระดับวิตามินซีเท่ากับ 0.03 มิลลิกรัมต่อเดซิลิตร ซึ่งมีค่าต่ำมาก ผลเพาะเชื้อไม่พบเชื้อ ผลพยาธิวิทยาพบ callus formation และ hemorrhage ผู้ป่วยได้รับการรักษาเป็นเวลา 2 เดือนและหายเป็นปกติ โรคกระดูกเปิดที่พบร่วมกับอุบัติเหตุมี subperiosteal hematoma เป็นเวลานาน มีโอกาสติดเชื้อและอาจต้องผ่าตัดล้างร่วมกับให้วิตามินซีเพื่อลดระยะเวลาการดำเนินโรค
