

Accuracy of Acetabular Cup Placement in Navigated THA with Modified Registration Technique in Semilateral Decubitus Position

Yingyong Suksathien MD*,
Rachawan Suksathien MD**, Porameth Chaiwirattana MD*

* Department of Orthopedic Surgery, Maharat Nakhon Ratchasima Hospital, Thailand

** Department of Rehabilitation Medicine, Maharat Nakhon Ratchasima Hospital, Thailand

Background: The accuracy of cup placement in navigated total hip arthroplasty (THA) depends on the bony landmark registration intraoperatively. We created a semilateral decubitus position that combined the advantage of supine position for registration and lateral decubitus position for better femoral canal visualization.

Objective: To evaluate the accuracy of cup placement within the “safe zone” and of imageless navigation measurement by comparing the intraoperative values of acetabular cup abduction and anteversion to postoperative CT values.

Material and Method: All cases were performed in semilateral decubitus position with OrthoPilot THA plus 3.2 (cup only) software (Aesculap AG). Postoperatively, a multislice computed tomographic (CT) scan was obtained at two months or later for abduction and anteversion angle measurement. The abduction and anteversion angle measured on postoperative CT were compared to the intraoperative measurement with a paired t-test and a correlation test at a 0.05 level of significance.

Results: Sixty-five cases were included in the present study. The median CT abduction value was 41°, range 35° to 48° and the median navigated abduction value was 39.8°, range 37.5° to 45.5°. The median paired difference was 1.6°, range -3.4° to 7.9°, this difference was significant ($p < 0.001$). The median CT anteversion value was 15°, range 8° to 28° and the median navigated anteversion value was 12°, range 5.9° to 16.5°. The mean paired difference was 3.2°, range -2.6° to 14.9°, this difference was significant ($p < 0.0001$).

Conclusion: Navigated THA with modified registration technique in semilateral decubitus position offered a more precise cup position as in supine and lateral decubitus position. It combined the advantage of supine position for registration and lateral decubitus position for better femoral canal visualization. Our modified registration technique by compressing the soft tissue above pubic symphysis (PS) to the abdomen and registering at the antero-superior-pubic-symphysis (ASPS) help us to increase the accuracy of anteversion angle.

Keywords: Hip arthroplasty, Imageless navigation

J Med Assoc Thai 2014; 97 (10): 1089-95

Full text. e-Journal: <http://www.jmatonline.com>

Malalignment of the acetabular component has been linked to increase dislocation rate, impingement, pelvic osteolysis, cup migration, leg length discrepancy and polyethylene wear in patients undergoing total hip arthroplasty (THA)⁽¹⁾. Lewinnek et al⁽²⁾ had defined a “safe zone” for the acetabular component placement, which they postulated, would decrease the incidence of dislocation. The safe zone widely accepted by various authors is abduction of 40°±10° and anteversion of 15°±10°. Freehand techniques rely on manual guides or the surgeon’s ability to estimate the cup orientation in relation to

the patient’s position on the operating table. Using conventional techniques, placement within the safe zone, as described by Lewinnek et al⁽²⁾, remains a challenge even for experienced surgeons. Callanan et al⁽³⁾ determined the percent of optimally positioned acetabular cups in 1,823 hips and demonstrated that 1,144 (63%) acetabular cups were within the abduction range, 1,441 (79%) were within the anteversion range and 917 (50%) were within the range of both. Digioia et al⁽⁴⁾ demonstrated that 78% of cups in freehand technique were placed outside the safe zone.

Several researchers⁽⁵⁻¹⁰⁾ had reported that imageless navigation is a safe and reliable technique and results in more precise cup placement compared to conventional freehand techniques. The accuracy of cup placement in navigated THA depends on the bony landmark registration intraoperatively. The usual

Correspondence to:

Suksathien Y, Department of Orthopedic Surgery, Maharat Nakhon Ratchasima Hospital, Chang Phueak Road, Mueang District, Nakhon Ratchasima 30000, Thailand.

Phone: 044-235-529, Fax: 044-259-677

E-mail: ysuksathien@yahoo.com

patient position for registration is supine, but supine position has some drawbacks such as it is more difficult for femoral stem visualization and implantation. The alternate patient position is lateral decubitus, but registration in this position may be unreliable because the contralateral ASIS cannot be palpated accurately. The other technique is registration in the supine position first and then placing the patient in the lateral decubitus position for operation. The drawbacks of this technique are time consumption and increase risk of contamination.

The authors created a semilateral decubitus position that combined the advantage of supine position for registration and lateral decubitus position for better femoral canal visualization. After finishing the cup, the operating table was tilted forward until the patient was in the lateral decubitus position. Then the patient's leg was dropped anteriorly to perform the femoral stem (Fig. 1). The authors modified the registration technique by compressing the soft tissue above pubic symphysis (PS) to the abdomen and registered at the antero-superior-pubic-symphysis (ASPS) to reduce the anteversion error (Fig. 2).

The purpose of the present study was to evaluate the accuracy of cup placement within the

“safe zone” and the accuracy of imageless navigation measurement by comparing the intraoperative values of acetabular cup abduction and anteversion to postoperative CT values. To our knowledge, there is no study about the accuracy of the navigated THA in semilateral decubitus position.

The authors hypothesized that navigated THA in semilateral decubitus position with modified registration technique would be as accurate as in supine and lateral decubitus position.

Material and Method

The present study was approved by the Ethic Committee of Maharat Nakhon Ratchasima Hospital. Between June 2012 and April 2013, patients requiring total hip arthroplasty were prospectively enrolled in the present single-center study. The exclusion criteria were patients who were not suitable for cementless cup and refused to participate in this study. All cases were received short stem cementless THA (Metha and Plasmacup SC; B. Braun Aesculap, Tuttlingen, Germany) with navigator by a single surgeon (YS). All cases were performed in semilateral decubitus position with OrthoPilot THA plus 3.2 (cup only) software (Aesculap AG). A screw was inserted into the

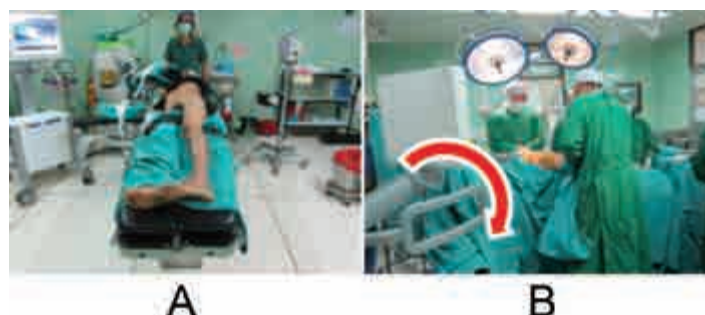

Fig. 1 (A) A patient was registered for APP plane and undergoing the cup in the semilateral decubitus position. (B) The operating table was tilted forward to lateral decubitus position and the patient's leg was dropped anteriorly to perform the femoral stem.

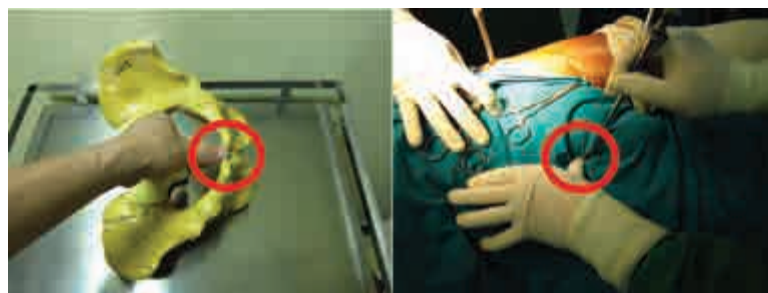

Fig. 2 The modified registration technique registered at the antero-superior-pubic-symphysis (ASPS).

ipsilateral ASIS through a stab incision. The pelvic navigation tracker was attached to the screw. Bony landmarks (both ASIS and ASPS) were determined and digitalized with a metal pointer to define anterior pelvic plane (APP). All patients were performed with modified Hardinge's approach. After removal of the femoral head, the deepest point of the acetabular fossa was registered as an additional reference point. Then, by using the trial cup, the native abduction and anteversion angle of the acetabulum were determined. During reaming, the position of the reamer was acquired by the navigation system and the operating surgeon was provided with real-time information about the resulting position of the reamer (medialization, cranialization and antero-posterior direction) and its orientation (abduction and anteversion) in relation to APP as well as the native acetabulum. After reaching the design reaming position, the final cup was implanted, the operating surgeon was provided with real-time information about the cup position and

orientation. Cup orientation was aimed at $40^{\circ} \pm 5^{\circ}$ of abduction and $15^{\circ} \pm 5^{\circ}$ of anteversion in all cases. The final cup position was saved by the navigation system. After finishing the cup, the operating table was tilted forward until the patient was in the lateral decubitus position, then the patient's leg was dropped anteriorly to perform the femoral stem with the conventional freehand technique.

Postoperatively, a multislice computed tomographic (CT) scan was obtained at two months or later for abduction and anteversion angle measurement. The largest cup diameter in the coronal plane was identified and the abduction angle was measured. The anteversion angle was measured by identifying the largest cup diameter in the axial plane. Soft tissue thickness overlying the anterior superior iliac spine (ASIS) and the pubis symphysis (PS) were measured in axial CT image (Fig. 3). All measurements were performed three times and averaged by PC who was not involved in the surgery. The demographic

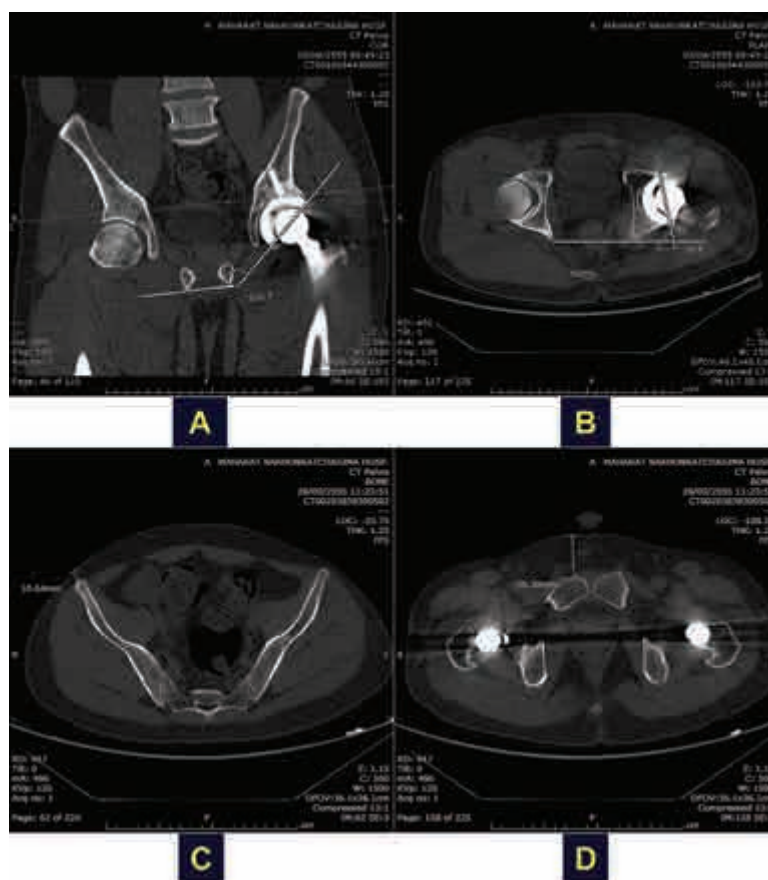


Fig. 3 Postoperative CT-scan evaluation (A) abduction, (B) anteversion, (C) soft tissue thickness overlying the anterior superior iliac spine (ASIS) and (D) soft tissue thickness overlying the pubis symphysis (PS).

data such as age, gender, body mass index (BMI), and diagnosis were recorded (Table 1).

Statistical analysis

The abduction and anteversion angle measured on postoperative CT were compared to the intraoperative measurement with a Wilcoxon Signed Rank test and a Spearman rank correlation test with Stata version 10.0. A *p*-value less than 0.05 was considered statistically significant. The number of outliers was also recorded for each individual direction and as a whole.

Results

Sixty-five cases were included in the present study. The mean patient age was 45.4 years (SD 12.6), range 18 to 68 and 72.3% of the cases were men. The main diagnosis was osteonecrosis of the femoral head (ONFH) (90.8%). The mean BMI was 22.27 kg/m² (SD 3.1), range 16.2 to 29.8 (Table 1) and there was no dislocation or infection.

The median CT abduction value was 41°, range 35° to 48° and the median navigated abduction value was 39.8°, range 37.5° to 45.5°. The median paired difference was 1.6°, range -3.4° to 7.9°, this difference was significant (*p*<0.001). There was a significant correlation between the CT abduction and navigated abduction (*r* = 0.63, *p*<0.0001). All cases

were within the safe zone of CT measurement, and 98.5% of the cases showed a difference of less than 5° between the two measurements. The median CT anteversion value was 15°, range 8° to 28° and the median navigated anteversion value was 12°, range 5.9° to 16.5°. The median paired difference was 3.2°, range -2.6° to 14.9°, this difference was significant (*p*<0.0001). There was a significant correlation between the CT anteversion and navigated anteversion (*r* = 0.26, *p* = 0.0375). Sixty-four cases (64/65, 98.5%) were within the safe zone of CT measurement and 49 cases (49/65, 75.38%) showed a difference of less than 5° between the two measurements (Table 2).

The authors evaluated the effect of soft tissue thickness on the difference of CT value and navigated value. Soft tissue thickness overlying the ASIS and PS were measured in axial CT images resulting in median of 7.7 mm, range 2.9 to 41.1 and 32.4 mm, range 11.7 to 54.6 respectively. The authors found significant correlation between the difference of abduction and the thickness of the soft tissue above the ASIS (*r* = 0.27, *p*<0.0001) but no significant correlation between the difference of anteversion and the thickness of the soft tissue above the PS (*r* = 0.13, *p* = 0.2847). The mean BMI was 22.27 (SD 3.1), range 16.2 to 29.8. We found no significant correlation between BMI and the difference of abduction (*r* = 0.2, *p* = 0.1151) or anteversion (*r* = 0.08, *p* = 0.5160).

Table 1. Demographics data of navigated-THA patients

Characteristic	Total n = 65
Gender, n (%)	
Male	47 (72.3)
Female	18 (27.7)
Age (years), mean (SD), range	45.4 (12.6), 18-68
BMI (kg/m ²), mean (SD), range	22.3 (3.1), 16.2-29.8
Diagnosis, n (%)	
ONFH	59 (90.8)
Post traumatic arthritis	5 (7.7)
Fracture neck of femur	1 (1.5)

THA = total hip arthroplasty; BMI = body mass index; ONFH = osteonecrosis of the femoral head

Discussion

Intraoperative palpation to define bony landmarks by the surgeon using a pointer is a decisive step during the registration process of navigated-THA. This procedure remains an important source of inaccuracy in the imageless navigation system procedure. Percutaneous registration method shows more error in cup anteversion than in abduction. Lee et al⁽¹¹⁾ demonstrated in a sawbone study that when palpating 10 mm above the pubic symphysis and 0 mm above the ASIS, the anteversion angle would be underestimated at approximately 7°.

Several researchers had studied about the accuracy of imageless navigation system in many

Table 2. Comparison of CT value and NAV value

	CT value median (range)	NAV value median (range)	Paired difference median (range)	<i>p</i> -value
Abduction angle	41° (35° to 48°)	39.8° (37.5° to 45.5°)	1.6° (-3.4° to 7.9°)	<0.001
Anteversion angle	15° (8° to 28°)	12.0° (5.9° to 16.5°)	3.2° (-2.6° to 14.9°)	<0.0001

CT = computed tomography, NAV = navigation

patients' positions, approaches, and registration techniques. Jenny et al⁽¹²⁾ used the antero-lateral approach and registration in the supine position and demonstrated that the mean difference between navigated abduction and CT-scan abduction was $-2^{\circ} \pm 4^{\circ}$ (range -12° to 9°) This difference was significant ($p = 0.003$). The mean difference between navigated anteversion and CT-scan anteversion was $-4^{\circ} \pm 8^{\circ}$ (range -25° to 19°), this difference was significant ($p = 0.003$). Sendtner et al⁽¹³⁾ used the modified Smith-Petersen approach and registration in the lateral decubitus position and demonstrated that the mean difference between the cup abduction and anteversion values displayed by navigation and CT-scan was 0.37° (SD 3.26) and -5.6° (SD 6.48) respectively. Lin et al⁽¹⁴⁾ used the limited posterior approach and registration in the lateral decubitus position and demonstrated that the mean anteversion difference between CT value and navigated value was 3.4 ± 3.6 (range -4 to 13) while the mean abduction difference was $0.0^{\circ} \pm 2.8^{\circ}$ (range 4° to 15°). The abduction was more significantly accurate ($p = 0.001$). Kumar et al⁽¹⁵⁾ registered in the supine position and then repositioned to the lateral decubitus and used the standard posterior approach. They demonstrated that the mean deviation of the navigated value from the CT value was 5.3° (range 1° to 13°) for abduction and 5.6° (range 1° to 17°) for anteversion.

Consistent with our results, we found that the median CT abduction was 41° , range 35° to 48° and the median navigated abduction was 39.8° , range 37.5° to 45.5° . The median paired difference was 1.6° , range -3.4° to 7.9° which was significant ($p < 0.001$) but considered to be clinically irrelevant. The median CT anteversion was 15° , range 8° to 28° and the median navigated anteversion was 12° , range 5.9° to 16.5° . The median paired difference was 3.2° , range -2.6° to 14.9° , which was significant ($p < 0.0001$) but considered to be clinically irrelevant. Our results showed that navigated THA in semilateral decubitus position with modified registration technique in the present study offered the accurate alignment as in supine and lateral decubitus position.

The abduction measurements were more accurate than the anteversion measurements in the present study, due to lesser soft tissue thickness overlying the anterior superior iliac spine as compare to the pubic symphysis with median of 7.7 mm, range 2.9 to 41.1 and 32.4 mm, range 11.7 to 54.6 respectively. The authors found significant correlation between the difference of abduction and the thickness of the soft tissue above the ASIS ($r = 0.27$, $p < 0.0001$). The

anteversion error in the present study was slightly smaller than some previous studies. These results showed that our modified registration technique by compressing the soft tissue above pubic symphysis (PS) to the abdomen and registering at the antero-superior-pubic-symphysis (ASPS) help us to increase the accuracy of registration. The authors found no significant correlation between the difference of anteversion and the thickness of the soft tissue above the PS ($r = 0.13$, $p = 0.2847$). The BMI of the patients had no effect on the accuracy of registration with this technique. In the present study we found no significant correlation between the BMI and the difference of abduction ($r = 0.2$, $p = 0.1151$) or anteversion ($r = 0.08$, $p = 0.5160$).

In conclusion, the present study showed that the navigated THA with modified registration technique in semilateral decubitus position offered a more precise cup position than in supine and lateral decubitus position. It combined the advantage of supine position for registration and lateral decubitus position for better femoral canal visualization. Our modified registration technique by compressing the soft tissue above pubic symphysis (PS) to the abdomen and registering at the antero-superior-pubic-symphysis (ASPS) help us to increase the accuracy of anteversion angle. The abduction measurements were more accurate than the anteversion measurements.

What is already known on this topic?

The imageless navigation is a safe and reliable technique and results in more precise cup placement compared to conventional freehand techniques. The accuracy of cup placement in navigated THA depends on the bony landmark registration intraoperatively. The usual patient position for registration is supine, but supine position has some drawbacks such as it is more difficult for femoral stem visualization and implantation. The alternate patient position is lateral decubitus, but registration in this position may be unreliable because the contralateral ASIS cannot be palpated accurately. The other technique is registration in the supine position first and then placing the patient in the lateral decubitus position for operation. The drawbacks of this technique are time consumption and increase risk of contamination.

What this study adds?

The navigated THA with modified registration technique in semilateral decubitus position offered a more precise cup position as in supine and lateral

decubitus position. It combined the advantage of supine position for registration and lateral decubitus position for better femoral canal visualization. Our modified registration technique by compressing the soft tissue above pubic symphysis (PS) to the abdomen and registering at the antero-superior-pubic-symphysis (ASPS) help us to increase the accuracy of anteversion angle.

Acknowledgement

The authors wish to acknowledge Dr. Urawit Piyapromdee, MD, for assisting in the statistical analysis.

Potential conflicts of interest

None.

References

- Kennedy JG, Rogers WB, Soffe KE, Sullivan RJ, Griffen DG, Sheehan LJ. Effect of acetabular component orientation on recurrent dislocation, pelvic osteolysis, polyeth-ylene wear, and component migration. *J Arthroplasty* 1998; 13: 530-4.
- Lewinnek GE, Lewis JL, Tarr R, Compere CL, Zimmerman JR. Dislocations after to-tal hip-replacement arthroplasties. *J Bone Joint Surg Am* 1978; 60: 217-20.
- Callanan MC, Jarrett B, Bragdon CR, Zurakowski D, Rubash HE, Freiberg AA, et al. The John Charnley Award: risk factors for cup malpositioning: quality improvement through a joint registry at a tertiary hospital. *Clin Orthop Relat Res* 2011; 469: 319-29.
- Digioia AM, III, Jaramaz B, Plakseychuk AY, Moody JE Jr., Nikou C, Labarca RS, et al. Comparison of a mechanical acetabular alignment guide with computer placement of the socket. *J Arthroplasty* 2002; 17: 359-64.
- Kalteis T, Handel M, Bathis H, Perlick L, Tingart M, Grifka J. Imageless navigation for insertion of the acetabular component in total hip arthroplasty: is it as accurate as CT-based navigation? *J Bone Joint Surg Br* 2006; 88: 163-7.
- Parratte S, Argenson JN. Validation and usefulness of a computer-assisted cup-positioning system in total hip arthroplasty. A prospective, randomized, controlled study. *J Bone Joint Surg Am* 2007; 89: 494-9.
- Hohmann E, Bryant A, Tetsworth K. A comparison between imageless navigated and manual freehand technique acetabular cup placement in total hip arthroplasty. *J Arthroplasty* 2011; 26: 1078-82.
- Najarian BC, Kilgore JE, Markel DC. Evaluation of component positioning in primary total hip arthroplasty using an imageless navigation device compared with traditional methods. *J Arthroplasty* 2009; 24: 15-21.
- Gandhi R, Marchie A, Farrokhyar F, Mahomed N. Computer navigation in total hip replacement: a meta-analysis. *Int Orthop* 2009; 33: 593-7.
- Moskal JT, Capps SG. Acetabular component positioning in total hip arthroplasty: an evidence-based analysis. *J Arthroplasty* 2011; 26: 1432-7.
- Lee YS, Yoon TR. Error in acetabular socket alignment due to the thick anterior pelvic soft tissues. *J Arthroplasty* 2008; 23: 699-706.
- Jenny JY, Boeri C, Dosch JC, Uscatu M, Ciobanu E. Navigated non-image-based positioning of the acetabulum during total hip replacement. *Int Orthop* 2009; 33: 83-7.
- Sendtner E, Schuster T, Worner M, Kalteis T, Grifka J, Renkawitz T. Accuracy of acetabular cup placement in computer-assisted, minimally-invasive THR in a lateral decubitus position. *Int Orthop* 2011; 35: 809-15.
- Lin F, Lim D, Wixson RL, Milos S, Hendrix RW, Makhosous M. Limitations of image-less computer-assisted navigation for total hip arthroplasty. *J Arthroplasty* 2011; 26: 596-605.
- Kumar MA, Shetty MS, Kiran KG, Kini AR. Validation of navigation assisted cup placement in total hip arthroplasty. *Int Orthop* 2012; 36: 17-22.

ความแม่นยำของมุมเบ้าข้อสะโพกเทียมในการผ่าตัดโดยใช้คอมพิวเตอร์นำร่องในท่ากึ่งนอนตะแคง

ยิ่งยง สุขเสถียร, รัชวรรณ สุขเสถียร, ประเมษฐ์ ชัยวิรัตน์

ภูมิหลัง: ความแม่นยำของมุมเบ้าข้อสะโพกเทียมขึ้นอยู่กับข้อกำหนดตำแหน่งของกระดูกระหว่างผ่าตัด คณะผู้วิจัยได้คิดค้นการผ่าตัดข้อสะโพกเทียมโดยใช้คอมพิวเตอร์นำร่องในท่ากึ่งนอนตะแคงซึ่งรวมข้อดีของการกำหนดตำแหน่งกระดูกในท่านอนหงายและการทำ femoral stem ได้ง่ายในท่านอนตะแคง

วัตถุประสงค์: ศึกษาความแม่นยำของมุมเบ้าข้อสะโพกเทียมโดยการเปรียบเทียบผลของมุมระหว่างผ่าตัดโดยใช้คอมพิวเตอร์นำร่องและหลังผ่าตัด

วัสดุและวิธีการ: ผู้ป่วยทุกรายได้รับการผ่าตัดโดยใช้คอมพิวเตอร์นำร่อง Orthopilot THA plus 3.2 (cup only) ในท่ากึ่งนอนตะแคง หลังผ่าตัดทำ CT scan ทุกรายเพื่อวัดมุม abduction และ anteversion เปรียบเทียบกับผลของมุมระหว่างผ่าตัดโดยใช้ paired t-test และ a correlation test

ผลการศึกษา: มีผู้ป่วยทั้งหมด 65 ราย ค่ามาตรฐานมุม CT abduction เท่ากับ 41° ค่ามาตรฐานมุม navigated abduction เท่ากับ 39.8° ค่าความแตกต่างเฉลี่ย เท่ากับ 1.6° ค่ามาตรฐานมุม CT anteversion เท่ากับ 15° ค่ามาตรฐานมุม navigated anteversion เท่ากับ 12° ค่าความแตกต่างเฉลี่ยเท่ากับ 3.2°

สรุป: การผ่าตัดข้อสะโพกเทียมโดยใช้คอมพิวเตอร์นำร่องในท่ากึ่งนอนตะแคงให้ค่าความแม่นยำของเบ้าข้อสะโพกเทียมใกล้เคียงกับท่านอนหงายและนอนตะแคง แต่ทำ femoral stem ได้ง่ายกว่า
