

# Fetal Ductus Venosus Pulsatility Index and Diameter during 20-30 Weeks Gestation

Athita Chanthasenanont MD\*,  
Densak Pongrojapaw MD\*, Charintip Somprasit MD\*

\* Division of Maternal-Fetal-Medicine, Department of Obstetrics and Gynecology, Thammasat University, Pathumthani

**Objective:** To present normal range of the pulsatility index and the smallest diameter in the ductus venosus in normal fetuses throughout gestation.

**Material and Method:** This was a prospectively cross-sectional study. Three measurements were made for the ductus venosus diameter and the pulsatility index in each fetus during fetal quiescence. Statistical Package for the Social Sciences 14.0 software was used to create nomograms for the ductus venosus pulsatility index and diameter against gestational age. Four hundred and sixty normal fetuses aged seventeenth to thirty-seventh weeks were evaluated.

**Results:** The median diameter of the ductus venosus was linear across gestation.

**Conclusion:** The nomograms for the ductus venosus pulsatility index and diameter are presented. The size of the narrowest portion of the DV grows in a linear relationship through gestation.

**Keywords:** Diameter, Ductus venosus, Normal range, Pulsatility index

*J Med Assoc Thai* 2008; 91 (6): 794-8

**Full text. e-Journal:** <http://www.medassocthai.org/journal>

The ductus venosus (DV) is one of the three physiological shunts in the fetus. It is a small funnel shaped vessel found posterior to the fetal liver connecting the intra- abdominal umbilical vein (IAUV) and the inferior vena cava (IVC). It directs a large part of the well- oxygenated blood from the placenta to the foramen ovale to the left side of the heart. The DV has been extensively investigated in animal models<sup>(1-5)</sup>. Recently, due to improved color Doppler techniques, the venous vessels have been analyzed across gestation in the human fetus<sup>(1-15)</sup>. Normal and abnormal flow patterns of the DV are becoming standardized in the human fetus.

The DV regulates the amount of oxygenated blood directed toward the heart from the IAUV away from the liver. The DV appear at a right angle to the curve of the IAUV. The double-layer wall of the DV contains elastic, collagen and argyrophilic fibers<sup>(16)</sup>. The specific anatomical finding of the ductal isthmus

is an accumulation of smooth muscle cells in a local focus as an “intimal pillow” can protrude into the vascular lumen<sup>(16)</sup>. This region also contains vasa vasorum and nervi vasorum. This pillowed isthmus performs the role of the resistor to flow similar to the valve. The thickness of the DV is consistently greater near the inlet than near the outlet. It is significantly greater than the wall thickness of either the portal sinus of IAUV or left hepatic vein<sup>(16)</sup>.

The aim of the present study was to present a normal range for the DV smallest diameter in normal fetuses throughout gestation. The authors also presented the reference value of the DV pulsatility index (PI).

## Material and Method

This was a prospectively cross-sectional observation study. Ethical approval was obtained from the Ethic Committee of Faculty of Medicine, Thammasat University, Thailand. From July 10, 2006 to May 31, 2007, four hundred and sixty low risk pregnant women with gestational age of seventeenth to thirty-seventh weeks were recruited in the present study. All of these

Correspondence to: Chanthasenanont A, Division of Maternal-Fetal-Medicine, Department of Obstetrics and Gynecology, Thammasat University, Pathumthani 12120, Thailand. E-mail: [athitaka@gmail.com](mailto:athitaka@gmail.com)

women underwent trans-abdominal ultrasound examination at the Maternal-Fetal Medicine Unit, Thammasat University Hospital. Exclusion criteria was fetus had abnormal growth or anomaly on that scan.

Fetal ultrasound studies were performed on all fetuses with a coaxial pulsed Doppler color flow imaging system (Aloka ProSound SSD-  $\alpha 5sv$  Tokyo, Japan) employing 3.5-7.5 MHz transducer. Two-dimensional structural identification of the fetus was accomplished. Doppler interrogation included a free loop of the umbilical artery (UA) and umbilical vein (UV), middle cerebral artery (MCA), IAUV, ductus arteriosus (DA) and DV were undertaken.

The DV can be visualized in its full length in a mid- sagittal section of the fetal trunk. In an oblique transverse section through the upper abdomen, it can be found where color Doppler indicates high velocities compared to the IAUV. In Doppler velocimetry, the most consistent measurements could be obtained by placing the sample volume at the initial half portion of the length of the DV. The flow velocity waveform of the DV demonstrates a continuous forward flow throughout the cardiac cycle. The DV was identified by color aliasing of the vessel arising from the IAUV; the color scale then increased and the color gain reduced until the echogenic surfaces of the DV could be observed with near transparent color flow (Fig. 1). All ultrasound studies were performed by the first author. For reduced intra-observer variation, three measurements were made in each fetus during fetal quiescence. A nomogram was constructed from the results by using an average of

three measurements for each normal fetus. All normal fetuses included in the present study had normal anatomy and normal growth assessed by these scans. All normal fetuses also had normal Doppler flow of the UA, UV, MCA, IAUV and DA. Statistical Package for the Social Sciences 14.0 (SPSS) software was used to create nomograms for DV PI and diameter against gestation. By using mean  $\pm$  standard deviation; the 5<sup>th</sup> and 95<sup>th</sup> percentiles, linear regression and correlation analyses to present the normal range for the DV and PI during gestational age, p-value less than 0.05 was considered significant.

## Results

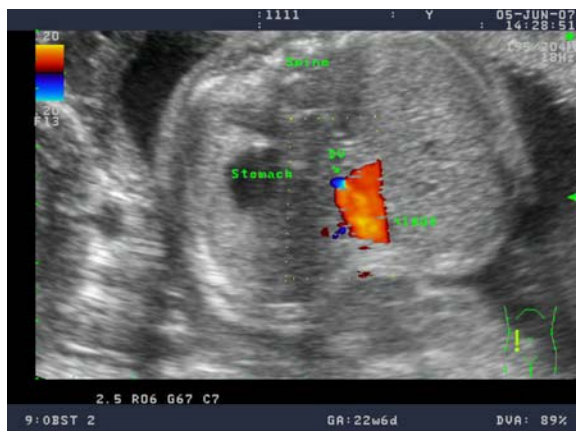There were 460 normal fetuses aged 17 to 37 weeks included in the present study. The authors used data from 407 cases (88.48%) of satisfactory measurements to create nomograms of DV PI and diameter. The satisfactory measurement was three measurements for each ductus venosus diameter or the pulsatility index in each fetus during fetal quiescence could be undertaken. The mean maternal age was 27 (range 16-40) years. The majority (89.4%) of these cases were 2<sup>nd</sup> trimester pregnancies (Table 1).

A nomogram was constructed from the results, using an average of three measurements from each fetus. The curve-fitted percentile charts of the DV PI and diameter were created (Fig. 2, 3). The DV PI decreased with advancing gestation ( $DV\ PI = 0.61 - (0.01 \times GA)$ ,  $r^2 = 0.02$  and  $p = 0.146$ ). The median diameter of the DV was linear across gestation ( $DV\ diameter = 0.23 + (0.05 \times GA)$ ,  $r^2 = 0.47$  and  $p < 0.001$ ).

## Discussion

Pulsatility of flow velocity waveforms in the DV are the consequence of changes in pressure difference between the venous system and the right atrium during the heart cycle. When the atrial contraction increases pressure, this is seen as a reversal in the otherwise forward flow pattern of the DV. When atrial pressure is higher during contraction the reversal pattern will be more exaggerated. The pulsatility index of the DV is normally below 1.0 during gestation between 2<sup>nd</sup> trimester and term. Pulsatility above 1.0 is an indicator of high central venous pressure and a harbinger of congestive heart failure and hydrops or of right ventricular obstructive lesions such as tricuspid valve atresia.

The authors have established the normal ranges for DV PI and diameter throughout gestation in the normal fetuses. All measurements were performed



DV, ductus venosus; IAUV, intra-abdominal umbilical vein

**Fig. 1** The ductus venosus was identified in transverse section through the upper abdomen

**Table 1.** Maternal demographics (407 cases)

Data	Number of cases	Mean $\pm$ SD	Percent
Age (years)		27.4 $\pm$ 4.9	
Gravida			
1	201		49.4
2	132		32.4
$\geq 3$	74		18.2
Parity			
0	262		64.4
1	112		27.5
$\geq 2$	33		8.1
Gestational age (weeks)		24.0 $\pm$ 3.4	
2 <sup>nd</sup> trimester	364		89.4
3 <sup>rd</sup> trimester	43		10.6

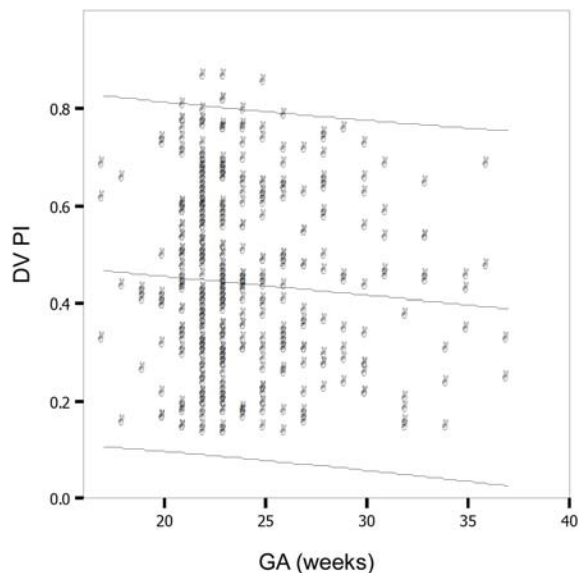
SD, standard deviation

**Table 2.** Mean and standard deviation of the ductus venosus pulsatility index and diameter during gestation

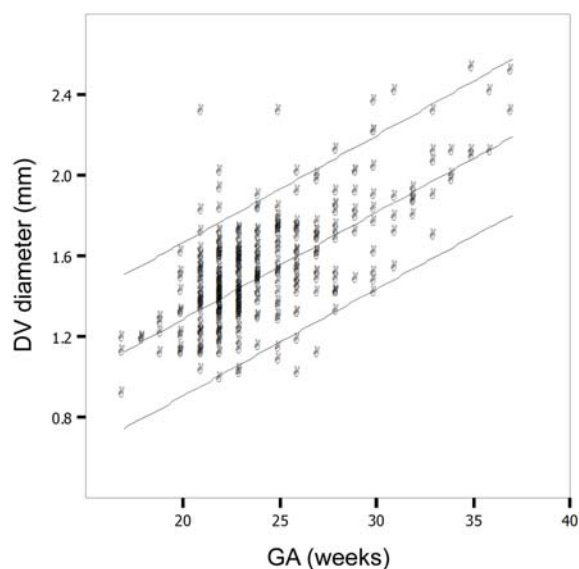
GA (weeks)	Number of cases	PI Mean $\pm$ SD	Diameter Mean $\pm$ SD (mm)
17	3	0.537 $\pm$ 0.190	1.063 $\pm$ 0.146
18	3	0.410 $\pm$ 0.251	1.177 $\pm$ 0.006
19	4	0.373 $\pm$ 0.754	1.201 $\pm$ 0.079
20	12	0.378 $\pm$ 0.198	1.303 $\pm$ 0.166
21	44	0.470 $\pm$ 0.180	1.370 $\pm$ 0.228
22	98	0.458 $\pm$ 0.180	1.405 $\pm$ 0.173
23	82	0.431 $\pm$ 0.185	1.437 $\pm$ 0.149
24	32	0.459 $\pm$ 0.180	1.522 $\pm$ 0.165
25	31	0.422 $\pm$ 0.197	1.575 $\pm$ 0.235
26	23	0.441 $\pm$ 0.182	1.540 $\pm$ 0.225
27	17	0.371 $\pm$ 0.166	1.617 $\pm$ 0.204
28	15	0.507 $\pm$ 0.183	1.633 $\pm$ 0.238
29	7	0.399 $\pm$ 0.175	1.809 $\pm$ 0.187
30	11	0.410 $\pm$ 0.192	1.836 $\pm$ 0.328
31	5	0.540 $\pm$ 0.095	1.858 $\pm$ 0.329
32	5	0.208 $\pm$ 0.094	1.862 $\pm$ 0.049
33	5	0.518 $\pm$ 0.080	2.006 $\pm$ 0.229
34	3	0.223 $\pm$ 0.080	2.017 $\pm$ 0.074
35	3	0.403 $\pm$ 0.057	2.233 $\pm$ 0.248
36	2	0.575 $\pm$ 0.148	2.250 $\pm$ 0.202
37	2	0.280 $\pm$ 0.057	2.400 $\pm$ 0.141

GA, gestational age; PI, pulsatility index; SD, standard deviation

by one examiner. The size of the narrowest portion of the DV is linear in growth throughout gestation as supports a previous study by Kiserud<sup>(9)</sup>. The authors' data shows the DV diameter does not exceed 2.5 mm



DV, ductus venosus; PI, pulsatility index; GA, gestational age

**Fig. 2** Individual values for the pulsatility index of the ductus venosus during gestation with mean, 5<sup>th</sup> and 95<sup>th</sup> percentiles from the regression analysis

DV, ductus venosus; GA, gestational age

**Fig. 3** Individual values for the diameter of the ductus venosus during gestation with mean, 5<sup>th</sup> and 95<sup>th</sup> percentiles from the regression analysis

(95<sup>th</sup> percentile) before 37 weeks of gestation. The DV PI varies widely within the normal range of less than 1.0 from 17 weeks to term, even in the same fetus, during the same study. The mean PI, however, does not correlate with gestation in a linear fashion significantly ( $p = 0.146$ ). This differs from numerous previous papers<sup>(3,4,10,12,13)</sup> that demonstrate the mean DV PI decreases with advancing gestational age. These normal values serve as the presented standard to investigate cardiovascular changes in pregnancies with fetuses at risk for hypoxia and acidemia because of anemia, congenital heart disease, congestive heart failure and intrauterine growth restriction.

## References

1. Kiserud T, Eik-Nes SH, Blaas HG, Hellevik LR. Ultrasonographic velocimetry of the fetal ductus venosus. *Lancet* 1991; 338: 1412-4.
2. Kiserud T, Eik-Nes SH, Blaas HG, Hellevik LR. Foramen ovale: an ultrasonographic study of its relation to the inferior vena cava, ductus venosus and hepatic veins. *Ultrasound Obstet Gynecol* 1992; 2: 389-96.
3. DeVore GR, Horenstein J. Ductus venosus index: a method for evaluating right ventricular preload in the second-trimester fetus. *Ultrasound Obstet Gynecol* 1993; 3: 338-42.
4. Hecher K, Campbell S, Snijders R, Nicolaides K. Reference ranges for fetal venous and atrioventricular blood flow parameters. *Ultrasound Obstet Gynecol* 1994; 4: 381-90.
5. Hecher K, Campbell S, Doyle P, Harrington K, Nicolaides K. Assessment of fetal compromise by Doppler ultrasound investigation of the fetal circulation. Arterial, intracardiac, and venous blood flow velocity studies. *Circulation* 1995; 91: 129-38.
6. Kiserud T. In a different vein: the ductus venosus could yield much valuable information. *Ultrasound Obstet Gynecol* 1997; 9: 369-72.
7. Bellotti M, Pennati G, Pardi G, Fumero R. Dilatation of the ductus venosus in human fetuses: ultrasonographic evidence and mathematical modeling. *Am J Physiol* 1998; 275: H1759-67.
8. Kiserud T. Hemodynamics of the ductus venosus. *Eur J Obstet Gynecol Reprod Biol* 1999; 84: 139-47.
9. Kiserud T, Rasmussen S, Skulstad S. Blood flow and the degree of shunting through the ductus venosus in the human fetus. *Am J Obstet Gynecol* 2000; 182: 147-53.
10. Bahlmann F, Wellek S, Reinhardt I, Merz E, Steiner E, Welter C. Reference values of ductus venosus flow velocities and calculated waveform indices. *Prenat Diagn* 2000; 20: 623-34.
11. Kiserud T. The ductus venosus. *Semin Perinatol* 2001; 25: 11-20.
12. Axt-Flidner R, Diler S, Georg T, Friedrich M, Diedrich K. Reference values of ductus venosus blood flow velocities and waveform indices from 10 to 20 weeks of gestation. *Arch Gynecol Obstet* 2004; 269: 199-204.
13. Axt-Flidner R, Wiegank U, Fetsch C, Friedrich M, Krapp M, Georg T, et al. Reference values of fetal ductus venosus, inferior vena cava and hepatic vein blood flow velocities and waveform indices during the second and third trimester of pregnancy. *Arch Gynecol Obstet* 2004; 270: 46-55.
14. Borrell A. The ductus venosus in early pregnancy and congenital anomalies. *Prenat Diagn* 2004; 24: 688-92.
15. Kiserud T. Physiology of the fetal circulation. *Semin Fetal Neonatal Med* 2005; 10: 493-503.
16. Ailamazyan EK, Kirillova OV, Polyanin AA, Kogan IY. Functional morphology of ductus venosus in human fetus. *Neuro Endocrinol Lett* 2003; 24: 28-32.

---

## ค่าปกติ ของ pulsatility index และ เส้นผ่านศูนย์กลางของหลอดเลือด ductus venosus ของทารกในครรภ์

อริตา จันทเสนานนท์, เด่นศักดิ์ พงศ์โรจน์เฒ่า, จรินทร์ทิพย์ สมประสิทธิ์

**วัตถุประสงค์:** เพื่อศึกษาค่าปกติของ pulsatility index และ เส้นผ่านศูนย์กลางของหลอดเลือด ductus venosus ของทารกในครรภ์ที่อายุครรภ์ต่าง ๆ

**วัสดุและวิธีการ:** ทำการวัด pulsatility index และ เส้นผ่านศูนย์กลางของหลอดเลือด ductus venosus ของทารกในครรภ์ที่ปกติโดยวัด 3 ครั้งในทารกแต่ละคนที่อายุครรภ์ 17 ถึง 37 สัปดาห์ จำนวน 460 คน แล้วนำค่าที่ได้มาคำนวณหาค่าปกติที่อายุครรภ์ต่าง ๆ โดยใช้ SPSS14.0

**ผลการศึกษา:** ค่าปกติของเส้นผ่านศูนย์กลางของหลอดเลือด ductus venosus ของทารกในครรภ์มีความสัมพันธ์เป็นเส้นตรงกับอายุครรภ์อย่างมีนัยสำคัญทางสถิติ

**สรุป:** เส้นผ่านศูนย์กลางของหลอดเลือด ductus venosus ของทารกในครรภ์มีความสัมพันธ์เชิงบวกกับอายุครรภ์

---