

Expression of E-Cadherin and Syndecan-1 in Axillary Lymph Node Metastases of Breast Cancer with and without Extracapsular Extension

Voranuch Thanakit MD*,
Preecha Ruangvejvorachai BSc*, Pichet Sampatanukul MD*

* Department of Pathology, Faculty of Medicine, Chulalongkorn University, Bangkok

Background: Extracapsular extension of axillary lymph node (ECE) has significantly increased the risk of locoregional and distant recurrence in breast cancer patients.

Objective: Identify markers with high biological aggressiveness since it may serve as a prognostic indicator or adjunct to standard treatment.

Material and Method: The authors immunostained 115 axillary lymph nodes of invasive ductal carcinoma with syndecan-1 and E-cadherin.

Results: The presented data shows a significantly higher number of positive lymph node (8.48 vs. 4.15; $p < 0.0001$) and larger primary tumor size (3.53 vs. 2.79; $p = 0.0029$) in ECE patients. Sixty-one cases had node positive and without evidence of ECE, 54 cases had ECE. Syndecan-1 was found to be of significantly high expression ($p = 0.001$). There was no significant difference in the expression of E-cadherin during progression into extracapsular area ($p = 0.12$).

Conclusion: E-cadherin displays high expression in nodal breast cancer metastases that may have re-expression and has coordinate function with syndecan-1 while invading to the surrounding fatty tissue. The protein is, therefore, likely to play a role in the invasiveness and aggressiveness.

Keywords: Breast cancer, E-cadherin, Syndecan-1, Extracapsular extension

J Med Assoc Thai 2008; 91 (7): 1087-92

Full text. e-Journal: <http://www.medassocthai.org/journal>

Invasiveness and metastasis is an important cause of morbidity and mortality in breast cancer patients. Assessment of the number of lymph nodes involved, tumor size, tumor grade, and hormone receptor status have been well-documented as risk factors of breast cancer metastasis for many years. So far, nodal status in a breast cancer patient is recognized as one of the most important prognostic factors⁽¹⁾.

There have been many studies on whether the presence of ECE influences the axillary recurrence. However, previous analyses found a lower survival rate was associated with ECE⁽²⁻⁴⁾. Moreover, a recent report found the presence of ECE was related to an increased risk of regional and distant recurrence and suggested

the benefit of additional treatment or adjuvant therapy as crucial to reduce the local relapse (breast or chest wall), regional relapse (axillary, supraclavicular or internal mammary) and distant recurrence in patients. The presence of ECE is more significant in predicting the prognosis than the pN category^(5,6). Thus, the importance of breast carcinoma with axillary metastases either with ECE or without ECE that demonstrates heterogeneity in clinical outcomes among women is interesting.

Until now, the molecular events that underlie the invasiveness and aggressiveness of the tumor cells with ECE are controversial. The mechanisms of metastases that breast cancer cells dissociate themselves from the primary site and move to metastatic sites as well as breaking through the capsule and invading to the surrounding soft tissue require various factors. The disturbance in epithelial cell adhesion is

Correspondence to: Thanakit V, Department of Pathology, Faculty of Medicine, Chulalongkorn University, Bangkok 10330, Thailand. Phone: 02-256-4235, E-mail: voranewt@yahoo.com

leading to the more invasiveness and progression. E-cadherin, a calcium-regulated cell surface glycoprotein, has an important role in cell-cell adhesion. It is a tumor suppressor gene and has a crucial anti-invasive role. Loss of E-cadherin causes dysfunction of the cell-cell junction and triggers cancer cells invasion and metastasis. To the authors' knowledge, there has been no published report on ECE patients with increased invasive capacity of breast cancer cells with E-cadherin.

A study on a subgroup of breast carcinoma characterized by molecular events may allow selective therapeutic target approaches such as c-erb-B2. However, the actual mechanisms between c-erb-B2 and the heparin-binding growth factor family are still unclear. These growth factors may require specific heparan sulfate proteoglycans (HSPGs) as coreceptor⁽⁷⁾. Syndecan-1 is a cell surface heparan sulphate proteoglycans and binding both extracellular matrix (ECM) components and basic fibroblast growth factor (bFGF) which participate in cell proliferation, cell migration and cell-matrix interactions⁽⁸⁾.

The purpose of the present study was to investigate any intrinsic factors that may play the role in extracapsular extension. Syndecan-1 and E-cadherin are investigated in axillary nodal metastases with and without ECE by means of immunohistochemistry. The authors further studied the importance of clinicopathological features by comparing the node-positive groups, with ECE and without ECE.

Material and Method

Tissue samples and clinical data

From 2003 to 2005, 115 patients with breast cancer underwent modified radical mastectomy with node positive at King Chulalongkorn Memorial Hospital. Histologic slides of breast tissues and axillary lymph nodes were retrieved for review by two pathologists from files of surgical pathology of the Department of Pathology, Faculty of Medicine, Chulalongkorn University. Positive axillary lymph nodes were separated into two groups. Of these, 61 patients had pathologically node-positive breast cancer without ECE and 54 patients had node positive with ECE. ECE was noted when the tumor cells extended beyond the nodal capsule to the extranodal adipose tissue. The total number of involved lymph nodes of both specimens was recorded. The largest node-positives from both groups of specimens were selected for immunohistochemistry study and the greatest dimension was recorded. All submitted nodes were evaluated in percentage of involved areas in lymph nodes as < 50% and > 50%.

Clinical pathologic features were obtained from submitted pathology requisition forms. The present study was approved by the Ethics Committee of the Faculty of Medicine, Chulalongkorn University. Immunohistochemical analysis

Immunohistochemical study was performed on two-micrometer-thick paraffin-embedded tissue sections of the axillary lymph node positive and ECE group using BENCHMARK LT immunostainer (Ventana Medical System). The slides were subsequently deparaffinized and antigen retrieval was performed on paraffin sections using EZ prep and CC1 mild. Primary antibodies included E-cadherin (Dako, clone NCH38, dilution 1:400) and Syndecan-1 (Dako, clone M115, dilution 1:500) incubated for 32 minutes, 37°C. The peroxidase reaction was developed using DAB chromogen provided in the kit (Ultraview™ Universal DAB Detection Kit).

E-cadherin stain was recorded as semiquantitative approach according to the modified histochemical score (H-score). The H-score was evaluation of both intensities of membranous staining and the percentage of stained cells. The intensity was recorded as score index including 0,1,2 and 3 corresponding to negative, weak, moderate and strong staining, respectively. The percentage of positive cells was estimated individually. The final score was 0-300 according to the intensity plus the percentage of positive cells. Final result was recorded as positive or negative. Reduced expression (negative, absent) when the H-score ≤ 100 ⁽⁹⁾.

Syndecan-1 stains were recorded as membranous, cytoplasmic, and/or both. Immunostain was considered positive when there were more than 10% of the tumor cells that were immunoreactive⁽¹⁰⁾. All cases were examined independently by two pathologists. Discrepancies between the observers were found in less than 10% of the examined slides, and consensus was reached on a subsequent review.

Statistical analysis

Continuous variables were compared using Student's two-tailed *t*-test when applicable. Chi-square test was used to analyze individual expression of Syndecan-1 and E-cadherin within the node positive and ECE groups. P-value of less than 0.05 was considered statistically significant.

Results

In the current study, 115 cases of invasive ductal carcinoma with axillary lymph node metastases were examined for clinicopathologic features and

immunohistochemical study. Of the invasive ductal carcinoma with node positive patients, 61 had node positive without evidence of extracapsular extension (without ECE), the other 54 cases had node positive with ECE (ECE group). The ECE patients had a mean age of 55.0 years (ranged 30-93 years). The mean age of the patients without ECE was 51.8 years (ranged 30-87 years). No significance of mean age of patients between the two groups was noted (p -value = 0.17). The means of the primary tumor size of invasive ductal carcinoma with ECE and without ECE were 3.53 and

2.79 cm. The primary tumor size of both groups was significantly different $p = 0.0029$ and larger in the ECE patients. Grading of the primary tumor of ECE and node-positive groups were Grade 1 = 0/54 cases; Grade 2 = 22/54 cases; Grade 3 = 32/54 cases; and, Grade 1 = 2/61 cases; Grade 2 = 28/61 cases; Grade 3 = 31/61 cases; $p = 0.47$ (Table 1). The mean total number of involved lymph nodes (8.48 nodes) in ECE patients was significantly higher than the group without ECE (4.15 nodes); $p \leq 0.0001$. No significant difference between the size of involved lymph node was noted, 0.4-3 cm for ECE and 0.4-2.4 cm for node-positive group ($p = 0.46$). Forty-nine cases of ECE (90.74%) and thirty-three cases of node-positive group (54.1%) had a significant area of tumor cells infiltration more than 50% of involved lymph node; $p \leq 0.001$ (Table 1).

Immunohistochemical study (Table 2) was performed in all 115 cases of invasive ductal carcinoma with node metastasis patients (54 with ECE and 61 without ECE groups). Of the largest selected involved lymph node cases, immunostains were done in both types of lymph nodes. Positive expression rate of Syndecan-1 in the ECE patients (Fig. 1) was significantly higher expression than that of the node-positive without ECE patients; $p = 0.001$. E-cadherin expression was high in both groups (Fig. 2). Such difference was not observed in both groups with E-cadherin immunostains ($p = 0.12$).

Discussion

Extracapsular extension (ECE) of invasive ductal carcinoma was a common finding on axillary lymph node with node-positive patients. The authors assessed the clinicopathologic features and immunohistochemistry status in different nodal status. Among 115 node-positive patients, the submitted cases had no difference in the size of involved lymph nodes, age, and grading of primary tumor. However, the finding was significantly elucidated in the ECE group which

Table 1. Summary of clinicopathological data of invasive ductal carcinoma with axillary lymph node metastasis with and without ECE

Clinicopathologic characteristics	ECE	Without ECE	p-value
Number of cases	54	61	
Age (years)			0.17*
Mean	55.0	51.8	
Range	30-93	30-87	
Primary tumor size (cm)			0.0029*
Mean	3.53	2.79	
Range	1-7	1-5.3	
Grade			0.47
1	0	2	
2	22	28	
3	32	31	
Total no. of involved LN			<0.0001*
Mean	8.48	4.15	
Range	1-38	1-17	
Size of involved LN (cm)			0.46*
Mean	1.16	1.24	
Range (cm)	0.4-3.0	0.4-2.4	
% of involved area in LN			<0.001
< 50%	5 (9.26%)	28 (45.9%)	
> 50%	49 (90.74%)	33 (54.1%)	

* = Unpaired t-test

Table 2. Immunohistochemistry expression of Syndecan-1 and E-cadherin in invasive ductal carcinoma with node-positive and ECE

Antibodies	E-cadherin			Syndecan-1		
	ECE	Without ECE	p-value	ECE	Without ECE	p-value
Status of lymph node						
Positive	51	51		40	26	
Negative	3	10		14	35	
Total	54	61	0.12	54	61	0.001

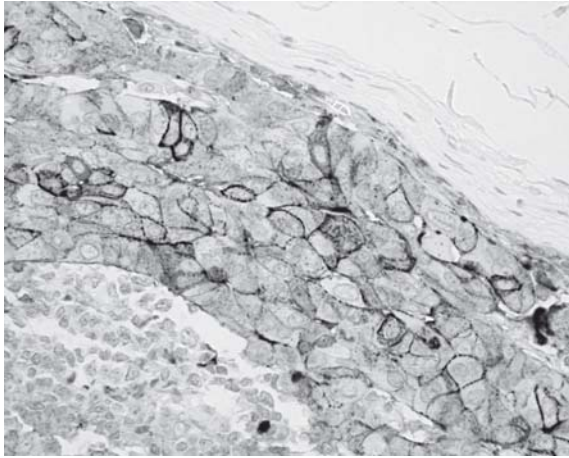


Fig. 1 The strong membranous and cytoplasmic staining of Syndecan-1 in axillary lymph node of invasive ductal carcinoma with extracapsular extension (ECE)

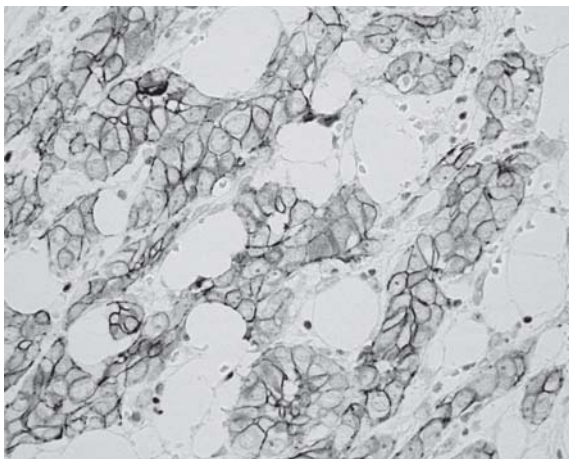


Fig. 2 High or strong E-cadherin expression in axillary lymph node with ECE

was associated with the larger primary tumor sizes, increased number of positive nodes, and more involved area within lymph nodes (> 50%). The authors' findings are consistent with those of prior studies that were directly related to increased total number of positive node⁽¹¹⁾. It displays significant correlation of ECE with their larger areas of involvement within affected lymph nodes that may be associated with the increased amount of breast cancer cells that invaded and deposited into the metastatic sites.

Syndecan-1 (CD138), a major syndecan in epithelial cells, is a member of four transmembrane heparan sulfate proteoglycans (HSPGs) implicated in

several signal transductions via the extracellular glycosaminoglycan chains that bind with growth factors, growth factor receptors, extracellular matrix proteins, cell-cell adhesion molecules, protease inhibitors, and degradative enzymes⁽⁸⁾. Syndecan-1 expression decreased in colorectal cancer in higher histological grade and more advanced clinical stage that is contradictory in breast and pancreatic cancer^(10,13). The biological function of syndecan-1 in human breast cancer has been extensively studied. They found over-expression of syndecan-1 in breast carcinoma cell lines and tumors⁽¹²⁾. However, no previous studies have focused on the protein expression in ECE and without ECE patients. In the present study, the authors found the level of syndecan-1 increased in ECE patients (40/54 cases). On the contrary, expression of syndecan-1 was found in 20 of 61 cases. In this series there was a significantly high expression of syndecan-1 in ECE patients ($p = 0.001$). Relatively few studies have investigated the expression of syndecan-1 in breast carcinoma. Barbaresch et al found high syndecan-1 expression in high histologic grades, large tumor size, high mitotic count, c-erbB-2 over-expression and ER and PgR negative status. High syndecan-1 expression is associated with aggressive phenotypes and labeled as marker of poor prognosis and had poor overall survival in breast cancer patients⁽¹⁰⁾. It is also consistent with the data since the presented ECE patients who had larger primary tumor size. This may support the idea that in an ECE patient, syndecan-1 expression is one of intrinsic factors involving extracapsular spread via biological interaction between cellular signaling and extracellular matrix or molecules. Thus, syndecan-1 over-expression may play an important role in the pathogenesis of the invasion. Axillary lymph nodes of ECE patients who had high syndecan-1 expression could be used to identify a group of patients with poor prognosis and aggressive type of breast cancer.

E-cadherin, a member of a large family of related proteins, is a transmembrane glycoprotein, which mediates calcium-dependent intercellular adhesion involving in epithelial cell-to-cell adhesion. Its impaired function may play a crucial role in invasiveness and more advanced tumor stages of lung cancer, prostate cancer, gastric cancer, colorectal cancer, and breast cancer⁽¹⁴⁾. The prognostic significance of E-cadherin expression in breast cancer has shown inconsistency. Many earlier reports found loss or reduced E-cadherin expression was associated with larger size, higher histologic grade, ER negative status. In addition, the loss of E-cadherin was also associated

with increased risk of development of distant metastasis, locoregional recurrence and poor prognosis⁽⁹⁾. On the contradictory, the present results have shown high expression of E-cadherin in ECE (51/54 cases) and without ECE group (51/61 cases). Some studies have demonstrated stronger E-cadherin expression at the metastatic sites and lymph nodes^(14,15). Previous reports also found a re-expression of E-cadherin in circulating tumor cells to survive and can deposit at metastatic site. Here, the authors have shown the similar higher expression of the E-cadherin protein in both groups of axillary node metastases. Therefore, it seems possible that E-cadherin and syndecan-1 had coordinating function and expression during tumor cells invasion. With regard to mammary epithelial cell lines, the experiment found that syndecan-1 expression was controlled by E-cadherin. This investigation showed a coordinate regulation of cell-cell and cell-matrix interaction in invasive tumor cell lines by sharing same transport mechanisms or syndecan-1 functions as helper-molecule for E-cadherin to restore the epithelial-like morphology in epithelial cells during tumor-cell invasion⁽¹⁶⁾. E-cadherin protein expression does not show any difference between the two groups, one with ECE and the other without ECE ($p = 0.12$). E-cadherin protein is, therefore, unlikely to play any major role regarding the invasiveness of axillary nodes but had re-expression and coordinate function with syndecan-1.

In conclusion, our present study has demonstrated a significantly higher expression of syndecan-1 in axillary lymph nodes with ECE of invasive ductal carcinoma patients, compared to the node-positive group without ECE. Syndecan-1 and E-cadherin has coordinated function while invading the surrounding fatty tissue at nodal metastatic sites. Over-expression of these proteins may contribute to the progression, invasiveness, and aggressiveness of breast cancer cells, and therefore deserve further studies.

Acknowledgement

This work was supported by Ratchadapiseksompotch Fund, Grant No. RA 21/49.

References

1. Harigopal M, Berger AJ, Camp RL, Rimm DL, Kluger HM. Automated quantitative analysis of E-cadherin expression in lymph node metastases is predictive of survival in invasive ductal breast cancer. *Clin Cancer Res* 2005; 11: 4083-9.
2. Leonard C, Corkill M, Tompkin J, Zhen B, Waitz D, Norton L, et al. Are axillary recurrence and overall survival affected by axillary extranodal tumor extension in breast cancer? Implications for radiation therapy. *J Clin Oncol* 1995; 13: 47-53.
3. Donegan WL, Stine SB, Samter TG Implications of extracapsular nodal metastases for treatment and prognosis of breast cancer. *Cancer* 1993; 72: 778-82.
4. Pierce LJ, Oberman HA, Strawderman MH, Lichter AS. Microscopic extracapsular extension in the axilla: is this an indication for axillary radiotherapy? *Int J Radiat Oncol Biol Phys* 1995; 33: 253-9.
5. Neri A, Marrelli D, Roviello F, De Stefano A, Guarnieri A, Pallucca E, et al. Prognostic value of extracapsular extension of axillary lymph node metastases in T1 to T3 breast cancer. *Ann Surg Oncol* 2005; 12: 246-53.
6. Evron E, Barzily L, Rakowsky E, Ben Baruch N, Sulkes J, Rizel S, et al. Postoperative loco-regional radiation therapy for breast cancer patients with four or more involved lymph nodes or extracapsular extension. *Isr Med Assoc J* 2005; 7: 439-42.
7. Iozzo RV. Heparan sulfate proteoglycans: intricate molecules with intriguing functions. *J Clin Invest* 2001; 108: 165-7.
8. Zimmermann P, David G. The syndecans, tuners of transmembrane signaling. *FASEB J* 1999; 13(Suppl): S91-100.
9. Rakha EA, Abd ER, Pinder SE, Lewis SA, Ellis IO. E-cadherin expression in invasive non-lobular carcinoma of the breast and its prognostic significance. *Histopathology* 2005; 46: 685-93.
10. Barbareschi M, Maisonneuve P, Aldovini D, Cangi MG, Pecciarini L, Angelo MF, et al. High syndecan-1 expression in breast carcinoma is related to an aggressive phenotype and to poorer prognosis. *Cancer* 2003; 98: 474-83.
11. Hetelekidis S, Schnitt SJ, Silver B, Manola J, Bornstein BA, Nixon AJ, et al. The significance of extracapsular extension of axillary lymph node metastases in early-stage breast cancer. *Int J Radiat Oncol Biol Phys* 2000; 46: 31-4.
12. Lundin M, Nordling S, Lundin J, Isola J, Wiksten JP, Haglund C. Epithelial syndecan-1 expression is associated with stage and grade in colorectal cancer. *Oncology* 2005; 68: 306-13.
13. Leivonen M, Lundin J, Nordling S, von Boguslawski K, Haglund C. Prognostic value of syndecan-1 expression in breast cancer. *Oncology* 2004; 67: 11-8.
14. Kowalski PJ, Rubin MA, Kleer CG. E-cadherin expression in primary carcinomas of the breast and its distant metastases. *Breast Cancer Res* 2003; 5:

- R217-R222.
15. Bukholm IK, Nesland JM, Borresen-Dale AL. Re-expression of E-cadherin, alpha-catenin and beta-catenin, but not of gamma-catenin, in metastatic tissue from breast cancer patients. *J Pathol* 2000; 190: 15-9.
 16. Leppa S, Vleminckx K, Van Roy F, Jalkanen M. Syndecan-1 expression in mammary epithelial tumor cells is E-cadherin-dependent. *J Cell Sci* 1996; 109(Pt 6): 1393-403.

การแสดงออกของ E-cadherin and Syndecan-1 ในต่อมน้ำเหลืองบริเวณรักแร้ของผู้ป่วยมะเร็งเต้านมที่มีการแพร่และไม่มีการแพร่กระจายออกนอกแคปซูล

วรณัฐ ธนากิจ, ปรีชา เรืองเวชวรชัย, พิเชฐ สัมปทานกุล

ผู้ป่วยมะเร็งเต้านมที่มีการแพร่กระจายของเซลล์มะเร็งเต้านมออกนอกแคปซูลพบมีนัยสำคัญของการเกิดซ้ำในตำแหน่ง locoregional และในตำแหน่งที่แพร่กระจายไกลออกไป รายงานนี้พบการแพร่กระจายออกนอกแคปซูลของเซลล์มะเร็งเต้านมมีความสัมพันธ์อย่างมีนัยสำคัญกับจำนวนที่เพิ่มขึ้นของต่อมน้ำเหลืองที่เกิดการแพร่กระจายของเซลล์มะเร็ง (8.48 กับ 4.15, $p < 0.001$) และมีขนาดของก้อนมะเร็งเต้านมที่ใหญ่กว่า (3.53 กับ 2.79, $p = .0029$) การตรวจหาตัวชี้วัดทางชีวภาพ ที่สัมพันธ์กับความรุนแรงของเซลล์มะเร็ง มีความสำคัญมาก เพราะอาจใช้เป็นตัวบ่งบอกการพยากรณ์โรค หรือ ใช้เป็นตัวเสริมร่วมกับวิธีการรักษาผู้ป่วยแบบเดิม คณะผู้นิพนธ์ศึกษาต่อมน้ำเหลืองที่มีการแพร่กระจายของผู้ป่วยมะเร็งเต้านมชนิด invasive ductal carcinoma จำนวน 115 ราย โดยย้อมด้วยอิมมูโนฮิสโตเคมีด้วย E-cadherin และ syndecan-1 ในจำนวนนี้ 61 ราย มีการแพร่กระจายไปสู่ต่อมน้ำเหลือง แต่ไม่มีการแพร่กระจายออกนอกแคปซูล และ 54 ราย พบแพร่กระจายออกนอกแคปซูล Syndecan-1 มีการแสดงออกในปริมาณที่สูงและมีนัยสำคัญ ในกลุ่มผู้ป่วยที่มีการแพร่กระจายออกนอกแคปซูล ($p = 0.001$) ซึ่งดูเหมือนว่ามีบทบาทที่สำคัญในการทำให้เกิดการลุกลาม และโรคมีความรุนแรง E-cadherin ไม่พบความแตกต่างของการแสดงออกอย่างมีนัยสำคัญ ($p = 0.12$) แต่อย่างไรก็ตาม E-cadherin มีค่าสูงในผู้ป่วยทั้ง 2 กลุ่ม การที่ E-cadherin มีค่าสูงในต่อมน้ำเหลืองอาจเกิดจาก E-cadherin กลับมามีค่าสูงใหม่ และยังทำงานร่วมกับ syndecan ในขณะที่มีการลุกลามออกสู่ไขมันรอบ ๆ