

# Supratentorial Lobar Anaplastic Ependymoma Resembling Cerebral Metastasis: a Case Report

Krishnapundha Bunyaratavej MD\*,  
Shanop Shuangshoti MD\*\*, Jantima Tanboon MD\*\*,  
Kraisri Chantra MD\*, Surachai Khaoroptham MD\*

\* Department of Surgery, Faculty of Medicine, Chulalongkorn University

\*\* Department of Pathology, Faculty of Medicine, Chulalongkorn University

---

*A 45-year-old man presented with progressive deterioration of vision. Visual acuity test revealed no light perception in both eyes. The fundoscopic examination demonstrated pale optic discs, consistent with secondary optic atrophy. Preoperative neuroimaging studies revealed a well-defined contrast-enhancing mass, 3 cm in diameter, at the left parietal region. Its radiologic appearances simulated those of cerebral metastases. A totally removed lesion was verified pathologically as an anaplastic clear cell ependymoma, which is rare in this location. A brief review of clinical features and neuroimaging of supratentorial lobar ependymoma is also included.*

**Keywords :** Lobar ependymoma, Supratentorium, Anaplastic, Clear cell ependymoma, Metastatic tumor

**J Med Assoc Thai 2004; 87(7): 829-33**

---

Ependymoma arising above the tentorium outside the ventricular surface is rare. It is less than 1% of all intracranial tumors and varies from 4.3 to 16.7% in ependymoma series<sup>(1-3)</sup>. Among the supratentorial ependymomas, 45-65% arise in the area remote from the ventricular wall<sup>(4-7)</sup>. Presumably these extraventricular ependymoma originate from fetal rests of ependymal cells<sup>(5,6,8)</sup>. Of interest, its malignancy increases with rising distance from the midline<sup>(6)</sup>. This is consistent with the reports of a high incidence of malignant ependymoma of the extraventricular location<sup>(2,6-8)</sup>. The author present herein a rare supratentorial lobar anaplastic ependymoma mimicking cerebral metastasis. The clinical features and neuroimaging are also reviewed.

## Case Report

A 45-year-old man presented with deterioration of visual acuity over the period of 4 months. Four months ago, he experienced transient "darkness" of his vision which lasted for a few minutes. Subsequently, he noticed a progressive

decline in his vision. Two weeks before admission, he could hardly perceive any light. He denied headache, motor weakness, and speech difficulties. The neurological examination revealed an alert and co-operative patient. Visual acuity test revealed no light perception in both eyes. Pupils were 3 mm in diameter and sluggishly reactive to light. The fundoscopic examination demonstrated pale optic discs, consistent with secondary optic atrophy. Computed tomography (CT) and magnetic resonance imaging (MRI) of the brain revealed a 3-cm in diameter isodensity mass at the left posterior parasagittal region, which enhanced brightly following contrast injection (Fig. 1 A & B and Fig. 2 A & B). There was massive perilesional edema of the white matter, causing 1.2 cm midline shift to the right at the level of the foramen of Monro (not shown). Chest roentgenography was normal. Ultrasonography of the abdomen failed to show an abnormality other than cholelithiasis. The pre-operative differential diagnosis included cerebral metastasis, glioblastoma, and meningioma. At craniotomy, a dark gray-pinkish moderately vascular tumor was found surfacing at the left posterior parasagittal region. The tumor did not involve the superior sagittal sinus. There was a plain

---

Correspondence to: Bunyaratavej K. Division of Neurosurgery, Department of Surgery, Faculty of Medicine, Chulalongkorn University, Bangkok 10330, Thailand.

between the tumor and adjacent brain parenchyma similar to that of a metastatic tumor. The lesion was removed completely. Microscopic examination (Fig. 3) revealed a well-defined neuroepithelial tumor with prominent clear cell component. Perivascular arrangement was seen throughout the lesion; many blood vessels possessed endothelial proliferation. There were also scattered foci of pseudopalisading necrosis. Mitotic figures were frequently seen, in active areas upto 10/14 high power fields. The majority of the tumor cells including perivascular processes were reactive for glial fibrillary acidic protein (GFAP). Synaptophysin was negative. Electron microscopic study (Fig. 4) demonstrated ependymal differentiation with cellular junctions and microvilli. The final diagnosis of anaplastic clear cell ependymoma was then rendered. Post-operative CT of the brain confirmed grossly total resection of the tumor. The patient received a complete course of 6000cGy whole brain radiation.

## Discussion

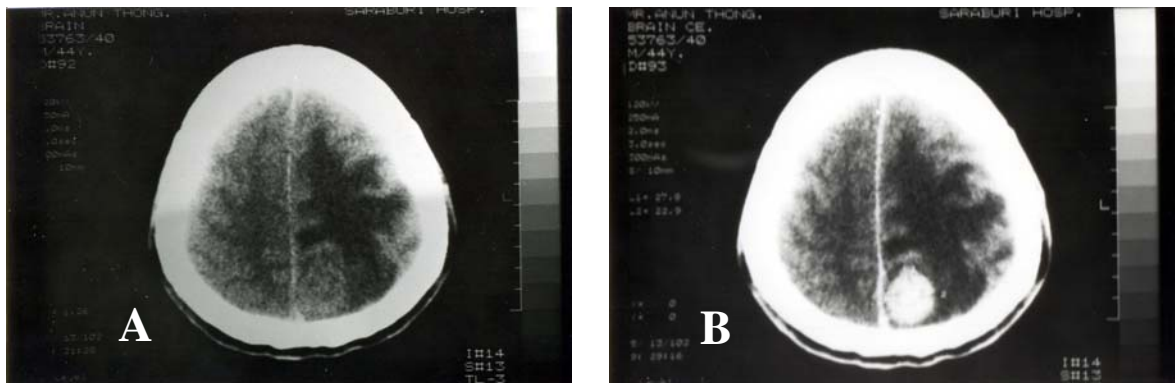
Supratentorial ependymomas are uncommon tumors of young subjects, with an average age of patients ranging from 17.1 to 34 years. To the best of our knowledge, only 19 patients over 45 years of age have been described<sup>(2-5,9,10)</sup>. From the clinical point of view, the present case has several features deserving mention. Firstly, despite the fact that the patient neither had known primary malignancy nor was it found during preoperative work up, the cerebral metastasis of unknown origin are common and this probability was, indeed, considered in the pre-operative imaging study. An ependymoma was entirely unexpected. Secondly, patients with cerebral hemispheric ependymoma typically manifest with headache, focal neurological deficits, and increased intracranial pressure; seizures are reported in one-third of the cases<sup>(1,7-9)</sup>. Interestingly, the presented patient did not complain of headache nor did he exhibit any other neurological deficits in spite of severe cerebral edema with midline shift. He presented with blindness as a result of long-standing increased intracranial pressure. The absence of other symptoms is presumably due to the slow progression of the tumor and adaptive capacity of the brain.

Most of the supratentorial ependymomas are well-circumscribed; cystic change with or without a mural nodule is characteristic<sup>(11,12)</sup>. On CT scan, the majority exhibits high attenuation prior to administration of contrast material with intense

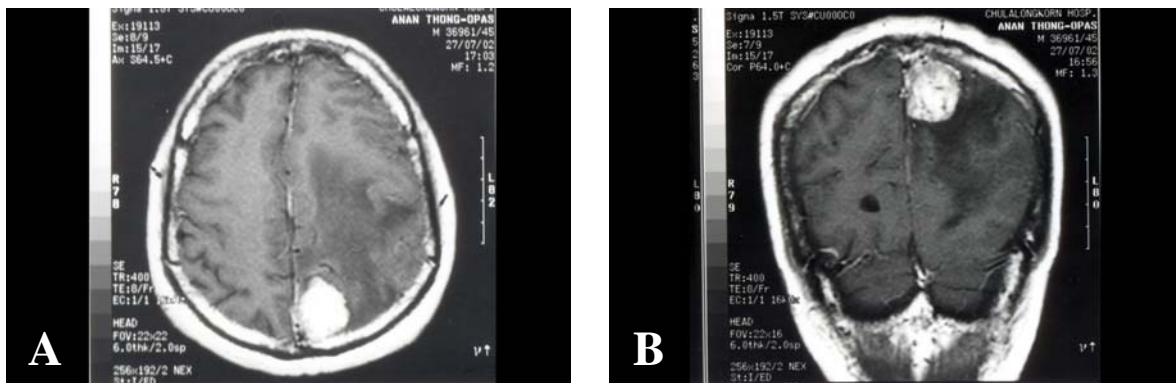
enhancement following contrast injection. Swartz *et al*<sup>(13)</sup> reported 84% of supratentorial ependymomas to demonstrate cystic component, a finding similar to others<sup>(14,15)</sup>. Centeno *et al* proposed that increased density of ependymoma on non-enhanced CT scan was due to the fine calcification<sup>(5)</sup>. Nevertheless, the CT scan of the presented patient demonstrated an isodense lesion prior to administration of contrast media with enhancing a solitary nodule following contrast injection. There was advanced cerebral edema, resembling that of a metastatic tumor or glioblastoma.

Pathologically, ependymomas have various histologic patterns. The clear cell variant, as in the current example, merits special attention because, on routine stain, this subtype of ependymoma is characterized by round tumor cells with perinuclear halo. These fried-egg-appearing cells distinctly mimic those of oligodendrogliomas and neurocytomas<sup>(12,16)</sup>. Unlike the infiltrative growth pattern of oligodendrogliomas, clear cell ependymomas are sharply-delineated lesions<sup>(12)</sup>. Like the presented case, the diffuse strong GFAP reactivity precludes the oligodendroglioma. The lack of neuronal markers such as synaptophysin excludes the neurocytoma which sometimes occur outside the ventricular system<sup>(17)</sup>. Electron microscopy plays an important role in the diagnosis of ependymoma, particularly when immunohistochemical study is inconclusive or when astrocytic tumors enter the differential diagnosis. As demonstrated in the presented case, microvilli and cellular junctions are the main ultrastructural features of ependymal neoplasms<sup>(12)</sup>. According to the recent World Health Organization guidelines<sup>(18)</sup>, the current clear cell ependymoma was considered anaplastic because of the presence of easily identified mitotic figures, endothelial proliferation, and foci of pseudopalisading necrosis.

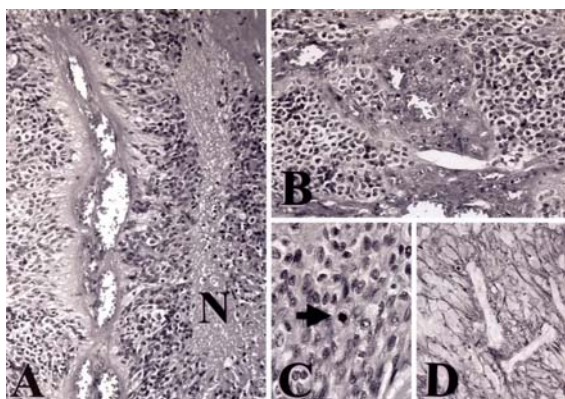
Supratentorial ependymomas are more feasible for total excision, as their common remote locations form important brain structures. The length of survival provided by complete resection, as opposed to partial, has been emphasized repeatedly. Indications for postoperative irradiation have been a subject of controversy. Recently however, it has been suggested that radiotherapy be given in cases of anaplastic ependymomas and in instances of benign or malignant tumors with partial resection<sup>(19,20)</sup>. Post-operative contrast-enhancing MRI study has also been recommended for a precise evaluation of the extent of surgery, and early second-look surgery



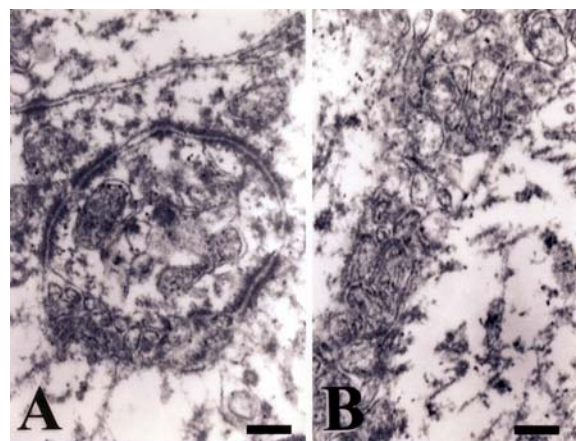
**Fig. 1A&B** Computed tomogram pre (A) and post (B) contrast revealed mass at parasagittal region of left parietal lobe with massive perileional edema



**Fig. 2A&B** Axial (A) and coronal (B) T<sub>1</sub>W MRI following gadolinium injection revealed lesion at parasagittal region of left parietal lobe



**Fig. 3** Histopathology of anaplastic clear cell ependymoma. Hematoxylin and eosin stain shows oligodendroglial-like tumor cells, with round nuclei and perinuclear halo (A). Note perivascular arrangement and a focus of pseudopalisading necrosis (N). Endothelial proliferation (B) and a mitotic figure (C) are demonstrated. Tumor cells express GFAP immunohistochemistry (D)



**Fig. 4** Ultrastructural features of anaplastic clear cell ependymoma. Ultrastructural study, using paraffin-embedded material, demonstrates cell junctions (A) and microvilli (B), features characteristic of ependymal differentiation (Bars = 200 nm)

can be proposed to achieve total excision in selected patients with an accessible residual tumor<sup>(19)</sup>. In case of recurrence, supratentorial ependymomas tend to recur in regions amenable to surgery, reoperation should, therefore, be considered first<sup>(19,20)</sup>. Prophylaxis craniospinal irradiation is no longer advocated unless cerebrospinal fluid seeding is evident<sup>(19)</sup>. The benefit of chemotherapy remains questionable.

### Acknowledgement

The authors wish to thank Professor Emeritus Doctor Samruay Shuangshoti for reviewing the manuscript.

### References

1. Barone BM, Elvidge AR. Ependymoma : A clinical survey. J Neurosurg 1970; 33: 428-37.
2. Mork SJ, Loken AC. Ependymoma: A follow up study of 101 cases. Cancer 1977; 40(2): 907-15.
3. Shuangshoti S Panyathanya R. Ependymomas: A study of 45 cases. Dis Nerv Syst 1973; 34(6): 307-14.
4. Armington WG, Osborn AG, Cubberley DA, Harnsberger HR. Supratentorial ependymoma: CT appearance. Radiology 1985; 157: 367-72.
5. Centeno RS Lee AA, Winter J, Barba D. Supratentorial ependymomas. Neuroimaging and clinicopathological correlation. J Neurosurg 1986; 64(2): 209-15.
6. Ernestus RI, Wilcke O, Schroder R. Supratentorial ependymoma in childhood: Clinicopathological findings and prognosis. Acta Neurochir (Wien) 1991; 111(3-4): 96-102.
7. Palma L, Celli P, Cantore G. Supratentorial ependymomas of the first two decades of life. Long-term follow-up of 20 cases (including two subependymomas). Neurosurgery 1993; 32(2): 169.
8. Dohrmann GJ: *Ependymomas*. 2nd ed. Neurosurgery, ed. Wilkins RH, Rengachary SS. Vol. I. 1996: McGraw-Hill.
9. Molina OM, Colina JL, Luzardo GD. Extraventricular cerebral anaplastic ependymoma. Surg Neurol 1999; 51(6): 630-5.
10. Kricheff II, Becker M, Schneck SA, Taveras J. Intracranial ependymomas: Factors influencing prognosis. J Neurosurg 1964; 21: 7-14.
11. Furie DM, Provenzale JM. Supratentorial ependymomas and subependymomas: CT and MRI appearance. J Comput Assist Tomogr 1995; 19: 518-26.
12. Min KW, Scheithauer BW. Clear cell ependymoma: A mimic of oligodendroglioma: clinicopathological and ultrastructural considerations. Am J Surg Pathol 1997; 21: 820-6.
13. Swartz JD, Zimmerman RA, Bilaniuk LT. Computed tomography of intracranial ependymomas. Radiology 1982; 143: 97-101.
14. Sauerbrei EE, Cooperberg PL. Cystic tumor of the fetal and neonatal cerebrum: Ultrasound and computed tomographic evaluation. Radiology 1983; 147: 689-92.
15. Naidich TP, Zimmerman RA. Primary brain tumor in children. Semin Roentgenol 1984; 19: 100-114.
16. Rosenblum MK. Ependymal tumors: A review of their diagnostic surgical pathology. Ped Neurosurg 1998; 28: 160-5.
17. Brat DJ Scheithauer BW, Eberhart CG, Burger PC. Extraventricular neurocytomas: Pathological features and clinical outcome. Am J Surg Pathol 2001; 25: 1252-60.
18. Kleihues P Caveness WK (ed): Pathology & Genetics of Tumours of the Nervous System, in World Health Organization Classification of Tumours, (IARC) International Agency for Research on Cancer, Editor. 2000, Press: Lyon.
19. Vinchon M, Soto-Ares G, Riffaud L, Ruchoux MM, Dhellemmes P. Supratentorial ependymoma in children. Ped Neurosurg 2001; 34(2): 77-87.
20. Palma L, Celli P, Mariottini A, Zalaffi A, Schettini G. The importance of surgery in supratentorial ependymomas. Long-term survival in a series of 23 cases. Child's Nerv Syst 2000; 16: 170-3.

---

*Anaplastic clear cell ependymoma* ของกลีบสมองเนื้อเทาโตเร็วเปลี่ยนแปลงมะเร็งกระจายมาที่  
สมอง: รายงานผู้ป่วย 1 ราย

กฤษณพันธ์ บุณยะรัตเวช, ชนพ ช่างโชติ, จันทิมา แทนบุญ, ไกรศรี จันทรา, สุรัชย์ เคารพธรรม

ผู้ป่วยอายุ 45 ปี มาพบแพทย์ด้วยสายตาดูลงจนมองไม่เห็นในเวลา 4 เดือน การตรวจจอประสาทตาพบข้อประสาทตาฝ่อทั้งสองข้างแบบเซคันดารี (Secondary optic atrophy) เอกซเรย์คอมพิวเตอร์ และ MRI ของสมองพบก้อนขนาด 3 ซม. ขอบเขตชัดเจนและ enhance เมื่อฉีดสีที่กลีบสมองพาราเอทอลด้านซ้ายเนื้องอกมีลักษณะคล้ายมะเร็งที่แพร่กระจายมายังสมอง ผู้ป่วยได้รับการผ่าตัด ผลตรวจทางพยาธิวิทยา เป็น *anaplastic clear cell ependymoma* ซึ่งพบได้น้อยมากในตำแหน่งดังกล่าว พร้อมกันนี้ได้นำเสนอลักษณะทางคลินิก และทางรังสีวิทยาของเนื้องอก *ependymoma* ของกลีบสมองใหญ่

---