

Positive Predictive Value of Breast Cancer in the Lesions Categorized as BI-RADS Category 5

Cholatip Wiratkapun MD*,
Panuwat Lertsithichai MD*, MSc**, Bussanee Wibulpholprasert MD*

* Department of Radiology, Faculty of Medicine, Ramathibodi Hospital, Mahidol University

** Department of Surgery, Faculty of Medicine, Ramathibodi Hospital, Mahidol University

Objective: To determine positive predictive value (PPV) of the breast imaging reporting and data systems (BI-RADS) category 5 mammogram and ultrasound (US) in the diagnosis of breast cancer in the study center and correlation between clinical, mammographic and US findings, and breast cancer.

Material and Method: Four hundred and ninety seven patients with BI-RADS category 5 who underwent mammograms and US at the Breast diagnostic center, Ramathibodi Hospital from January, 1, 2002 to December, 31, 2004 were enrolled into the present study. Selected clinical information, mammographic and US findings, and histopathological diagnosis were retrospectively reviewed.

Results: Breast cancer was found in 467 of 497 patients, giving a PPV of 94%. Invasive ductal carcinoma was the most common malignancy (89.5%). Fibrocystic change was the most common benign pathology found in the remaining patients. Discrete mass was the most frequently encountered lesion detected on mammography and US, followed by mass containing calcifications. Patients with advanced age, having a clinically palpable breast mass, with mammographic and US evidence of mass containing calcifications showed significant statistical association with breast cancer.

Conclusion: PPV of BI-RADS category 5 lesions in the present study was comparable to other published studies. Although the probability of malignancy was very high, a small number of patients had benign pathologies. Preoperative histopathologic diagnosis is necessary before definitive treatment.

Keywords: Breast cancer, BI-RADS category 5

J Med Assoc Thai 2006; 89 (8): 1253-9

Full text. e-Journal: <http://www.medassocthai.org/journal>

In 1992, the American College of Radiology (ACR) developed the breast imaging reporting and data system (BI-RADS) to standardize mammographic interpretation. The fourth edition of BI-RADS was introduced in 2003 and proposed a BI-RADS system for the Ultrasound (US)⁽¹⁾. Details of the BI-RADS for mammography and US are as follows; Category 0: Incomplete assessment, additional imaging evaluation and/or prior mammograms for comparison are needed, Category 1: Negative, annual screening mammogram is recommended, Category 2: Benign finding(s), annual screening mammogram is recommended, Category 3:

Probable benign finding, initial short-interval follow-up is suggested, Category 4: Suspicious abnormality, biopsy should be considered, Category 5: Highly suggestive of malignancy, appropriate action should be taken, and Category 6: Known biopsy-proven malignancy, appropriate action should be taken⁽¹⁾. BI-RADS was created to format mammographic and US interpretation among radiologists, to standardize assessment of the findings, to communicate to the referring physicians and to recommend appropriate care according to imaging findings⁽¹⁻⁸⁾. Moreover, it has been shown to improve the positive predictive value of breast biopsy⁽⁸⁾.

Breast lesions categorized as BI-RADS category 5 should have a very high likelihood of malignancy, i.e., at least a 95% chance of being malignant⁽¹⁾. In the period before percutaneous breast biopsy became

Correspondence to : Wiratkapun C, Department of Radiology, Faculty of Medicine, Ramathibodi Hospital, Rama VI Rd, Rajthawee, Bangkok 10400, Thailand. Phone: 0-2201-1260, Fax: 0-2201-1297, E-mail: cholattipp@hotmail.com

widely used, lesions assigned to BI-RADS category 5 could be surgically treated as malignant lesions⁽¹⁾.

The purposes of the present study were to determine Positive Predictive Value (PPV) of mammograms and US categorized as BI-RADS category 5 in the diagnosis of breast cancer in the present center, and to determine correlation between clinical, mammographic and US findings, and breast cancer.

Material and Method

From January 1, 2002 to December 31, 2004, 42,025 women who underwent screening and diagnostic mammogram at the Breast Diagnostic Center, Faculty of Medicine, Ramathibodi Hospital were studied. Five hundred and seventeen cases were categorized as BI-RADS category 5 (1.2%). Patients who had no histopathological records at Ramathibodi Hospital were excluded from the present study. Four hundred and ninety seven patients were enrolled into the present study. Selected clinical, mammographic, US findings and histopathological diagnosis were retrospectively reviewed. The size of a breast lesion was defined as the largest dimension determined by either mammography or US. Type of malignancy was based on highest histopathological grading of specimens obtained either by percutaneous biopsy or opened surgical biopsy.

During this period, mammography was performed using two mammography machines (Lorads M-IV; Danbury, CT, USA and Senographe DMR; GE, Milwaukee, WI, USA). Almost all patients underwent US (HDI 5000; Philips ultrasound, Bothell, WA, USA) after mammography, except for those cases with almost entirely fatty breasts. Thirteen radiologists, including three radiologists specializing in breast imaging, interpreted the mammograms and sonograms. Final assessment was based on the BI-RADS classification. BI-RADS category 5 was reserved for findings that are strongly associated with breast cancer, for example in mammograms, a spiculated, irregular high-density mass, a segmental or linear arrangement of fine linear calcifications or an irregular spiculated mass with associated pleomorphic calcifications⁽¹⁾. For US, mass with spiculated margin, irregular shape, and non-parallel orientation are highly predictive of malignancy⁽³⁾.

In the authors' practice, the most worrisome BI-RADS category either from mammography or sonography was selected as the final outcome. For example, linear branching calcification seen on the mammogram was categorized as BI-RADS mammogram category 5, but if these were not visible on US, the lesion will be

BI-RADS US category 1. The final assessment in this case will be BI-RADS category 5, based on mammography, which is more worrisome.

Statistical analysis

Continuous variables were summarized as mean (standard deviation) or median (range) as appropriate. Categorical variables were summarized as counts and percentages. Associations between histologic findings of malignancy and patient or radiographic characteristics were determined using logistic regression analysis. These associations were reported as odds ratios and 95% Confidence Intervals (95%CI). Statistical significance was defined as a p-value of 0.05 or less. All statistical analyses were performed using Stata v. 7 (Stata Corp, College Drive, Texas, USA).

Results

The mean age of the patients was 53 years (standard deviation, 12 years), ranging from 23 to 91 years. Twenty patients (4%) had a personal history of breast cancer. Palpable masses were noted in 432 patients (87%). The most frequent mammographic finding was discrete breast masses, which was found in 241 patients (49%), followed by breast masses containing calcifications in 195 patients (39%). US was able to detect a higher frequency of breast masses both palpable and nonpalpable, which were found in 350 patients (70%). The size of each mass ranged from 0.5 to 12 cm with a median of 2.5 cm. Details of mammographic and US features of BI-RADS category 5 lesions for these patients are displayed in Table 1. Note that in five patients (1%), findings judged to be BI-RADS category 5 were based solely on the US because they were invisible on mammograms due to dense breasts. All five were malignancies. Mean age of patients in this group was 40 years. US detected lesions in this group were masses with the median size of 1.9 cm, ranged 0.6-3.3 cm. Almost all of them were palpable by physical examination, except for the 0.6-cm lesion which was nonpalpable. US was unable to identify lesions that were initially detected by mammography as being BI-RADS category 5 in eight patients (1.6%). Five malignancies were found upon subsequent biopsies. All of them presented as calcifications.

Of the 497 patients in the present study, 467 patients were found to have breast cancer, giving a positive predictive value of 94%. Fig. 1A and B shows typical mammographic and US features of BI-RADS category 5 lesion. Invasive ductal carcinoma was the most frequent breast malignancy, found in 418 patients

Table 1. Mammographic and sonographic findings of lesions categorized in BI-RADS category 5 (n = 497)

Finding	Number of patients (%)
Mammographic findings	
Mass	241 (48.5)
Mass containing calcifications	195 (39.2)
Calcifications	30 (6.0)
Architectural distortion	11 (2.2)
Asymmetric breast density	8 (1.6)
Trabecular thickening	7 (1.4)
Negative mammography	5 (1.0)
Sonographic findings	
Mass	350 (70.4)
Mass containing calcifications	128 (25.8)
Architectural distortion	4 (0.8)
Complex mass	3 (0.6)
Edema	3 (0.6)
Calcifications	1 (0.2)
Negative US	8 (1.6)

(89.5%). Details of types of malignancies are displayed in Table 2. Benign pathology was reported in 30 patients (6%). The most common benign pathology was fibrocystic change, followed by fibroadenomas. Table 3 shows details of benign pathologic results.

Table 2. Type of malignancies

Type	Number of patients (%)
Invasive ductal carcinoma	418 (89.5)
Ductal carcinoma in situ	20 (4.3)
Invasive lobular carcinoma	8 (1.7)
Mucinous carcinoma	6 (1.3)
Medullary carcinoma	5 (1.1)
Breast lymphoma	4 (0.9)
Papillary carcinoma	3 (0.6)
Breast sarcoma	2 (0.4)
Mixed invasive ductal and lobular carcinoma	1 (0.2)
Total	467 (100)

Mammograms and US of 30 benign pathology were retrospectively reviewed by the principle investigator. There were 10 cases that should be classified as BI-RADS category 4 instead of category 5. Two cases of mammographic finding were of microcalcifications that turned out to be fibrocystic change. The remaining 8 cases were masses seen either on mammogram, US or both modalities. Their pathologies included benign phyllodes tumor (2 cases), fibrocystic change (2 cases), papilloma (2 cases), fibrosis (1 case) and atypical ductal

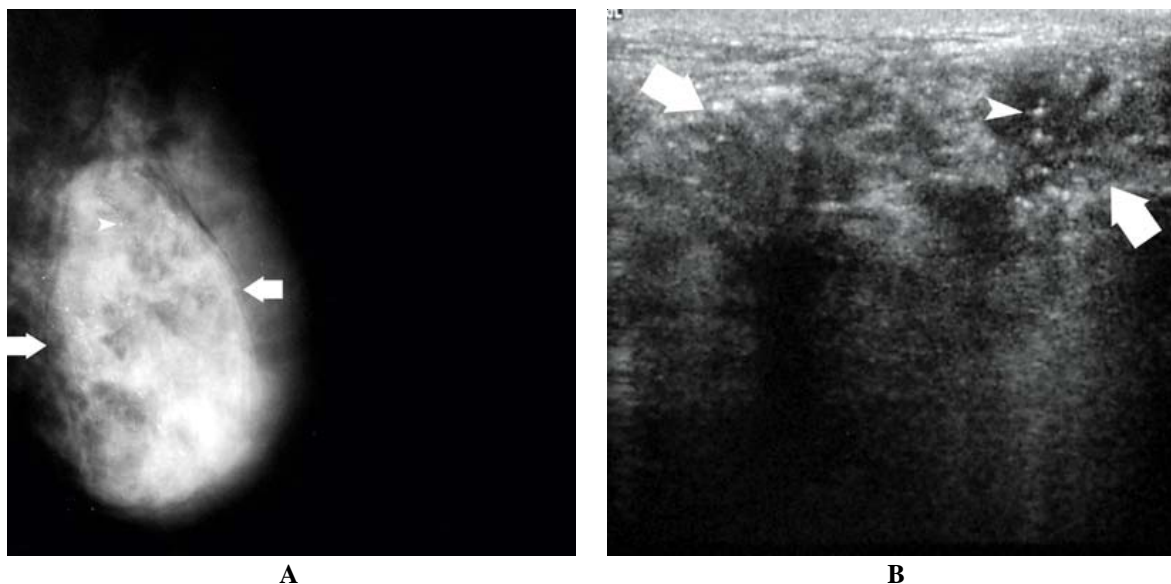


Fig. 1 A 34-year-old female had a palpable mass in the left breast. Mammogram (Fig. 1A) demonstrates a mass with partially ill-defined border (arrows). Example of pleomorphic and linear branching calcifications within this mass is shown by an arrowhead. This mass appears on US (Fig. 1B) as an irregular solid mass with indistinct border (arrows). Note calcifications within the mass (arrowhead). Pathology is invasive ductal carcinoma

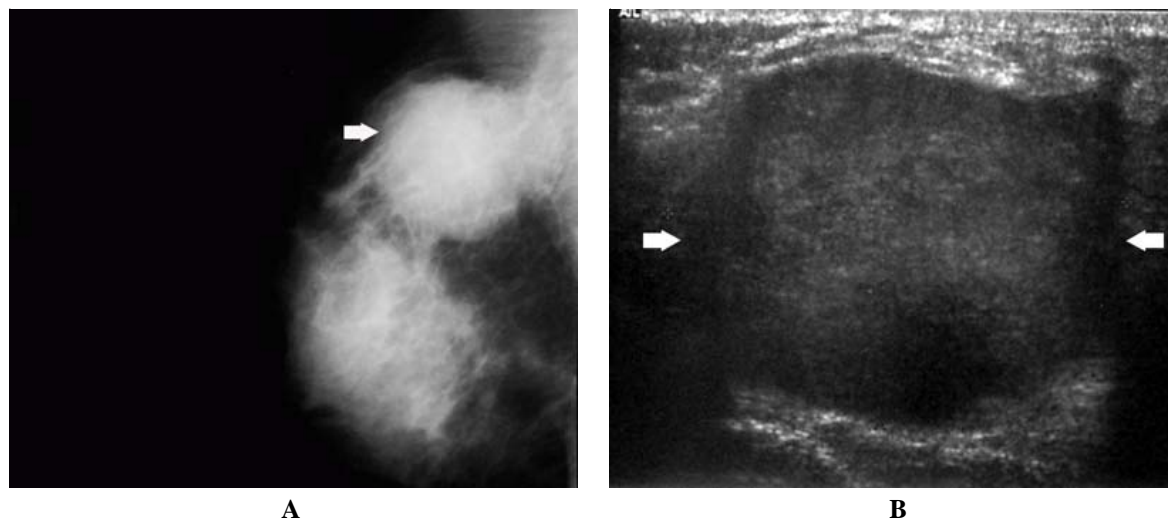


Fig. 2 A 40-year-old female developed a palpable mass in the right breast. Mammogram (Fig. 2A) demonstrates a mass with partially ill-defined border, which is shown by US (Fig. 2B) as an inhomogeneous solid mass. Pathology is benign phyllodes tumor

hyperplasia (1 case). The example of false positive case is shown in Fig. 2A and B.

The inappropriate assignment of BI-RADS classification was affected by the experience of radio-

logists. Among 10 false positive cases, 4 cases were interpreted by the less experienced radiologist who had 2-years less experience than other radiologists.

Increasing age, clinical finding of a palpable breast mass, mammographic finding of mass containing calcifications, and, particularly, sonographic finding of mass containing calcifications were significantly associated with breast cancer on univariable logistic regression (Table 4).

Discussion

Mammographic lesions categorized as BI-RADS category 5 include a spiculated, irregular high-density mass, a segmental or linear arrangement of fine linear calcifications or an irregular spiculated mass with associated pleomorphic calcifications⁽¹⁾.

US is an accepted adjunctive diagnostic tool for characterization of palpable or nonpalpable abnormalities of the breast, as well as a tool for further evaluation of clinical and mammographic findings⁽⁹⁾. US is particularly useful in cases of dense breasts where

Table 3. Benign or high-risk pathology found in lesions categorized as BI-RADS category 5

Pathology	Number of patients (%)
Fibrocystic change	8 (26.7)
Fibroadenoma/giant fibroadenoma	5 (16.7)
Sclerosing adenosis/adenosis	3 (10)
Benign phyllodes tumor	3 (10)
Papilloma	3 (10)
Fibrosis	3 (10)
Abscess/mastitis	2 (6.7)
Atypical ductal hyperplasia	2 (6.7)
Granuloma	1 (3.3)
Total	30 (100)

Table 4. Association between findings and breast cancer using univariable logistic regression (n = 497)

Findings	Odds Ratio	95%CI
Age	1.05 per year increase	1.01 to 1.09
Palpable breast mass	2.75	1.16 to 6.49
Mammographic evidence of mass containing calcifications	3.54	1.25 to 10.04
Sonographic evidence of mass containing calcifications	9.91	3.41 to 28.78

the fibroglandular tissue can obscure the lesion. The present study confirmed the role of US in dense breasts that the malignant lesions were invisible on the mammogram.

In the present study, breast mass was the most frequently detected BI-RADS category 5 lesions seen on both mammography and US, followed by a mass containing calcifications. These findings correlated with the most common malignancy found in the present series. This was the invasive ductal carcinoma (IDC). The most common mammographic sign of an IDC is a mass⁽¹⁰⁾. Typical IDC mass appears as having irregular shape, ill-defined or spiculated margins, and high radiographic density on mammography. In about 40% of cases, the mass is associated with malignant calcifications⁽¹⁰⁾. Malignant sonographic features include a solid mass with spiculation or thick hyperechoic halo or a solid mass with angular margins with or without acoustic shadowing⁽¹¹⁾. The type of common BI-RADS category 5 lesions in the published literature depends on the prevalence of the type of malignancies found in each study. In the series of Orel et al, mass is the most common mammographic lesion corresponding to the histopathology of IDC⁽²⁾. The mammographic hallmark of ductal carcinoma in situ (DCIS) is the presence of calcifications. In 70-80% of lesions, calcifications are the only finding⁽¹²⁾. Calcifications were the most frequently encountered lesions reported by Tan et al and DCIS was the most common malignancy found in their study⁽⁵⁾.

Among the 30 patients who had purely calcifications evident on mammography, subsequent US detected correlated calcifications in only one patient. Mammographic evidence of mass containing calcifications was found in 195 patients, but only 128 were subsequently detected by US. US has lower sensitivity for detecting calcifications compared to mammography. It is only 80% as sensitive as mammography for detection of calcifications within malignant nodules. Thus, US may fail to show some calcifications that are mammographically visible⁽¹¹⁾. However, US has a greater ability than mammography to differentiate solid mass from normal breast tissue⁽¹³⁾. While mammography is far better for detecting DCIS that is more likely to appear as microcalcifications, US is more sensitive for detecting early invasive cancer that is likely to be a mass⁽⁹⁾. The presented data supported this assertion. In the present series, US could detect 70% of pathologic masses whereas mammography was able to find such correlated masses in only 49% of cases.

Note that five patients in the present series had negative mammographic findings due to dense breasts, and the diagnosis of BI-RADS category 5 was based on US alone. All of them were masses. On the other hand, 8 patients had mammographic BI-RADS category 5 despite no detectable lesions on US. All of them were calcifications. These results emphasize the value of using both mammography and US to evaluate breast lesions in order to increase the sensitivity for detecting breast cancer. The value of US is greatest for women with dense breasts such as Asian women^(5,9).

PPV of the BI-RADS category 5 criteria in diagnosing breast cancer in the present study was 94% (467 of 497 patients). This PPV is compatible with the PPV advocated by the ACR, which proposed a PPV of at least 95%, and that of other published studies^(1,2,4,15,16). PPV for mammographic BI-RADS category 5 in published studies ranged from 80-97%^(2,4,15,16). In the study done by Tan et al, using both mammography and US, a PPV of 84% was reported. The PPV of the present study and others indicated that radiologists are able to accurately predict the presence of breast cancer in a highly suspicious lesion⁽⁴⁾.

Although BI-RADS category 5 lesions have a high probability of being cancerous, pre-operative histologic diagnosis particularly by percutaneous core needle biopsy should be performed before definitive surgery⁽¹⁾. The present study found that 30 patients (6%) presented with lesions initially categorized as BI-RADS category 5 but benign pathologies were later found on subsequent biopsy. Fibrocystic change was the most common benign pathology encountered in the present series, followed by fibroadenoma. Similar findings are also reported in the literature^(4,5). However, in the present study, the result from retrospective review mammograms and US found that some cases were more appropriate to be categorized in BI-RADS 4. Experience of radiologists had an influence on the accuracy of BI-RADS categorization.

In the present study, patients with mammographic and/or sonographic lesions, categorized as BI-RADS category 5 who were older, presented with a palpable breast mass, with mammographic and/or sonographic evidence of mass containing calcifications showed significant statistical association with breast cancer.

The incidence of breast cancer increases with advancing age. A palpable mass is the most common physical sign of breast cancer⁽¹⁰⁾. The likely pathology of a palpable breast mass depends on the age of the patient. In women younger than 30 years, fibroadenoma

is the most common pathology. In women older than 50 years, the pathology of a palpable breast mass is more likely to be breast cancer⁽¹⁰⁾.

Invasive breast cancers are commonly associated with microcalcifications⁽¹⁰⁾. Lesions appearing as masses containing calcifications on US had the highest probability of being breast cancers in the present study. As stated earlier, US has lower sensitivity than mammography in detecting calcifications. But if pleomorphic calcifications can be demonstrated within the mass, malignancy should be suspected. Visualization of calcifications on US depends on the echogenicity and heterogeneity of the background tissue where the calcification is located. Benign calcifications that occur as a result of fibrocystic change or benign proliferative disorders tend to be surrounded by hyperechoic tissues, and are often sonographically invisible^(11,14). US is able to demonstrate a higher percentage of malignant than benign calcifications. This finding is explained by the fact that malignant calcifications are often surrounded by hypoechoic tumor matrix which generates counter echo and are thus easily seen during US examination^(11,12).

A major limitation of the present study was possibly the high interrater variability in image interpretation among radiologists, which was influenced by experience.

Conclusion

The present study suggested that breast lesions that were categorized as BI-RADS category 5 had a high probability of being malignant (94%). BI-RADS category 5 lesions in patients with advanced age, with clinically palpable breast mass, with mammographic, and particularly, with sonographic evidence of mass containing calcifications had significant statistical association with breast cancer. However, a small number of patients with BI-RADS category 5 lesions had benign pathologies on subsequent biopsies. These findings suggest that preoperative histopathologic diagnosis, either by percutaneous core needle biopsy or opened surgical biopsy, is still necessary to preclude overtreatment.

References

1. American College of Radiology. ACR BI-RADS-Mammography. In: ACR Breast imaging reporting and data system atlas. 4th ed. Reston, VA: American College of Radiology; 2003.
2. Orel SG, Kay N, Reynolds C, Sullivan DC. BI-RADS categorization as a predictor of malignancy. *Radiology* 1999; 211: 845-50.
3. Hong AS, Rosen EL, Soo MS, Baker JA. BI-RADS for sonography: positive and negative predictive values of sonographic features. *AJR Am J Roentgenol* 2005; 184: 1260-5.
4. Lacquement MA, Mitchell D, Hollingsworth AB. Positive predictive value of the breast imaging reporting and data system. *J Am Coll Surg* 1999; 189: 34-40.
5. Tan YY, Wee SB, Tan MP, Chong BK. Positive predictive value of BI-RADS categorization in an Asian population. *Asian J Surg* 2004; 27: 186-91.
6. Geller BM, Barlow WE, Ballard-Barbash R, Ernster VL, Yankaskas BC, Sickles EA, et al. Use of the American College of Radiology BI-RADS to report on the mammographic evaluation of women with signs and symptoms of breast disease. *Radiology* 2002; 222: 536-42.
7. Lehman C, Holt S, Peacock S, White E, Urban N. Use of the American College of Radiology BI-RADS guidelines by community radiologists: concordance of assessments and recommendations assigned to screening mammograms. *AJR Am J Roentgenol* 2002; 179: 15-20.
8. Berg WA, Campassi C, Langenberg P, Sexton MJ. Breast Imaging Reporting and Data System: inter- and intraobserver variability in feature analysis and final assessment. *AJR Am J Roentgenol* 2000; 174: 1769-77.
9. Feig SA. Current status of screening US. In: Feig SA, editor. *Categorical course in diagnostic radiology: breast imaging*. Oak Brook, IL: Radiological Society of North America; 2005: 143-54.
10. Fu KL, Fu YS, Bassett LW, Cardall SY, Lopez JK. Invasive malignancies. In: Bassett LW, Jackson VP, Fu KL, Fu YS, editors. *Diagnosis of diseases of the breast*. 2nd ed. Philadelphia, PA: Elsevier; 2005: 483-517.
11. Stavros AT. Ultrasound of solid breast nodules: distinguishing benign from malignant. In: Stavros AT, editor. *Breast ultrasound*. Philadelphia, PA: Lippincott Williams & Wilkins; 2004: 445-527.
12. Stavros AT. Malignant solid breast nodules: specific types. In: Stavros AT, editor. *Breast ultrasound*. Philadelphia, PA: Lippincott Williams & Wilkins; 2004: 597-688.
13. Stavros AT. Introduction to breast ultrasound. In: Stavros AT, editor. *Breast ultrasound*. Philadelphia, PA: Lippincott Williams & Wilkins; 2004: 1-15.
14. Stavros AT, Rapp CL, Kaske TI, Parker SH. Hard and soft sonographic findings of malignancy.

- In: Feig SA, editor. Categorical course in diagnostic radiology: breast imaging. Oak Brook, IL: Radiological Society of North America; 2005: 125-42.
15. Hirunpat S, Tanomkiat W, Khojarern R, Arpakul N. Accuracy of the mammographic report category according to BIRADS. J Med Assoc Thai 2005; 88: 62-5.
16. Liberman L, Abramson AF, Squires FB, Glassman JR, Morris EA, Dershaw DD. The breast imaging reporting and data system: positive predictive value of mammographic features and final assessment categories. AJR Am J Roentgenol 1998; 171: 35-40.

มะเร็งเต้านมที่พบในรอยโรคที่จัดอยู่ใน BI-RADS category 5

ชลทิพย์ วิรัตน์พันธ์, ภาณุวัฒน์ เลิศสิทธิชัย, บุษณี วิบุลผลประเสริฐ

วัตถุประสงค์: เพื่อศึกษา Positive predictive value (PPV) ในรอยโรคที่ได้รับการวินิจฉัยด้วยแมมโมแกรมและอัลตราซาวด์ว่าเข้าได้กับ Breast Imaging Reporting And Data Systems (BI-RADS) category 5 และศึกษาความสัมพันธ์ระหว่างอาการทางคลินิก, ลักษณะทางแมมโมแกรม และอัลตราซาวด์กับมะเร็งเต้านม

วัสดุและวิธีการ: รวบรวมข้อมูลจากเวชระเบียน เปรียบเทียบผลการตรวจแมมโมแกรม, อัลตราซาวด์ และผลพยาธิวิทยาของผู้ป่วยที่จัดอยู่ใน BI-RADS category 5 ตั้งแต่ 1 มกราคม พ.ศ. 2545 - 31 ธันวาคม พ.ศ. 2547 จำนวน 497 ราย

ผลการศึกษา: พบมะเร็งเต้านม 467 ราย จากผู้ป่วย 497 ราย คิดเป็น PPV 94% มะเร็งเต้านมชนิด Invasive ductal carcinoma เป็นชนิดที่พบได้บ่อยที่สุด (89.5%) Fibrocystic change พบมากที่สุดในกลุ่มที่ไม่ใช่มะเร็งเต้านม รอยโรคชนิดที่เป็นก้อน (mass) เป็นลักษณะทางแมมโมแกรมและอัลตราซาวด์ที่พบได้บ่อยที่สุด ผู้ป่วยอายุมาก คลำก้อนได้ พบก้อนมีหินปูนจากแมมโมแกรมและอัลตราซาวด์ มีความเกี่ยวข้องกับมะเร็งเต้านมอย่างมีนัยสำคัญทางสถิติ

สรุป: การศึกษานี้พบว่า PPV ของ BI-RADS category 5 ใกล้เคียงกับการศึกษาอื่น ๆ ที่ผ่านมา ถึงแม้ผู้ป่วยที่จัดอยู่ใน category 5 มีโอกาสเป็นมะเร็งเต้านมสูง แต่การตรวจขึ้นเนื้อก่อนวางแผนการรักษายังมีความสำคัญมาก
